

The AF-FICIENT magnetic resonance imaging and endoscopy safety substudy: A visually guided radiofrequency balloon ablation catheter for pulmonary vein isolation



Matthew Daly, MBChB,* Michael Hurrell, MBChB,[†] Iain Melton, MBChB,* Gary Lim, MBChB,[‡] Audrius Aidietis, MD, PhD,[§] Gediminas Rackauskas, MD, PhD,[§] Amin Al-Ahmad, MD, FHRS,^{||} Ian Crozier, MD, FHRS*

From the *Department of Cardiology, Christchurch Hospital, Christchurch, New Zealand, [†]Department of Radiology, Christchurch Hospital, Christchurch, New Zealand, [‡]Department of Gastroenterology, Christchurch Hospital, Christchurch, New Zealand, [§]Centre for Cardiology and Angiology, Vilnius University, Vilnius, Lithuania, and ^{||}Texas Cardiac Arrhythmia Institute at St. David's Medical Centre, Austin, Texas.

BACKGROUND Early experience with a novel multielectrode saline-irrigated radiofrequency balloon (RFB) catheter with an integrated camera system found that it was safe and effective in performing single-shot pulmonary vein isolation (PVI) for atrial fibrillation.

OBJECTIVE The purpose of this study was to further assess potential treatment risks by looking for subclinical events.

METHODS The study was performed at 2 sites. Patients underwent PVI by RFB. A control group underwent conventional point-by-point radiofrequency ablation. Stroke scale questionnaire and brain magnetic resonance imaging (MRI) were performed before and after the ablation procedure, and esophageal endoscopy was performed after the procedure in RFB patients only.

RESULTS We enrolled 27 patients in the RFB group and 15 patients in the control group. The RFB and control groups were well matched [predominantly male: 62% vs 53%; CHA₂DS₂-VASc score: 1.9 ± 1.3 vs 1.5 ± 1.6; mean age 60 years in both groups]. All patients

underwent successful ablation and completed study assessments. Clinically silent, new MRI diffusion weighted imaging cerebral lesions were observed in 8 patients (30%) in the RFB group and 1 patient (7%) in the control group, and 11 susceptibility weighted imaging lesions in the RFB group and 1 in the control group. Endoscopy showed a minor thermal injury in 1 patient in the RFB group.

CONCLUSION An increased rate of clinically silent cerebral events was seen in the RFB group. A low rate of esophageal thermal injury was observed.

KEYWORDS Atrial fibrillation; Catheter ablation; Esophageal thermal lesions; Pulmonary vein isolation; Radiofrequency balloon; Silent cerebral events

(Heart Rhythm 0² 2022;3:15–22) © 2021 Heart Rhythm Society. Published by Elsevier Inc. This is an open access article under the CC BY-NC-ND license (<http://creativecommons.org/licenses/by-nc-nd/4.0/>).

Introduction

The clinical outcomes of the first 100 patients who underwent radiofrequency ablation (RFA) for atrial fibrillation using a novel, visually guided radiofrequency balloon (RFB) catheter were recently reported.¹ In a first-in-human multicenter clinical trial of first-time ablation for paroxysmal atrial fibrillation, we studied the performance, safety, and efficacy of pulmonary vein isolation (PVI) using this novel RFB cath-

eter.¹ We reported that 372 of 381 veins were acutely isolated, with median procedural time of 85 minutes and 84% freedom from atrial fibrillation at 12 months without device-related major complications.

Catheter ablation is the standard of care for patients with paroxysmal atrial fibrillation refractory to medical therapy.² However, conventional point-by-point RFA has limitations. The RFB catheter was designed to address many of these limitations, including long procedural times, low acute procedural efficacy, and frequent recurrence of atrial fibrillation.

Conventional RFA is associated with significant complications. Periprocedural stroke and esophageal injury are of particular concern and have the potential to cause major procedure-related morbidity and mortality.² Although the initial cohort of RFB patients was free from major

Clinical Trial Registrations: ACTRN12615001340527 and ACTRN12619000509167 (<https://www.anzctr.org.au>; Australian New Zealand Clinical Trials Registry). **Address reprint requests and correspondence:** Dr Ian Crozier, Department of Cardiology, Christchurch Hospital, 2 Riccarton Avenue, PO Bag 4710, Christchurch 8140, New Zealand. E-mail address: Ian.Crozier@cdhb.health.nz.

KEY FINDINGS

- The incidence of silent cerebral events as detected by brain magnetic resonance imaging (MRI) was 30%, higher than in a comparator group undergoing conventional ablation but comparable to initial reports of other multielectrode ablation systems.
- The silent cerebral event rate differed between the 2 study sites (8/20 and 0/7). This may have been due to the timing of heparin administration, procedural duration, or different sensitivity of the MRI scans.
- The incidence of asymptomatic esophageal lesions by upper gastrointestinal endoscopy was 3.7%, lower than previously observed with conventional radiofrequency ablation.

complications, in the current study we sought to address in greater detail the potential risks of the RFB catheter. As stroke and clinically manifest esophageal injury are infrequent complications (incidence <2% and 0.02%–0.11%, respectively),² we performed brain magnetic resonance imaging (MRI) and esophageal endoscopy after the ablation procedure to assess for subclinical injury.

Methods

Study design

AF-FICIENT-1 (A First In Human Radiofrequency [RF] Balloon Catheter Ablation to Isolate Pulmonary Veins in the Treatment of Patients with Paroxysmal Atrial Fibrillation; ACTRN12615001340527) was a first-in-human, prospective, multicenter, single-arm, clinical study of the RFB ablation catheter (Boston Scientific Inc., Marlborough, MA) for the treatment of symptomatic paroxysmal atrial fibrillation. The study enrolled 100 patients. The safety study was performed in another 27 patients who were enrolled in New Zealand and Lithuania. In addition, we subsequently performed a control study (ACTRN12619000509167) in which RFA was performed in a conventional point-by-point fashion in 15 patients in New Zealand. The clinical data were collected and recorded in an electronic database and monitored at regular intervals.

Patient enrollment criteria

The entry criteria were the same as for AF-FICIENT-1. Patients were adults undergoing a first-ever ablation procedure for symptomatic paroxysmal atrial fibrillation. Specific contraindication for the substudy was ineligibility for brain MRI or esophageal endoscopy.

RFB description

The RFB ablation system consists of a bidirectional, steerable, multielectrode, irrigated, luminal RFB catheter, which is an over-the-wire catheter introduced into the heart using a 13.5F deflectable sheath (Luminize catheter and steerable

sheath; Boston Scientific Inc.). The catheter interfaces with an ablation console, which is designed to deliver simultaneous multipolar radiofrequency energy. The RFB catheter incorporates the following features (Figure 1A): (1) a conformable 28-mm-diameter balloon that is inflated with saline; (2) a series of 18 ablation electrodes (6 forward-facing, 12 equatorial) on the surface of the balloon; (3) irrigation holes within each electrode that provide for saline-based cooling of the electrodes; (4) 12 sensing mini-electrodes; and (5) a series of 4 solid-state cameras inside the balloon that faced outward to provide a composite video image of the balloon inner surface showing the 18 ablation electrodes and any tissue in contact with the transparent conformable balloon membrane (Figure 1B). The console's user interface is used to visualize tissue contact, select the ablation pathway, display real-time impedance for each electrode, and control the irrigation pump. The generator provides independently titratable radiofrequency bipolar energy (6–10 W) to any of the selected adjacent electrodes during ablative treatment.

RFB study procedural workflow

Patients received either warfarin or non-warfarin oral anticoagulation for a minimum of 1 month before the procedure. The anticoagulation therapy was continued uninterrupted in 24 patients and withheld for 1–3 days preprocedure in 3 patients. Patients were screened for left atrial appendage thrombus using either cardiac computerized tomography or transesophageal echocardiography at the preprocedural assessment. The ablation procedures were performed with patients under conscious sedation. No esophageal temperature monitoring was used. The procedure was performed with femoral venous access, a decapolar catheter placed in the coronary sinus, and a single transseptal puncture. Unfractionated heparin was administered before transseptal puncture in Lithuania and after transseptal puncture in New Zealand as per local practice. Activated clotting time (ACT) was maintained at >300 seconds. The standard transseptal sheath was exchanged over a guidewire to place the custom 13.3F deflectable sheath. After thorough aspiration to evacuate any trapped air bubbles, the RFB catheter was advanced through the sheath into the left atrium. RFB catheter preparation included a dedicated flush and sonication of the balloon to remove any trapped air bubbles before the catheter was inserted into the sheath.

Using the guidewire (0.032 or 0.035 inch) as an anchor within each target pulmonary vein, the RFB catheter was positioned sequentially at each vein ostium. Under visual guidance from the internal cameras, the balloon was manipulated to maximize electrode–tissue contact, and a customized path of electrodes was selected for ablation. Bipolar radiofrequency energy was delivered between selected electrodes for up to 60 seconds. Pulmonary vein electrograms and electrode impedance were continuously monitored throughout each radiofrequency application to assess electrical isolation as determined by the operator using local

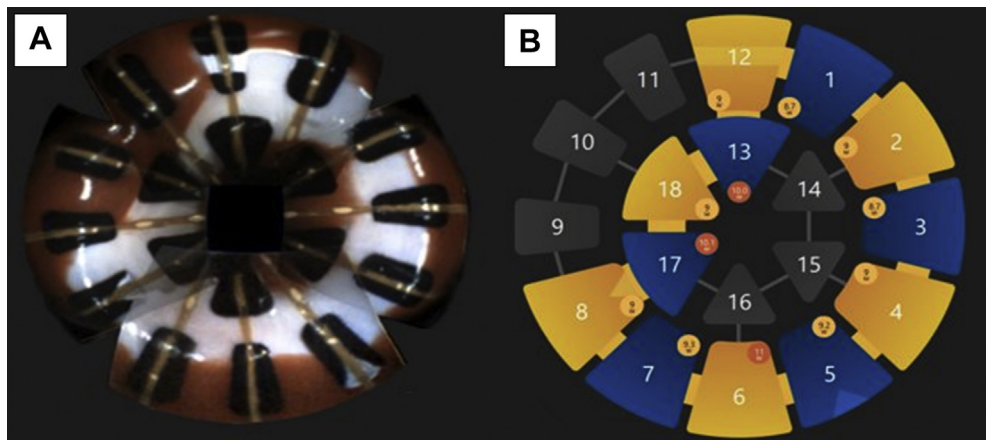


Figure 1 Pulmonary vein (PV) isolation with the radiofrequency balloon (RFB) catheter. Balloon position within the PV (A) and strategy used to achieve PV isolation (B). Here the RFB catheter was askew to the center of the PV, so 9 equatorial and 3 forward-facing electrodes were selected.

criteria. If circumferential contact and electrical isolation were not achieved with the initial balloon position, the RFB catheter was repositioned and additional applications were administered. If required, patients received either electrical or chemical cardioversion to achieve sinus rhythm. After electrical isolation, pulmonary vein entrance block was reconfirmed, vascular sheaths were removed, and hemostasis was achieved. Patients were followed for 12 months postprocedure.

Control study procedural workflow

The same workflow was used except that after transseptal puncture, a single commercially available irrigated-tip radiofrequency CARTO navigation, contact force, and ablation catheter (Biosense Webster, Diamond Bar, CA) was used for point-by-point PVI. A maximum power of 35 W was used. All studies were performed with patients on uninterrupted oral anticoagulation.

The following additional procedures were performed.

Brain MRI: A baseline scan was obtained before the procedure and then repeated within 72 hours after the ablation procedure. MRI was performed using Magnetom 1.5-T scanners (Siemens, Erlangen, Germany) with an Aera 16-channel head coil in Christchurch, and using an earlier model Avanto with 8-channel head coil in Lithuania. The Christchurch protocol comprised unenhanced sagittal T1 with 5 mm; transverse RESOLVE b1000 diffusion weighted imaging (DWI) in both 4-mm and 5-mm slice thicknesses with derived apparent diffusion coefficient (ADC) images; transverse T2 5 mm; transverse susceptibility weighted imaging (SWI) 2 mm; and transverse T2-FLAIR 5 mm. The Lithuania protocol comprised unenhanced sagittal T1 1 mm; transverse b1000 DWI 5-mm slice thicknesses with derived ADC images; transverse T2 5 mm; and transverse T2-FLAIR 5 mm.

Based on previous work by Deneke et al,³ lesions were classified as a silent cerebral event (SCEs) if a hyperintense lesion was seen on DWI with a corresponding hypointense lesion on ADC without FLAIR hyperintensity, and as silent cerebral lesion (SCL) if similar DWI/ADC changes were

observed but with corresponding T2-hyperintensity on T2-FLAIR images.

All MRIs were blindly read by a panel of 3 radiologists and the consensus reported, although the panel of radiologists was different for the Lithuania scans. In patients with SCE or SCL abnormalities, follow-up MRI was performed at 1–3 months.

SWI abnormalities were only recorded for the Christchurch cohort, and new postprocedure SWI hypointensities were reported by consensus.

National Institutes of Health Stroke Scale (NIHSS) Assessment: Assessment was performed before the ablation procedure and again during the 1-month follow-up. If no abnormality was detected, the score was 0; if any abnormality was detected, the score was 1.

Esophageal Endoscopy: This procedure was performed within 72 hours after the ablation in the substudy only, that is, only in patients who underwent treatment with the RFB catheter. Any potential thermal esophageal lesion was recorded.

The study was conducted in accordance with the Declaration of Helsinki and was approved by the ethics committees and local regulatory agencies at both sites. Informed consent was obtained from all subjects before enrollment.

The trial's sponsor, Boston Scientific, was involved in trial design and protocols but not data collection or analysis. The authors had full access to, and take responsibility for, the integrity of the data, and have read and agree with the manuscript as written.

The study was not powered for any secondary endpoint, so descriptive statistics were used to characterize these outcomes. Continuous variables are given as mean \pm SD or median (range) as appropriate, and categorical variables are given as number (percentage).

Results

In the RFB group, 27 patients were enrolled (20 New Zealand, 7 Lithuania). In the control group, 15 patients were enrolled (all in New Zealand). All patients completed the

Table 1 Patient characteristics

Characteristic	Study group	Control group
No.	27	15
Age [mean ± SD (range)] (y)	60 ± 8 (40–74)	60 ± 7 (48–72)
Male/female (%)	62/38	53/47
Modified EHRA classification (%)		
1: None	0	0
2a: Mild (normal daily activity not affected)	22	0
2b: Moderate (normal daily activity not affected)	67	87
3: Severe (normal daily activity affected)	11	13
Medical history (%)		
Paroxysmal/persistent AF	100/0	100/0
Hypertension	56	33
Diabetes	11	20
Dyslipidemia	65	33
Permanent pacemaker	0	0
Coronary artery disease	22	7
Chronic pulmonary disease	4	0
Stroke or transient ischemic attack	7	13
CHA ₂ DS ₂ -VASc score [mean ± SD (median)]	1.9 ± 1.3 (2)	1.5 ± 1.6 (1)
Left ventricular ejection fraction [mean ± SD (n)] (%)	59 ± 7.1 (27)	63 ± 4.0*
Left atrial dimension [mean ± SD (n)] (mm)	42 ± 5.9 (27)	41 ± 6.2*
Medication (%)		
Oral anticoagulant	100	100
Class I or III antiarrhythmic medication	96	80

AF = atrial fibrillation; EHRA = European Heart Rhythm Association.
*N = 14 (control arm).

ablation procedure and substudy tests except for 1 preprocedural stroke scale assessment.

Patient characteristics

Baseline clinical characteristics of the patients are given in [Table 1](#). All patients had previously been treated with a class I or III antiarrhythmic medication and had been taking an oral anticoagulant.

The characteristics of the control cohort of 15 patients were similar to those of the RFB group. The majority of the cohort (80%) had previously been treated with a class I

or III antiarrhythmic medication, and all had been taking an oral anticoagulant.

Procedural performance parameters

In the RFB cohort, total procedural time was 108.8 ± 31.6 minutes, total balloon time for the RFB catheter was 57.9 ± 25.3 minutes, and fluoroscopy time was 17.9 ± 10.3 minutes ([Table 2](#)). A mean of 8.7 ± 3.1 applications was delivered per patient, each lasting no more than 60 seconds, with RF power of 8–10 W. The procedure was performed without oral anticoagulation interruption in 24 patients. ACT while

Table 2 Procedural characteristics

Procedural parameter	Study group	Site 1	Site 2	Control group
No.	27	20	7	15
No. of catheters opened	32	24	8	17
No. of catheters opened and used	29	22	7	15
ACT >350 s	92.6% (25/27)	90% (18/20)	100% (7/7)	
Total heparinized saline infused (mL)	1059.0 ± 385.2	1144.4 ± 405.4	814.9 ± 168.9	625 ± 282
Fluoroscopy time (min)	17.9 ± 10.3	19.8 ± 10.5	12.6 ± 8.3	14 ± 19
Procedural duration (min)	108.8 ± 31.6	118.3 ± 30.2	81.7 ± 17.2	112 ± 29
Balloon/catheter time (min)	57.9 ± 25.3	65.3 ± 25.2	36.9 ± 7.4	91 ± 62
Total no. of pulmonary veins ablated	3.8 ± 0.5	3.7 ± 0.6	4	4
Total no. of ablations	8.7 ± 3.1	9.2 ± 3.4	7.4 ± 1.5	34 ± 10

ACT = activated clotting time; site 1 = New Zealand; site 2 = Lithuania.

Table 3 MRI and NIHSS results

Characteristic	Measurement	Study group	Site 1	Site 2	Control group
Time difference between procedure start and prior MRI (hour)	N	27	20	7	15
	Mean \pm SD	24 \pm 9	22 \pm 7	29 \pm 14	28 \pm 6
	Range	2–46	2–29	15–46	21–48
Time difference between MRI and procedure stop (h)	N	27	20	7	15
	Mean \pm SD	27 \pm 17	21 \pm 3	45 \pm 27	24 \pm 8
	Range	12–70	17–27	12–70	18–49
NIHSS score (preprocedure)	0	25 (92.6)	18 (90.0)	7 (100.0)	13 (86.7)
	1	1 (3.7)	1 (5.0)		2 (13.3)
	Missing	1 (3.7)	1 (5.0)	0	0
NIHSS score (postprocedure)	0	26 (96.3)	19 (95.0)	7 (100.0)	11 (73.3)
	1	1 (3.7)	1 (5.0)		2 (13.3)
	Missing				2 (13.3)
SCE consensus	0	19 (70.4)	12 (60.0)	7 (100.0)	14 (93.3)
	1	8 (29.6)	8 (40.0)		1 (6.7)
SCL consensus	0	26 (96.3)	19 (95.0)	7 (100.0)	15 (100.0)
	1	1 (3.7)	1 (5.0)		
SCE consensus at 30-d to 3-mo follow-up	0	5 (100.0)	4 (100.0)	1 (100.0)	
SCL consensus at 30-d to 3-mo follow-up	0	5 (100.0)	4 (100.0)	1 (100.0)	
SWI consensus*	0	16 (59.3)	9 (45.0)	Missing	14 (93.3)
	1	11 (40.7)	11 (55.0)	Missing	1 (6.7)

All values are n (%), except the time differences (hour).

MRI = magnetic resonance imaging; NIHSS = National Institutes of Health Stroke Scale (0 = normal; 1 = abnormal); SCE = silent cerebral event; SCL = silent cerebral lesion; site 1 = New Zealand; site 2 = Lithuania; SWI = susceptibility weighted imaging.

*For SCE, SCL, and SWI, consensus required agreement of 2 of 3 radiologists on the presence (1) or absence (0) of an abnormality.

the RFB catheter was in the left atrium was >300 seconds in all patients and >350 seconds in 25 patients (93%) (18/20 in New Zealand; 7/7 in Lithuania). Cardioversion was required to achieve sinus rhythm in 9 of the 20 New Zealand patients.

In the control cohort, total procedural time was 112 \pm 29 minutes, total ablation time was 58 \pm 19 minutes, and fluoroscopy time was 14 \pm 19 minutes. The procedure was performed without anticoagulation interruption in all patients.

Safety assessments

MRI

In the RFB cohort, new SCEs were observed in 8 of 27 patients (30%) and a new SCL in 1 patient who also had an SCE (Table 3). In the 22 patients treated with uninterrupted anticoagulation, new SCEs were observed in 7 patients,

whereas in the 3 patients treated with interrupted anticoagulation, a new SCE was observed in 1 patient. SWI revealed 11 focal postprocedural SWI hypointensities in 11 patients in the Christchurch group. SWI data was not obtained in the Lithuanian patients. Clinical characteristics of patients with new SCEs are detailed in Table 4. Mean kappa across the 3 observers was 91% for SCE the presence of SCE on MRI and 86% for SCL.

In the patients with SCEs and SCLs who underwent a follow-up scan, 1 of 4 patients had residual T2 change at the site of a previous DWI abnormality.

There was a difference in new SCEs and SCLs between sites, with no SCEs or SCLs observed in the 7 patients from Lithuania. In patients undergoing cardioversion during the ablation period, SCEs were observed in 2 of 11 patients, whereas SCEs were observed in 6 of the 16 patients who did not require cardioversion.

Table 4 Characteristics of patients with new brain MRI lesions

Patient	Age (y)	Sex	CHADS ₂ -VASc score	Balloon time in left atrium (min)	Percent time at therapeutic ACT	Ablation time (s)	Ablation no.	Interrupted or uninterrupted anticoagulation	Need for cardioversion during procedure
1	58	Female	1	85	100	787	16	Uninterrupted	Yes
2	60	Male	4	100	100	614	10	interrupted	No
3	52	Male	0	70	100	360	6	interrupted	No
4	68	Male	1	87	100	529	11	Uninterrupted	Yes
5	60	Male	1	83	70	736	13	Uninterrupted	No
6	61	Female	1	49	100	393	7	Uninterrupted	No
7	68	Male	1	66	100	600	8	Uninterrupted	No
8	55	Male	1	54	90	649	11	Uninterrupted	No

ACT = activated clotting time; MRI = magnetic resonance imaging.

In the control cohort, new SCEs were observed in 1 of 16 patients (7%). No SCLs were observed in any patients.

Stroke scale

In the RFB cohort, a single patient with a prior stroke had an abnormal stroke scale before the ablation procedure but a normal stroke scale postprocedure. One patient had a new abnormal stroke scale postprocedure with no other clinical signs but did have new SCE on MRI. In the control cohort, 2 patients had new abnormal stroke scales after the procedure.

Esophageal endoscopy

In the RFB cohort, 1 patient had a grade I thermal lesion detected at endoscopy. No ulceration or fistulas were observed.

Adverse cerebral events

In the RFB cohort, no clinical cerebral ischemic events were reported immediately after the procedure. However, new clinical cerebral ischemic events were reported in 2 substudy patients during follow-up. The first patient reported word-finding difficulty that commenced 17 days postprocedure and lasted until the study end. He had a history of stroke and an abnormal NIHSS preprocedure but not postprocedure. His postprocedure MRI showed a new right frontal cortical infarction and possible new left frontal white matter infarction. The second patient had transient expressive dysphasia and right hemianopia 6 months after the ablation procedure.

In the control cohort, no clinical strokes or neurological deficits occurred.

Discussion

We previously reported the clinical results of the first 100 patients who underwent RFA for atrial fibrillation using a novel visually guided RFB system.¹ We found this system offered short procedural times, with good acute and long-term efficacy, and has the potential to provide improved efficiency for ablation of atrial fibrillation relative to point-by-point RFA. Adoption of this novel technology will be dependent on showing that the complication rate compares favorably with those of existing thermal ablation technologies.

Stroke occurs in up to 2% of atrial fibrillation ablation procedures, but we did not observe any periprocedural strokes. Two delayed cerebral events occurred during follow-up, but they are unlikely to be procedure related.

The tiny areas of MRI diffusion restriction (SCE, SCL) in this clinical setting probably represent tiny infarcts or possibly areas of reversible ischemia, and are believed to be due to cerebral emboli and are likely to be an indirect indicator of stroke risk.^{3,4} Previous studies have shown widely ranging rates of SCE (2%–48%) in patients undergoing RFA for atrial fibrillation.^{5,6} The variation likely is due to multiple factors, including procedural anticoagulation management; ablation catheter type; and MRI timing, imaging protocol, sensitivity, and definition of abnormality.

Table 5 Number of cerebral lesions reported by radiologists in the Christchurch cohort

Reviewer no.	Lesions detected		
	SCE	SCL	SWI
1	9	2	25
2	7	1	15
3	3	1	20

SCE = silent cerebral event; SCL = silent cerebral lesion; SWI = susceptibility weighted imaging.

We observed SCEs in 8 of our patients (30%), including 1 SCL in the RFB group, whereas in the control group, only 1 patient (7%) developed a new SCE. No periprocedural clinical strokes were observed, but 2 patients (13%) had new abnormalities on the stroke scale that were uncertain significance. Furthermore, there seemed to be a site difference in the occurrence of SCE in the RFB patients, with new MRI lesions occurring in 8 of 20 patients in New Zealand but 0 of 7 patients in Lithuania. Interpretation of these disparate results is difficult, especially as the numbers are small and the differences may have been due to chance.

Previous studies have suggested that a number of factors may influence the rate of new SCEs after atrial fibrillation ablation.³ Procedures performed with patients on uninterrupted oral anticoagulation may have lower rates than procedures performed with interrupted anticoagulation³; however, SCEs commonly occur even with uninterrupted anticoagulation.⁷ The level of intraprocedural anticoagulation with heparin as measured by the activated partial thromboplastin time does seem to influence the incidence of SCEs, with ACT <250 seconds being associated with higher rates.⁸ For our patients, we followed the 2017 guidelines by performing the procedures with uninterrupted anticoagulation whenever possible, and this was achieved in almost all patients. In addition, heparin was administered during the procedure to maintain minimum ACT >300 seconds in all patients.² A minimum ACT of 350 seconds was achieved in 93% of patients, but a relatively high rate of SCEs still was observed. The timing of heparin administration may help explain the difference in SCE rates observed between the 2 centers, as heparin administration before transseptal puncture has been suggested to reduce the rate of SCEs.⁵ Furthermore, procedural duration would be expected to influence the rate of SCEs, and procedural times were shorter overall in Lithuania. Finally, it has been suggested that the performance of intraprocedural cardioversion may increase the rate of SCE.⁸ However, we did not observe higher rates of SCE in our patients undergoing cardioversion.

Balloon-based ablation systems including cryoballoon and laser balloon seem to have rates of SCE similar to those of RFA.⁹ However, previous reports raise the possibility that multielectrode ablation systems may be associated with higher rates of SCE. The pulmonary vein ablation catheter is a circular catheter that utilizes duty-cycled phased radiofrequency energy to multiple electrode pairs. Initial reports

documented much higher rates of SCE of 37%–39% using this catheter than conventional RFA (7%–8%) and cryoablation (4%–6%) in comparative studies.^{10,11} However, very low rates of SCE with this catheter subsequently were reported by avoiding ablation between electrodes that were in close proximity, submerged catheter introduction, uninterrupted anticoagulation combined with ACT \geq 350 seconds, and changing the electrodes to gold.^{12,13}

SCE rates have been reported for a multielectrode RFB ablation catheter without visual guidance.¹⁴ In the first cohort of patients, the rate of SCEs was 24%; however, with multiple changes to the procedural workflow, including heparinization before transseptal puncture and maintaining ACT $>$ 350 seconds, the SCE rate fell to 7%. Therefore, it is possible that a lower rate of SCEs may have been observed if higher ACT levels had been maintained.

In this report, we document the rates of SCE observed with use of a novel, visually guided, multielectrode RFB ablation catheter. An SCE rate of 30% was noted, which was higher than in our control group of conventional RFA but comparable to initial reports of multielectrode ablation systems. This finding suggests that multielectrode systems are associated with higher rates of SCE than conventional RFA. However, it seems that these rates can be reduced by making changes to the procedural workflow, including uninterrupted anticoagulation, maintaining higher ACTs, and heparinization before transseptal puncture. No SCEs were observed in the 7 patients from Lithuania in whom heparinization was performed before transseptal puncture.

An alternate explanation for the difference in SCE rates between the 2 sites is the sensitivity of the MRI scans. SCEs may be transient,⁴ and because the MRIs were performed, on average, 1 day later in Lithuania, transient lesions may not have been detected. Furthermore, differences in machine characteristics or scanning protocols may have contributed to the difference observed. In this study, SWI was used as a further marker of procedural safety in addition to DWI. Although follow-up of these SWI lesions was not part of the study design, 3 of the 4 patients followed up for DWI abnormalities coincidentally had persisting SWI abnormalities. Although the precise pathophysiology of the SWI lesions is uncertain, their appearance postprocedure almost certainly indicates an underlying embolic process, most likely tiny thrombi due to the presence of the catheter.

There was no significant correlation between the presence of DWI events (ie, SCEs) and the presence of SWI lesions. More SWI than DWI events (11 vs 7) were observed. This implies that SWI is highly sensitive to microembolic events, as previously suggested.¹⁵ The lack of associated DWI changes suggests that most, if not all, SWI abnormalities were nonobstructing. However, in a study of emboli from thrombectomy of intracranial large vessel occlusion, the

SWI abnormalities were associated with larger DWI changes as well.¹⁶ MRI SWI may be a more sensitive test of embolism and may have value in future safety studies.

The other component of this safety study was the assessment of asymptomatic esophageal lesions by upper gastrointestinal endoscopy. We found a reassuringly low rate of abnormality, with only 1 grade I esophageal thermal injury observed. This rate is lower than we previously observed with conventional RFA, for which we noted a 12% incidence of thermal injury.¹⁷ This low rate may reflect the low energies used for ablation, with a maximum of 10 W per channel. It also may reflect the theoretical advantage of bipolar ablation between adjacent electrodes, which can generate continuous but shallower lesions¹⁸ and has the potential to ensure PVI while reducing the risk of collateral damage to adjacent tissues such as the esophagus. As these thermal injuries almost certainly are precursors to the rare but feared atrioesophageal fistula, these data suggest that the RFB catheter should at least not increase the risk of major esophageal injury.

Study limitations

The major limitation of these studies is the small patient numbers. The study and control were done sequentially and not randomized. Radiology interpretation consensus was based on agreement of independently reported findings without interobserver discussion and may have led to reduced lesion detection, given that sensitivity varied considerably from reviewer to reviewer (Table 5). In retrospect, interactive dispute resolution would have allowed debate of imaging findings before arriving at consensus, likely increasing the number of detected lesions (eg, nominal group technique, Delphi method).¹⁸ Although all reviewers were trained radiologists, the lesions were smaller than those normally encountered in daily radiology practice, and detection likely would be better with group feedback and skill improvement. MRI was performed using 2 different scanners with slightly different configurations. Consensus MRI SWI data were only obtained for the New Zealand patients, which makes it difficult to assess the cause of the different adverse event detection rates between the Christchurch and Lithuania subgroups. Therefore, any conclusions must be regarded as hypothesis-generating.

Conclusion

We report the rates of SCLs and esophageal lesions after ablation for atrial fibrillation using a novel visually guided RFB system. We found an incidence of SCEs of 30%, which is higher than the incidence in a comparator group undergoing conventional ablation. We also report a low rate of silent esophageal thermal injury.

Funding Sources: This work was supported by Boston Scientific.

Disclosures: Dr Al-Ahmad has received stock options from Apama and is a consultant to Boston Scientific. Dr Crozier has received research funding and is an investigator with Boston Scientific. All other authors have no conflicts of interest relevant to this study.

Authorship: All authors attest they meet the current ICMJE criteria for authorship.

Patient Consent: Informed consent was obtained from all subjects prior to enrollment.

Ethics Statement: The study was conducted in accordance with the Declaration of Helsinki and was approved by the ethics committees and local regulatory agencies at both sites.

References

- Reddy V, Al-Ahmad A, Aidietis A, et al. A novel visually-guided radiofrequency balloon ablation catheter for pulmonary vein isolation: 1-year outcomes of the multicenter AF-FICIENT-I trial. *Circ Arrhythm Electrophysiol* 2021; 14:e009308.
- Calkins H, Hindricks G, Cappato R, et al. 2017 HRS/EHRA/ECAS/APHRS/SOLAECE expert consensus statement on catheter and surgical ablation of atrial fibrillation: executive summary. *Europace* 2018;20:157–208.
- Deneke T, Jais P, Scaglione M, et al. Silent cerebral events/lesions related to atrial fibrillation ablation: a clinical review. *J Cardiovasc Electrophysiol* 2015; 26:455–463.
- Kidwell C, Alger JR, Di Salle F, et al. Diffusion MRI in patients with transient ischemic attacks. *Stroke* 1999;30:1174–1180.
- Di Biase L, Gaita F, Toso E, et al. Does periprocedural anticoagulation management of atrial fibrillation affect the prevalence of silent thromboembolic lesion detected by diffusion cerebral magnetic resonance imaging in patients undergoing radiofrequency atrial fibrillation ablation with open irrigated catheters? Results from a prospective multicenter study. *Heart Rhythm* 2014;11:791–798.
- Von Bary C, Deneke T, Arentz T, et al. Silent cerebral events as a result of left atrial catheter ablation do not cause neuropsychological sequelae—a MRI-controlled multicenter study. *J Interv Card Electrophysiol* 2015;43:217–226.
- Martinek M, Sigmund E, Lemes C, et al. Asymptomatic cerebral lesions during pulmonary vein isolation under uninterrupted oral anticoagulation. *Europace* 2013;15:325–331.
- Gaita F, Caponi D, Pianelli M, et al. Radiofrequency catheter ablation of atrial fibrillation: a cause of silent thromboembolism? Magnetic resonance imaging assessment of cerebral thromboembolism in patients undergoing ablation of atrial fibrillation. *Circulation* 2010;122:1667–1673.
- Schmidt B, Gunawardene M, Krieg D, et al. A prospective randomized single-center study on the risk of asymptomatic cerebral lesions comparing irrigated radiofrequency current ablation with the cryoballoon and the laser balloon. *J Cardiovasc Electrophysiol* 2013;8:869–874.
- Herrera Siklody C, Deneke T, Hocini M, et al. Incidence of asymptomatic intracranial embolic events after asymptomatic vein isolation: comparison of different atrial fibrillation ablation technologies in a multicenter study. *J Am Coll Cardiol* 2011;58:681–688.
- Gaita F, Leclercq JF, Schumacher B, et al. Incidence of silent cerebral thromboembolic lesions after atrial fibrillation ablation may change according to technology used: comparison of irrigated radiofrequency, multipolar nonirrigated catheter and cryoballoon. *J Cardiovasc Electrophysiol* 2011; 22:961–968.
- Verma A, Debruyne P, Nardi S, et al. Evaluation and reduction of asymptomatic cerebral embolism in ablation of AF, but high prevalence of chronic silent infarction. *Circ Arrhythm Electrophysiol* 2013;6:835–842.
- De Greef Y, Dekker L, Boersma L, et al. Low rate of asymptomatic cerebral embolism and improved procedural efficacy with the novel pulmonary vein ablation catheter GOLD: results of the PRECISION GOLD trial. *Europace* 2016; 18:687–695.
- Grimaldi M, Tondo C, Riva S, et al. Impact of workflow modifications in atrial fibrillation ablation for reducing the incidence of silent cerebral lesions with a new multi-electrode radiofrequency balloon catheter. Poster presentation P1033. European Society of Cardiology Congress 2019, August 31–September 4, 2019, Paris, France.
- Klinger-Gratz PP, Schroth G, Gralla J, et al. Protected stent retriever thrombectomy prevents iatrogenic emboli in new vascular territories. *Neuroradiology* 2015;57:1045–1054.
- Schönfeld MH, Kabiri R, Kniep HC, et al. Sub-angiographic peripheral emboli in high resolution DWI after endovascular recanalization. *J Neurol* 2020; 267:1401–1406.
- Daly M, Melton M, Roper G, Lim G, Crozier I. High-resolution infrared thermography of esophageal temperature during radiofrequency ablation of atrial fibrillation. *Circ Arrhythm Electrophysiol* 2018;1:e005667.
- Yan S, Wu X, Wang W. Theoretical and experimental analysis of amplitude control ablation and bipolar ablation in creating linear lesion and discrete lesions for treating atrial fibrillation. *Int J Hypertherm* 2017; 33:608–616.