

Dermatofibrosarcoma protuberans in adolescence: a case report and literature review

Vaikų dermatofibrosarkoma: klinikinis atvejis ir literatūros apžvalga

Agnietė Valiulytė¹, Milda Gudavičiūtė², Kęstutis Trainavičius², Dmitrij Šeinin³

¹ Faculty of Medicine, Vilnius University, M. K. Čiurlionio Str. 21, LT-03101 Vilnius, Lithuania

² Department of Pediatric Surgery, Children's Hospital, Affiliate of Vilnius University Hospital Santariskiu Klinikos, Santariskiu Str. 7, LT-08406 Vilnius, Lithuania

³ National Centre of Pathology, Affiliate of Vilnius University Hospital Santariskiu Klinikos
E-mail: kestutis.trainavicius@vuvl.lt

Dermatofibrosarcoma protuberans yra itin retas vaikų piktybinis navikas. Nurodoma, kad klasikinė dermatofibrosarkomos forma labai retai metastazuoja, o fibrosarkominei jos transformacijai dažnai būdingos metastazės. Mes aprašome išopėjusios dešinėsios šlaunies dermatofibrosarkomos atvejį septyniolikos metų berniukui. Navikas buvo radikaliai pašalintas. Po vienerių metų atkryčio nerasta.

Reikšminiai žodžiai: vaikų dermatofibrosarkoma, minkštųjų audinių sarkomos, fibrosarkominė transformacija, chirurginis gydymas

Dermatofibrosarcoma protuberans is a very rare malignant neoplasm in children. It is reported that the classic form of dermatofibrosarcoma has a very limited metastatic potential, while a fibrosarcomous transformation of *dermatofibrosarcoma protuberans* has a much higher potential. We present a case of a 17-year-old boy with a huge ulcerated mass (17 x 15 cm) on his right thigh. At operation, the pathological diagnosis was *dermatofibrosarcoma protuberans* with a fibrosarcomous component. All lesions were removed by surgical excision with a margin of 1.5 to 3 cm. After one year, there is no evidence of tumor recurrence.

Key words: *dermatofibrosarcoma protuberans* in children, soft tissue sarcomas, fibrosarcomous transformation, surgical treatment

Introduction

Dermatofibrosarcoma protuberans (DFSP) was first described as a distinct clinicopathologic entity in 1924 (1), and it was approximately 30 years later when the tumor was first described in a child (2). Epidemiology shows 0.8–4.2 cases per million persons per year and accounts for between 2% and 6% of all soft tissue sarcomas (3). It is an uncommon malignant neoplasm of the deep

dermis and subcutaneous tissue, mostly affecting young and middle-aged adults (4). Men and women are equally affected (5). According to the WHO classification of the mesenchymal tumors, DFSP is an intermediate-grade, locally-aggressive tumor which recurs commonly but metastasizes very rarely (5). Because of a high local recurrence rate, the benchmark of the therapy is a wide surgical excision. On the other hand, complete resection

carries the risk of a severe mutilation in relatively small children (6).

The alternative treatment options, such as chemotherapy or radiotherapy, have only minimal therapeutic effects (3). A novel targeted antitumor treatment is based on the specific molecular characterization of the DFSP. In over 90% of cases there is a 17q22; 22q13 translocation leading to a constitutive activation of the platelet-derived growth factor receptor (PDGFR) followed by a continuous stimulation of the tumor cells to grow (3, 5, 6). Initial studies with imatinib mesylate, a PDGF receptor-specific oral tyrosine kinase inhibitor, showed a response rate of 65% in patients with extensive local, recurrent or metastatic DFSP (5).

Case report

A 17-year-old boy had initially presented to a pediatric surgeon with a tumor on the proximal part of his right thigh. The mass measured 15 by 17 cm. It was irregular in form, fairly hard, and the overlying skin was tense and ulcerated.

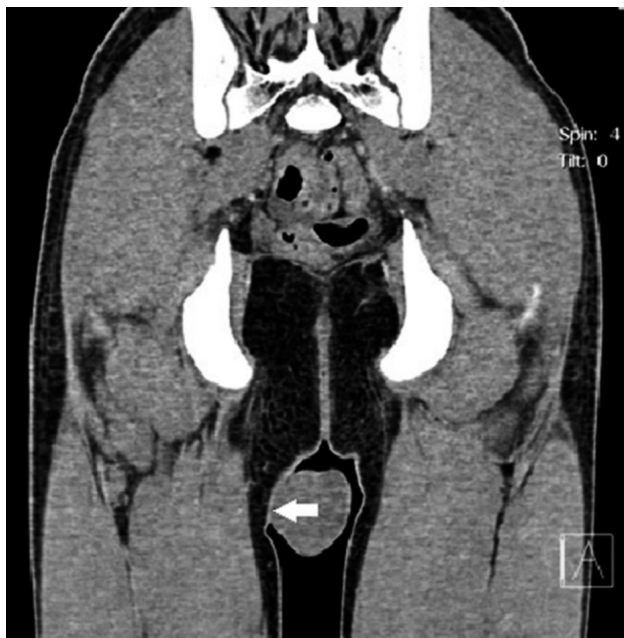

Figure 1. Anterior contrast-enhanced CT scan shows a superficial soft tissue mass. Nonhomogeneous accumulation of contrast can be seen. It does not appear to invade the adjacent subcutaneous fat (white arrow)

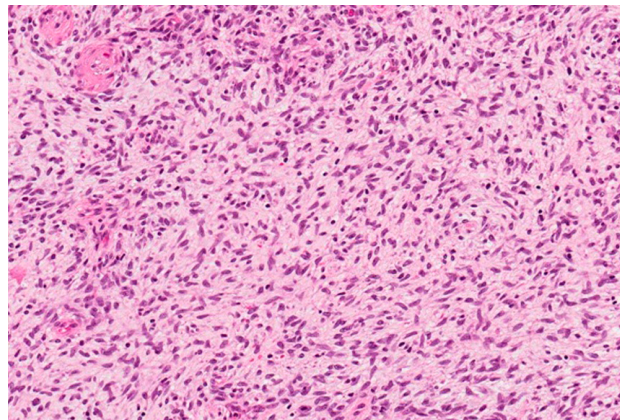


Figure 2. DFSP: uniform, mildly atypical tumor cells arranged in a storiform pattern. Hematoxylin–eosin staining, x200

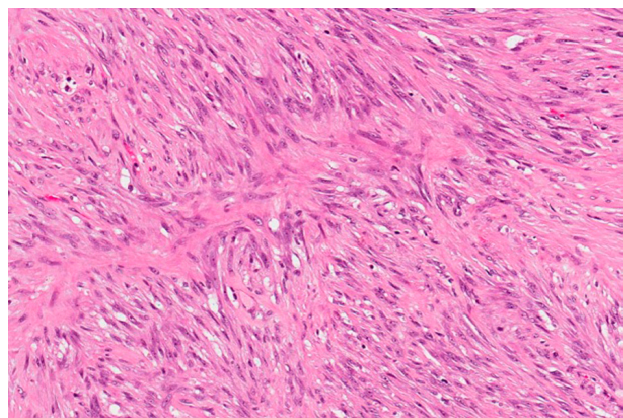


Figure 3. Fibrosarcomatous transformation of DFSP. Hematoxylin–eosin staining, x200

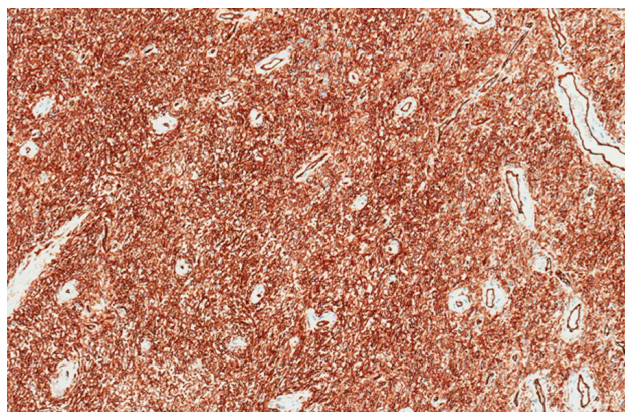


Figure 4. DFSP cells displaying positivity for CD34. x100

Ultrasound revealed an irregular nonhomogeneous tumor with some signs of calcification. A color Doppler showed a good blood flow in the mass. CT clearly defined a homogeneous tumor in the dermis and subcutaneous tissue with a local contact to the right gracilis muscle (Figure 1). On post contrast CT, the tumor showed nonhomogeneous accumulation of contrast.

The potential malignancy of the tumor was predicted by its rapid growth, ulceration, and bleeding. The physical examination showed that the tumor was in the skin and subcutaneous tissue. CT revealed a limited, local growth of the tumor. It was decided to remove it surgically.

A spindle-shaped incision was made. The blood vessels were ligatured, and the mass was removed intact. Bone marrow biopsies were taken from both sides of the iliac wings to ascertain there were no metastases.

Histologically, the tumor was composed of a fibrous and myxoid tissue and variously cellular sheets of spindle-shaped cells with eosinophilic cytoplasm and uniform elongated nuclei. The tumor showed up to 5 mitoses per 10 HPF (Figure 2) and had areas with longitudinal fascicles of atypical spindle cells demonstrating more prominent nuclear atypia and mitotic activity: up to 10 mitoses per 10 HPF (fibrosarcomatous transformation). (Figure 3). The tumor cells were positive for CD34 and negative for heavy caldesmon, EMA, keratins, S100 protein, smooth muscle actin, desmin, myogenin, and MyoD1. (Figure 4). By RT-PCR analysis, the tumor exhibited t(17;22)(q22;g13) COL1A1/PDGFB translocation.

The tumor reached the margin of the surgical excision. There were no metastases in the bone marrow biopsies. After reoperation, the histological examination showed no residual tumor.

Discussion

Dermatofibrosarcoma protuberans (DFSP) is a low – intermediate – grade cutaneous sarcoma which is rare in adults and even less common in children (7). Nevertheless, it is the most frequent skin sarcoma (3). DFSP shows a locally invasive and aggressive behavior and has a high recurrence rate but a limited metastatic potential (1% to 4%) (4, 5). The metastatic potential depends on tumor type. Normally, DFSP is considered to be a tumor of low-grade malignancy. Rarely, this “classic”

form can transform into fibrosarcomous DFSP (DFSP-FS), a more aggressive tumor with a higher metastatic potential (8) which may require a more intensive treatment approach.

In this age group, there are a number of soft tissue neoplasms which can have a similar appearance, location and growth type. The most common site of DFSP is the limbs (41%) and trunk (39%) (6). However, rhabdomyosarcoma is the most common soft tissue sarcoma in children (9) and may present on the limbs. Furthermore, rhabdomyosarcoma progresses quickly, and our patient complained that the mass grew in a year. About a quarter of primary leiomyosarcoma occur on the lower limbs, but usually they present in younger children. These tumors have very different treatment options. The decision to operate was based on the local growth of the tumor.

More than 90% of DFSP have a unique translocation involving chromosomes 17 and 22. Usually, CD34 is one of the most useful stains to differentiate DFSP from other soft tissue tumors. In approximately 3.2–15% of DFSP the tumor contains a high-grade fibrosarcomous component (3) which may present 20% to 80% of the tumor mass. These areas usually have a focal or diffuse loss of CD34 (10). A biopsy may hit the CD34-negative areas and give false negative results for dermatofibrosarcoma. In these cases, the RT-PCR analysis to determine translocation could be useful to diagnose dermatofibrosarcoma.

The primary treatment for DFSP is complete resection (3). The best method to remove these lesions is the Mohs micrographic surgery (1, 3) with a recurrence rate of 1.5% (2). In view of the infiltrative nature of DFSP, a wide excision (removal of 2–3 cm of uninvolved skin and the *en bloc* removal of the underlying subcutaneous tissue and fascia) had been widely accepted as the main treatment option (12). Furthermore, the average recurrence rate after a wide excision has been reported to be 8.8% (3). However, in our case, a wide surgical excision could cause considerable cosmetic and functional deformities. On the other hand, it has been reported that using conservative surgical margins the local recurrence rate may reach 39.7% (3). Our decision was to excise as widely as possible but leaving the least possible cosmetic and functional deformity.

However, the postoperative positive surgical margins forced us to consider additional treatment options. *Dermatofibrosarcoma protuberans* is a radio-responsive tumor. The addition of postoperative radiotherapy reduces the risk of local recurrence in patients with narrow or positive surgical margins (13). Because of the high risk of gonadal dysfunction this treatment option was not suitable for our patient.

DFSP with fibrosarcomous transformation is resistant to conventional chemotherapy (3). A limited

number of studies show that Imatinib mesylate can be effective in such cases (3, 5, 6). Unfortunately, our clinic is not able to offer this treatment because of its high costs. Reoperation was performed, and no residual tumor was found. After one year, there is no evidence of tumor recurrence.

Conflict of interests

None of the authors have declared any conflict of interests.

REFERENCES

1. Jafarian F, McCuaig C, Kokta V, et al. Dermatofibrosarcoma protuberans in childhood and adolescence: report of eight patients. *Pediatr Dermatol* 2008; 25: 317–325.
2. Checketts SR, Hamilton TK, Baughman RD. Congenital and childhood dermatofibrosarcoma protuberans: a case report and review of the literature. *J Am Acad Dermatol* 2000; 42: 907–913.
3. Lemm D, Mügge LO, Mentzel T, et al. Current treatment options in dermatofibrosarcoma protuberans. *J Cancer Res Clin Oncol* 2009; 135: 653–665.
4. Suzuki D, Kobayashi R, Yasuda K, et al. Congenital Dermatofibrosarcoma Protuberans in a Newborn Infant With a Massive Back Tumor: Favorable Effects of Oral Imatinib on the Control of Residual Tumor Growth. *J Pediatr Hematol Oncol* 2011; 33: 304–306.
5. Ugurel S, Kortmann R.D., Mohr P, et al. Short German guidelines: dermatofibrosarcoma protuberans. *J Dtsch Dermatol Ges* 2008; 6: 17–18.
6. Gooskens SL, Oranje AP, van Adrichem LN, et al. Imatinib mesylate for children with dermatofibrosarcoma protuberans (DFSP). *Pediatr Blood Cancer* 2010; 55: 369–373.
7. Marcus JR, Few JW, Senger C, et al. Dermatofibrosarcoma protuberans and the Bednar tumor: treatment in the pediatric population. *J Pediatr Surg* 1998; 33: 1811–1814.
8. Bowne WB, Antonescu CR, Leung DH, et al. Dermatofibrosarcoma protuberans: A clinicopathologic analysis of patients treated and followed at a single institution. *Cancer* 2000; 88: 2711–2720.
9. Pinkel D, Pickren J. Rhabdomyosarcoma in children. *JAMA* 1961; 175: 293–298.
10. Abbott JJ, Oliveira AM, Nascimento AG: The prognostic significance of fibrosarcomatous transformation in dermatofibrosarcoma protuberans. *Am J Surg Pathol.* 2006; 30: 436–443.
11. Gloster HM Jr. Dermatofibrosarcoma protuberans. *J Am Acad Dermatol* 1996; 35: 355–374.
12. Martin L, Piette F, Blanc P, et al. Clinical variants of the preprotuberant stage of dermatofibrosarcoma protuberans. *Br J Dermatol* 2005; 153(5): 932–926.
13. Ballo MT, Zagars GK, Pisters P, et al. The role of radiation therapy in the management of dermatofibrosarcoma protuberans. *Int J Radiat Oncol Biol Phys* 1998; 40(4): 823–827.