

World Journal of *Clinical Cases*

World J Clin Cases 2022 May 16; 10(14): 4327-4712



OPINION REVIEW

- 4327 Emerging role of biosimilars in the clinical care of inflammatory bowel disease patients
Najeeb H, Yasmin F, Surani S

MINIREVIEWS

- 4334 Practical insights into chronic management of hepatic Wilson's disease
Lynch EN, Campani C, Innocenti T, Dragoni G, Forte P, Galli A
- 4348 Adipose-derived stem cells in the treatment of hepatobiliary diseases and sepsis
Satilmis B, Cicek GS, Cicek E, Akbulut S, Sahin TT, Yilmaz S

ORIGINAL ARTICLE**Clinical and Translational Research**

- 4357 Learning curve for a surgeon in robotic pancreaticoduodenectomy through a "G"-shaped approach: A cumulative sum analysis
Wei ZG, Liang CJ, Du Y, Zhang YP, Liu Y
- 4368 Clinical and prognostic significance of expression of phosphoglycerate mutase family member 5 and Parkin in advanced colorectal cancer
Wu C, Feng ML, Jiao TW, Sun MJ

Case Control Study

- 4380 Significance of preoperative peripheral blood neutrophil-lymphocyte ratio in predicting postoperative survival in patients with multiple myeloma bone disease
Xu ZY, Yao XC, Shi XJ, Du XR

Retrospective Study

- 4395 Association between depression and malnutrition in pulmonary tuberculosis patients: A cross-sectional study
Fang XE, Chen DP, Tang LL, Mao YJ
- 4404 Pancreatic cancer incidence and mortality patterns in 2006-2015 and prediction of the epidemiological trend to 2025 in China
Yin MY, Xi LT, Liu L, Zhu JZ, Qian LJ, Xu CF
- 4414 Evaluation of short- and medium-term efficacy and complications of ultrasound-guided ablation for small liver cancer
Zhong H, Hu R, Jiang YS

- 4425 Hematopoiesis reconstitution and anti-tumor effectiveness of Pai-Neng-Da capsule in acute leukemia patients with haploidentical hematopoietic stem cell transplantation

Yuan JJ, Lu Y, Cao JJ, Pei RZ, Gao RL

- 4436 Oral and maxillofacial pain as the first sign of metastasis of an occult primary tumour: A fifteen-year retrospective study

Shan S, Liu S, Yang ZY, Wang TM, Lin ZT, Feng YL, Pakezhati S, Huang XF, Zhang L, Sun GW

- 4446 Reduced serum high-density lipoprotein cholesterol levels and aberrantly expressed cholesterol metabolism genes in colorectal cancer

Tao JH, Wang XT, Yuan W, Chen JN, Wang ZJ, Ma YB, Zhao FQ, Zhang LY, Ma J, Liu Q

Observational Study

- 4460 Correlation of pressure gradient in three hepatic veins with portal pressure gradient

Wang HY, Song QK, Yue ZD, Wang L, Fan ZH, Wu YF, Dong CB, Zhang Y, Meng MM, Zhang K, Jiang L, Ding HG, Zhang YN, Yang YP, Liu FQ

- 4470 Multi-slice spiral computed tomography in diagnosing unstable pelvic fractures in elderly and effect of less invasive stabilization

Huang JG, Zhang ZY, Li L, Liu GB, Li X

SYSTEMATIC REVIEWS

- 4480 Distribution and changes in hepatitis C virus genotype in China from 2010 to 2020

Yang J, Liu HX, Su YY, Liang ZS, Rao HY

CASE REPORT

- 4494 Bow hunter's syndrome successfully treated with a posterior surgical decompression approach: A case report and review of literature

Orlandi N, Cavallieri F, Grisendi I, Romano A, Ghadirpour R, Napoli M, Moratti C, Zanichelli M, Pascarella R, Valzania F, Zedde M

- 4502 Histological remission of eosinophilic esophagitis under asthma therapy with IL-5 receptor monoclonal antibody: A case report

Huguenot M, Bruhm AC, Essig M

- 4509 Cutaneous mucosa-associated lymphoid tissue lymphoma complicating Sjögren's syndrome: A case report and review of literature

Liu Y, Zhu J, Huang YH, Zhang QR, Zhao LL, Yu RH

- 4519 Plexiform neurofibroma of the cauda equina with follow-up of 10 years: A case report

Chomanskis Z, Jusky R, Cepkus S, Dulko J, Hendrixson V, Ruksenas O, Rocka S

- 4528 Mixed porokeratosis with a novel mevalonate kinase gene mutation: A case report

Xu HJ, Wen GD

- 4535 Isolated pancreatic injury caused by abdominal massage: A case report

Sun BL, Zhang LL, Yu WM, Tuo HF

- 4541** Bronchiolar adenoma with unusual presentation: Two case reports
Du Y, Wang ZY, Zheng Z, Li YX, Wang XY, Du R
- 4550** Periodontal-orthodontic interdisciplinary management of a “periodontally hopeless” maxillary central incisor with severe mobility: A case report and review of literature
Jiang K, Jiang LS, Li HX, Lei L
- 4563** Anesthesia management for cesarean section in a pregnant woman with odontogenic infection: A case report
Ren YL, Ma YS
- 4569** Convulsive-like movements as the first symptom of basilar artery occlusive brainstem infarction: A case report
Wang TL, Wu G, Liu SZ
- 4574** Globe luxation may prevent myopia in a child: A case report
Li Q, Xu YX
- 4580** Computer tomography-guided negative pressure drainage treatment of intrathoracic esophagojejunal anastomotic leakage: A case report
Jiang ZY, Tao GQ, Zhu YF
- 4586** Primary or metastatic lung cancer? Sebaceous carcinoma of the thigh: A case report
Wei XL, Liu Q, Zeng QL, Zhou H
- 4594** Perianesthesia emergency repair of a cut endotracheal tube’s inflatable tube: A case report
Wang TT, Wang J, Sun TT, Hou YT, Lu Y, Chen SG
- 4601** Diagnosis of cytomegalovirus encephalitis using metagenomic next-generation sequencing of blood and cerebrospinal fluid: A case report
Xu CQ, Chen XL, Zhang DS, Wang JW, Yuan H, Chen WF, Xia H, Zhang ZY, Peng FH
- 4608** Primary sigmoid squamous cell carcinoma with liver metastasis: A case report
Li XY, Teng G, Zhao X, Zhu CM
- 4617** Acute recurrent cerebral infarction caused by moyamoya disease complicated with adenomyosis: A case report
Zhang S, Zhao LM, Xue BQ, Liang H, Guo GC, Liu Y, Wu RY, Li CY
- 4625** Serum-negative Sjogren's syndrome with minimal lesion nephropathy as the initial presentation: A case report
Li CY, Li YM, Tian M
- 4632** Successful individualized endodontic treatment of severely curved root canals in a mandibular second molar: A case report
Xu LJ, Zhang JY, Huang ZH, Wang XZ

- 4640** Successful treatment in one myelodysplastic syndrome patient with primary thrombocytopenia and secondary deep vein thrombosis: A case report
Liu WB, Ma JX, Tong HX
- 4648** Diagnosis of an extremely rare case of malignant adenomyoepithelioma in pleomorphic adenoma: A case report
Zhang WT, Wang YB, Ang Y, Wang HZ, Li YX
- 4654** Management about intravesical histological transformation of prostatic mucinous carcinoma after radical prostatectomy: A case report
Bai SJ, Ma L, Luo M, Xu H, Yang L
- 4661** Hepatopulmonary metastases from papillary thyroid microcarcinoma: A case report
Yang CY, Chen XW, Tang D, Yang WJ, Mi XX, Shi JP, Du WD
- 4669** PD-1 inhibitor in combination with fruquintinib therapy for initial unresectable colorectal cancer: A case report
Zhang HQ, Huang CZ, Wu JY, Wang ZL, Shao Y, Fu Z
- 4676** Cutaneous metastasis from esophageal squamous cell carcinoma: A case report
Zhang RY, Zhu SJ, Xue P, He SQ
- 4684** Rare pattern of Maisonneuve fracture: A case report
Zhao B, Li N, Cao HB, Wang GX, He JQ
- 4691** Suprasellar cistern tuberculoma presenting as unilateral ocular motility disorder and ptosis: A case report
Zhao BB, Tian C, Fu LJ, Zhang XB
- 4698** Development of plasma cell dyscrasias in a patient with chronic myeloid leukemia: A case report
Zhang N, Jiang TD, Yi SH
- 4704** Ovarian growing teratoma syndrome with multiple metastases in the abdominal cavity and liver: A case report
Hu X, Jia Z, Zhou LX, Kakongoma N

LETTER TO THE EDITOR

- 4709** Perfectionism and mental health problems: Limitations and directions for future research
Nazari N

ABOUT COVER

Editorial Board Member of *World Journal of Clinical Cases*, Jamir Pitton Rissardo, MD, Academic Research, Adjunct Associate Professor, Research Associate, Department of Medicine, Federal University of Santa Maria, Santa Maria 97105110, Brazil. jamirrissardo@gmail.com

AIMS AND SCOPE

The primary aim of *World Journal of Clinical Cases* (*WJCC*, *World J Clin Cases*) is to provide scholars and readers from various fields of clinical medicine with a platform to publish high-quality clinical research articles and communicate their research findings online.

WJCC mainly publishes articles reporting research results and findings obtained in the field of clinical medicine and covering a wide range of topics, including case control studies, retrospective cohort studies, retrospective studies, clinical trials studies, observational studies, prospective studies, randomized controlled trials, randomized clinical trials, systematic reviews, meta-analysis, and case reports.

INDEXING/ABSTRACTING

The *WJCC* is now indexed in Science Citation Index Expanded (also known as SciSearch®), Journal Citation Reports/Science Edition, Scopus, PubMed, and PubMed Central. The 2021 Edition of Journal Citation Reports® cites the 2020 impact factor (IF) for *WJCC* as 1.337; IF without journal self cites: 1.301; 5-year IF: 1.742; Journal Citation Indicator: 0.33; Ranking: 119 among 169 journals in medicine, general and internal; and Quartile category: Q3. The *WJCC*'s CiteScore for 2020 is 0.8 and Scopus CiteScore rank 2020: General Medicine is 493/793.

RESPONSIBLE EDITORS FOR THIS ISSUE

Production Editor: *Hua-Ge Yan*, Production Department Director: *Xu Guo*, Editorial Office Director: *Jin-Lei Wang*.

NAME OF JOURNAL

World Journal of Clinical Cases

ISSN

ISSN 2307-8960 (online)

LAUNCH DATE

April 16, 2013

FREQUENCY

Thrice Monthly

EDITORS-IN-CHIEF

Bao-Gan Peng, Jerzy Tadeusz Chudek, George Kontogeorgos, Maurizio Serati, Ja Hyeon Ku

EDITORIAL BOARD MEMBERS

<https://www.wjgnet.com/2307-8960/editorialboard.htm>

PUBLICATION DATE

May 16, 2022

COPYRIGHT

© 2022 Baishideng Publishing Group Inc

INSTRUCTIONS TO AUTHORS

<https://www.wjgnet.com/bpg/gerinfo/204>

GUIDELINES FOR ETHICS DOCUMENTS

<https://www.wjgnet.com/bpg/GerInfo/287>

GUIDELINES FOR NON-NATIVE SPEAKERS OF ENGLISH

<https://www.wjgnet.com/bpg/gerinfo/240>

PUBLICATION ETHICS

<https://www.wjgnet.com/bpg/GerInfo/288>

PUBLICATION MISCONDUCT

<https://www.wjgnet.com/bpg/gerinfo/208>

ARTICLE PROCESSING CHARGE

<https://www.wjgnet.com/bpg/gerinfo/242>

STEPS FOR SUBMITTING MANUSCRIPTS

<https://www.wjgnet.com/bpg/GerInfo/239>

ONLINE SUBMISSION

<https://www.f6publishing.com>

Plexiform neurofibroma of the cauda equina with follow-up of 10 years: A case report

Zilvinas Chomanskis, Raimondas Jusky, Saulius Cepkus, Justyna Dulko, Vaiva Hendrixson, Osvaldas Ruksenas, Saulius Rocka

Specialty type: Medicine, research and experimental

Provenance and peer review: Unsolicited article; Externally peer reviewed.

Peer-review model: Single blind

Peer-review report's scientific quality classification

Grade A (Excellent): 0
Grade B (Very good): B, B
Grade C (Good): 0
Grade D (Fair): 0
Grade E (Poor): 0

P-Reviewer: Ma X, China; Munakomi S, Nepal

Received: August 2, 2021

Peer-review started: August 2, 2021

First decision: September 28, 2021

Revised: October 9, 2021

Accepted: March 25, 2022

Article in press: March 25, 2022

Published online: May 16, 2022



Zilvinas Chomanskis, Saulius Rocka, Department of Neurology and Neurosurgery, Institute of Clinical Medicine, Faculty of Medicine, Vilnius University, Vilnius 03104, Lithuania

Raimondas Jusky, Anatomy, Histology and Anthropology Department, Vilnius University, Faculty of Medicine, Vilnius 03104, Lithuania

Saulius Cepkus, Department of Neurosurgery, Republican Vilnius University Hospital, Vilnius 04130, Lithuania

Justyna Dulko, Faculty of Medicine, Vilnius University, Vilnius 03104, Lithuania

Vaiva Hendrixson, Institute of Biomedicine, Faculty of Medicine, Vilnius University, Vilnius 03104, Lithuania

Osvaldas Ruksenas, Institute of Biosciences, Life Sciences Centre, Vilnius University, Vilnius 10257, Lithuania

Corresponding author: Raimondas Jusky, MD, Assistant, Anatomy, Histology and Anthropology Department, Vilnius University, Faculty of Medicine, Ciurlionio str. 21, Vilnius 03104, Lithuania. raimondas.juskys@mf.vu.lt

Abstract

BACKGROUND

Plexiform neurofibromas are extremely rarely found in the region of cauda equina and can pose a significant challenge in the diagnostic and management sense. To our knowledge, only 7 cases of cauda equina neurofibromatosis (CENF) have been reported up-to-date.

CASE SUMMARY

We describe a case of a 55-year-old man with a 10 years history of progressive lower extremities weakness and bladder dysfunction. Before presenting, patient was misdiagnosed with idiopathic polyneuropathy. Lumbar spine MRI revealed a tortuous tumorous masses in the cauda equina region, extending through the Th12-L4 vertebrae. The patient underwent Th12-L3 Laminectomy with duraplasty. During the operation, the most enlarged electroneurographically silent nerve root was resected, anticipating inadequate decompression if nerve root was spared. The patient's neurological condition improved post-operatively, but urinary retention became the major complaint. We provide a follow-up period of

10 years. During this time, the patient's condition progressively worsened despite extensive decompression. The consequent MRI scans showed progressive enlargement of cauda equina roots and increasing lumbar stenosis, predominantly affecting L3-L4 segment. During the follow-up 8 years after the operation, the patient complained of worsening lower extremities sensorimotor function and neurogenic claudication. Subsequent MRI revealed lumbar spine stenosis at the level of L3-L4, requiring further decompression. The patient underwent a second surgery involving L4-L5 Laminectomy with duraplasty and L2-L5 transpedicular fixation. The post-operative period was uneventful. Latest follow-up 18 mo after the second surgery revealed substantial improvement in patient's well-being.

CONCLUSION

CENF should be kept in mind during the differential diagnostic work-up for polyneuropathies. Management with an extensive decompression, duraplasty and primary spinal fixation represents a rational approach to achieve a sustained symptomatic improvement and superior overall outcome.

Key Words: Cauda equina; Plexiform neurofibroma; Neurofibromatosis type I; Spine; Spinal tumor; Case report

©The Author(s) 2022. Published by Baishideng Publishing Group Inc. All rights reserved.

Core Tip: Plexiform neurofibroma manifestation in the region of cauda equina is an exceptionally rare event, as only 7 cases were described in the literature up-to-date. We present the 8th such case with the follow-up period of 10 years. Diagnosis was delayed because patient was initially misdiagnosed with the idiopathic polyneuropathy. In order to minimize the necessity for additional interventions in the future, we would recommend to pursue an extensive decompression with duraplasty and primary spinal fixation as the initial management of choice. However, we would strongly suggest to abstain from tumor resection attempts as risk of neurological complications is high.

Citation: Chomanskis Z, Juskys R, Cepkus S, Dulko J, Hendrixson V, Ruksenas O, Rocka S. Plexiform neurofibroma of the cauda equina with follow-up of 10 years: A case report. *World J Clin Cases* 2022; 10(14): 4519-4527

URL: <https://www.wjgnet.com/2307-8960/full/v10/i14/4519.htm>

DOI: <https://dx.doi.org/10.12998/wjcc.v10.i14.4519>

INTRODUCTION

Neurofibromas are benign nerve sheath tumors formed by a combined proliferation of different histological elements of a peripheral nerve. Two types of neurofibromas have been described according to their extent of tissue involvement[1]. Localized form, which can grow on the skin or as a peripheral nerve lesion, is the most common type seen and represents about 90% of all neurofibromas. Localized neurofibromas have minimal malignant potential, in the majority of cases are sporadic, and present as a solitary mass, but individuals with neurofibromatosis type 1 (NF-1) tend to develop multiple lesions distributed in a diffuse fashion throughout the neural and cutaneous tissues[2]. The second type is plexiform neurofibroma – these tumors grow within the bundles of nervous tissues such as trunks and plexuses. This morphological aspect of neurofibromas makes the surgery difficult and radical tumor excision without neurological compromise virtually impossible. Plexiform lesions are said to have about 10% life-time risk to transform into malignant peripheral nerve sheath tumor and is significantly more likely in NF-1 population[3,4].

The cauda equina region is an extremely uncommon location for plexiform neurofibromas. Only seven cases of plexiform neurofibromas of the cauda equina (CENF) have been reported in the literature up-to-date[5-11]. Here we present a case of cauda equina plexiform neurofibroma with a follow-up period of 10 years.

CASE PRESENTATION

Chief complaints

A 55-year-old Lithuanian man presented with a progressive weakness in his lower extremities, fasciculations, difficulty urinating, and sexual dysfunction.

History of present illness

Weakness and fasciculations started about 10 years ago and progressed insidiously. Difficulties in urinating and sexual dysfunction started a few years ago and were only revealed after careful history taking.

History of past illness

The patient was previously diagnosed with idiopathic sensorimotor polyneuropathy. There was no history of other comorbidities, surgeries, allergies, or use of medications.

Personal and family history

Patient denied the history of smoking, alcohol or substance abuse. The family history was unremarkable.

Physical examination

During the initial examination, patient vitals were normal (temperature 36.6 °C, respiratory rate 13 times/min, heart rate 69 bpm, and blood pressure 124/81 mmHg). Patient was slightly overweight (body mass index 26 kg/m²). Neurological examination revealed an absence of deep tendon reflexes in the lower extremities with diminished muscle strength, calf muscles atrophy, and mild impairment in proprioceptive and vibratory sensation bilaterally. Further neurological and general examination was unrevealing.

Laboratory examinations

Complete blood count, biochemical analysis (including electrolytes, hepatic/renal and inflammatory markers), and coagulation testing were all within the normal values.

Imaging examinations

An initial instrumental investigation with electroneurography showed sensorimotor axonopathy of the left leg, whereas electromyography demonstrated an ongoing chronic denervation/reinnervation pattern in the muscles of the both legs.

Given the long history of the disease with a progressive course and inconclusive neurophysiological study results, a gadolinium-enhanced lumbar spine magnetic resonance imaging (MRI) was performed. Imaging modality revealed a non-enhancing intradural tumor stretching out through the levels of Th12-L4 vertebrae. Diffusely enlarged, tortuous cauda equina roots were squeezed inside congenitally narrow spinal canal ([Figure 1](#)).

FINAL DIAGNOSIS

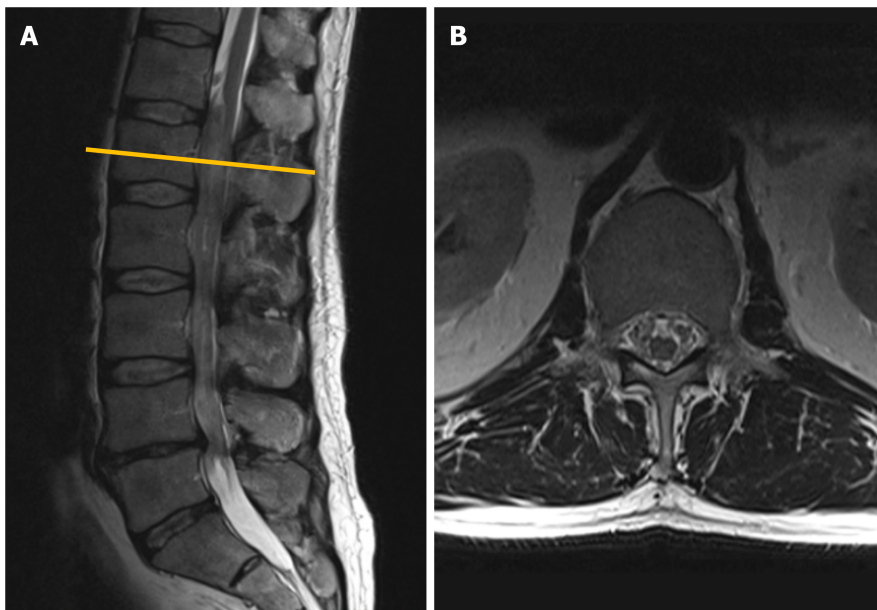
The final diagnosis of the presented case is plexiform neurofibroma of cauda equina. It was proven after the histopathological examination following the surgical treatment.

TREATMENT

Given the likelihood of symptomatic progression and unclear pathological diagnosis, the surgical treatment was pursued – patient underwent Th12-L3 Laminectomy with duraplasty and biopsy of the lesion. During the operation, a few diffusely enlarged nerve roots were identified, with one nerve root being noticeably bulkier than the rest ([Figure 2](#)). The remaining nerve roots and conus medullaris were dislocated to the right. After careful intraoperative neuromonitoring, the decision to resect the most enlarged nerve root was made. The following surgical intervention was limited to the separation of adhesions between damaged roots and subsequent duraplasty with fascia lata graft.

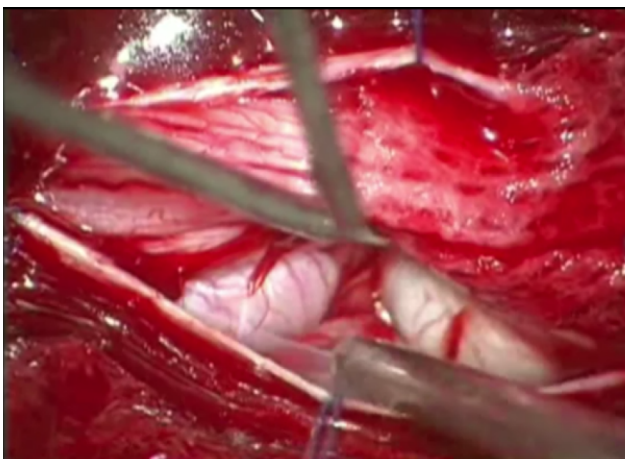
OUTCOME AND FOLLOW-UP

Following the surgery, a slight improvement in sensorimotor function was concealed by development of permanent urinary retention. The histopathological study of biopsy material revealed a hypocellular



DOI: 10.12998/wjcc.v10.i14.4519 Copyright ©The Author(s) 2022.

Figure 1 Contrast-enhanced magnetic resonance imaging (T2-weighted imaging sequence) performed in 2010 revealed a non-enhancing intradural tumor extending throughout the Th12-L4 vertebral levels. A: Sagittal plane: a non-enhancing intradural tumor extending throughout the Th12-L4 vertebral levels; B: Axial plane. Tumor at the level of L1 vertebral body. Note few enlarged lumbar nerve roots engulfing conus medullaris.



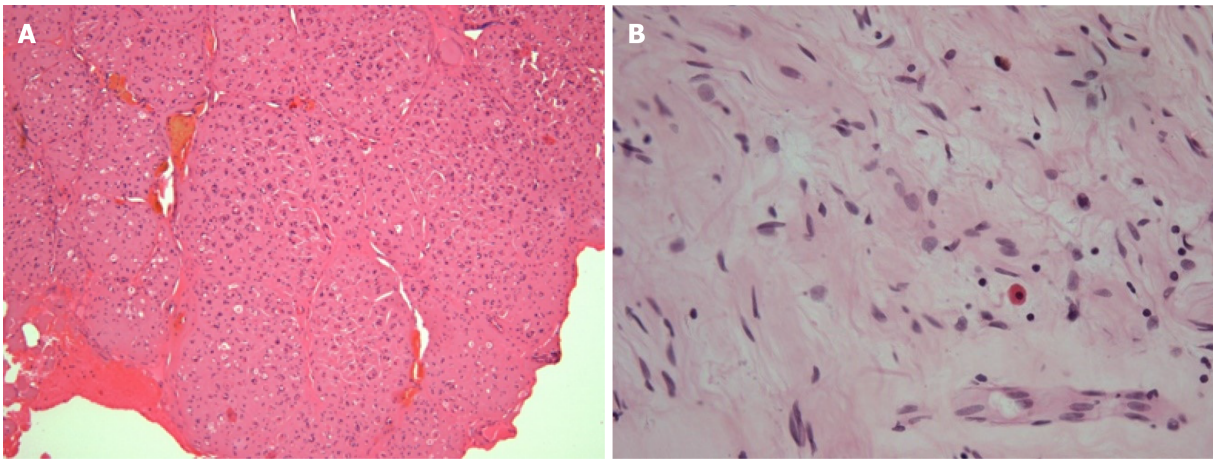
DOI: 10.12998/wjcc.v10.i14.4519 Copyright ©The Author(s) 2022.

Figure 2 Intraoperative photograph demonstrating the enlarged nerve root which emerged immediately following the duratomy.

tumor consisting of Schwann cells with wavy contours and elongated nuclei with fine dense chromatin, fibroblasts, and mast cells, a diagnosis consistent with plexiform neurofibroma (Figure 3). No deletions, duplications and translocations of NF1 gene were detected during fluorescence in situ hybridization (using specific markers for 17q11.2 area). Subsequent molecular genetic testing methods showed no point mutations characteristic for NF-1 or NF-2.

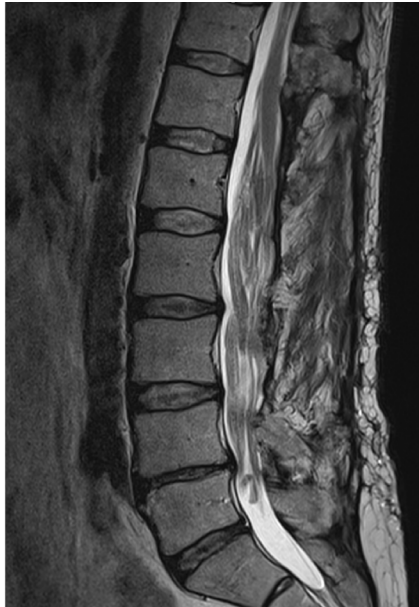During the follow-up visit 5 years later, the patient reported that he had to intermittently catheterize himself 3-4 times a day and is experiencing some problems with ambulation, faring slightly worse than shortly after the decompression. Subsequent MRI revealed a slowly growing tumorous masses at the region of cauda equina (Figure 4). No compression was noted in the conus region due to extensive duraplasty, and there were no radiological signs of malignant transformation observed.

About 3 years later, the patient presented again for the follow-up with complaints of a significant worsening in motor function and pain in lower back which sometimes radiates to lower extremities, especially during physical activity. Neurological examination was significant for neurogenic claudication with a claudicating distance of 50 meters. Consequent MRI revealed a markedly enlarged tumorous masses occupying the majority of the vertebral canal with a central canal stenosis at L3-4 Level, mainly due to hypertrophy of facet joints and ligamenta flava (Figure 5).



DOI: 10.12998/wjcc.v10.i14.4519 Copyright ©The Author(s) 2022.

Figure 3 The histological appearance of the pathological specimen, final diagnosis was consistent with plexiform neurofibroma. A: 10 ×-magnified hematoxylin-eosin staining (H&E) micrograph: note the preserved gross architecture of the nerve and coagulated resection margin; B: 40 ×-magnified H&E micrograph. Appearance of hypocellular tumor consisting of Schwann cells with wavy contours and elongated nuclei with fine dense chromatin, fibroblasts, and mast cells. No signs of atypia were observed.

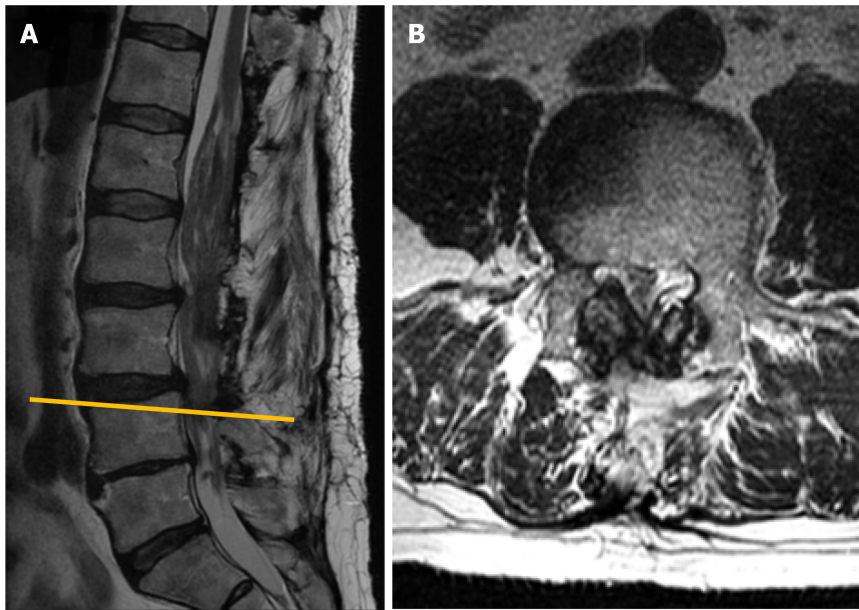


DOI: 10.12998/wjcc.v10.i14.4519 Copyright ©The Author(s) 2022.

Figure 4 Subsequent magnetic resonance imaging (T2-weighted imaging sequence) control performed in 2015, midsagittal plane. Note the slight increase in tumor mass over the 5 years following the initial surgery. Neoplastic expansion is accommodated by bony decompression and duraplasty.

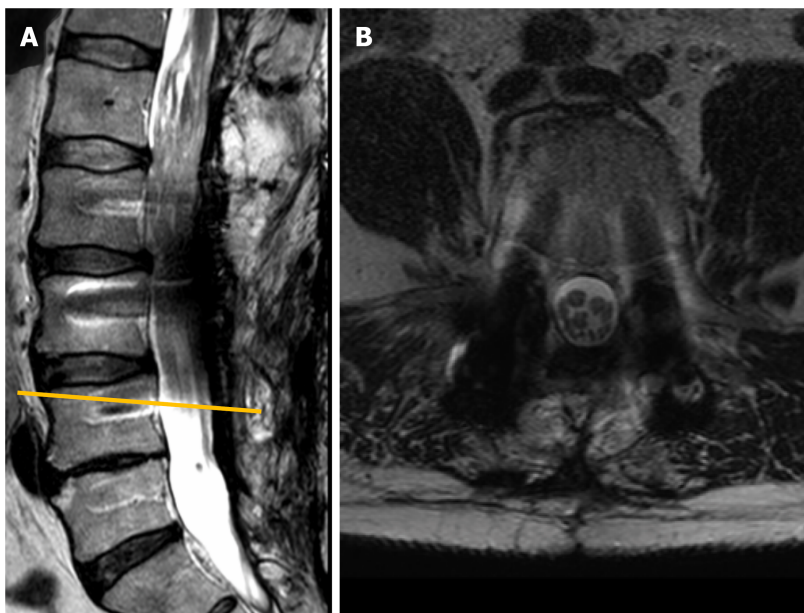
Given the marked progression of symptoms and a radiological evidence of segmental stenosis, an operative treatment was proposed for the patient. Initially, patient decided to delay the intervention and wait, but neurological condition continued to worsen and 2 mo later he agreed to comply with the surgical management option. Patient underwent a L4-L5 Laminectomy with a caudal extension of previous duraplasty and L2-L5 transpedicular fixation (Figure 6). Hypertrophied ligamenta flava, facet joints, and visible adhesions were maximally removed from the spinal canal to accommodate the thecal sac. The post-operative period was uneventful, and patient's pre-operative symptoms in terms of ambulation and pain improved dramatically following the operation. However, the problem of urinary retention remained unaffected, without the significant changes observed between the pre-operative and post-operative status.

During the most recent follow-up 18 mo after the second operation, the patient reported an improved quality of life, minor pain in the projection of lumbar spine, and persistence of minor lower extremities weakness with a similar degree of urinary dysfunction as prior the operation.



DOI: 10.12998/wjcc.v10.i14.4519 Copyright ©The Author(s) 2022.

Figure 5 Magnetic resonance imaging (T2-weighted imaging sequence) performed in 2018. A: Sagittal plane. Note markedly enlarged tumorous masses occupying the majority of the spinal canal, with a most significant stenosis at L3-L4 segment; B: Axial plane at L4 vertebral body level. Instability-induced ligamenta flava and facet joints (not seen in the section) hypertrophy, resulting in lumbar spinal stenosis at L3-L4 Level.



DOI: 10.12998/wjcc.v10.i14.4519 Copyright ©The Author(s) 2022.

Figure 6 The magnetic resonance imaging (T2-weighted imaging sequence) performed in 2020 following the second surgery involving L4-L5 Laminectomy and L2-L5 transpedicular fixation. A: Sagittal plane. Position of titanium screws following the transpedicular fixation. Titanium-induced artefacts prevent from reliable evaluation of the spinal canal and its contents; B: Axial plane at L3-L4 segment level. Note the additional space available in the central canal following the extended decompression.

DISCUSSION

Plexiform neurofibromas of the cauda equina region are extremely rare tumors. To our knowledge, only seven cases have been reported to the date[5-11]. The main clinical features of previous cases are summarized in the table (Table 1). These tumors originate from various cellular elements comprising the nerve roots (*i.e.*, axons, fibroblasts, Schwann cells)[5]. About 10% of plexiform neurofibromas eventually become malignant, and lesions in locations other than cauda equina are typically associated with NF-1 [2,4]. Only in one case of CENF a diagnosis of NF was made, but surprisingly NF-2 was the genetic syndrome reported[8]. Our case demonstrated no association with NF.

Table 1 The main characteristics of previously published cauda equina plexiform neurofibroma cases

Patient	Localization	Complaints	Medical history	Treatment and outcome
44-year-old male [5]	L3-L4	Exacerbation of chronic lower back pain and bilateral leg pain	None of the stigmata of neurofibromatosis	Surgical treatment: laminectomy, resection of the tumor
59-year-old male [6]	N/A	Progressive weakness in the lower limbs that began in infancy	Long-term follow-up presenting as peroneal muscle atrophy. His parents were first cousins	Died before the surgery because of respiratory insufficiency. Presence of ectopic motor neurons
65-year-old male [7]	L3-L4	Continuous severe lower back pain radiating into both L5 segments for several months	Suffered 20 years from pain and hypesthesia in the lumbar region and both legs. Slowly progressive atrophy of the crural muscles for 10 years	Surgical treatment: complete laminectomy of L3 through L4. Complete recovery from pain and gradual improvement in neurological signs
20-year-old male [8]	L1-5, S1-3	Right-sided foot drop, gait abnormality, bladder dysfunction	NF-2 positive, bilateral schwannomas, peripheral nerve involvement	Surgical treatment
28-year-old male [9]	L4-L5	Low back pain and bilateral radicular pain of lower extremities for the preceding 5 years	Unremarkable medical history. None of the stigmata of NF	Surgical treatment. Metaplastic ossification of the lesion. The patient was symptom-free within the first year after the surgery, when he again developed lower back pain
56-year-old male [10]	L1-L2	Urinary retention and saddle anesthesia	None of the stigmata of neurofibromatosis. After an episode of poliomyelitis at the age of 10 had muscle atrophy, severe motor disturbance, and mild sensory disturbance of the left leg	After surgery returned to his previous condition
4-year-old boy [11]	L3- sacrum	8-month history of severe lower back pain that radiated bilaterally into the L4-5 distribution. The results of a neurological examination were normal	No family history of NF. Incidental thoracic-level dermal sinus	Surgical treatment: spinous processes and laminae were exposed from L2 to L5, en bloc laminectomy and laminoplasty. The dissection of the tumor was abandoned to avoid neurological compromise. After the operation, the patient still experienced significant pain, so radiotherapy was administered to control the tumour and relieve his pain

NF: neurofibromatosis.

Previously published cases showed various combinations of progressive symptoms, the most common being the lumbar and lower extremities pain for prolonged periods of time before a clinical condition worsened and advanced to polyneuropathy. Although the probability of neoplastic process in such patients remains low, we would advocate for a more comprehensive investigation in a form of neuroimaging, especially if patient reports a prolonged history of gradually worsening complaints. Given the complex differential diagnosis process surrounding polyneuropathies, a low threshold for radiological assessment would minimize the likelihood of delayed diagnosis and treatment not only in cases of CENF, but also other slowly growing lesions.

The topic regarding an optimal management strategy and the extent of the surgery remains somewhat controversial, as various operative options could be supported by reasonable arguments. On the more conservative end of the spectrum, the practice of open biopsy together with targeted decompression and duraplasty could be sufficient in selected cases. Anyway, we decided to pursue a complete resection of the most enlarged neural root due to the fact that intraoperative monitoring showed it as silent and achieving adequate decompression was highly unlikely without the removal of the mass. The combination of Th12-L3 Laminectomy and duraplasty together with a resection of prevailing pathological nerve root allowed us to attain a satisfactory degree of decompression, but this came at the expense of permanent urinary retention as a complication. However, lack of primary spinal fixation resulted in some degree of post-operative instability one segment below the most caudal laminectomy site. Over the prolonged period of time (in our case 8 years), this facilitated the evolution of compensatory hypertrophy of facet joints and ligamenta flava, culminating in the spinal canal stenosis at L3-L4 Level. Combination of instability-induced stenosis and slowly but steadily growing CENF creates a recipe for disaster and will eventually result in the demand for an additional neurosurgical input. Therefore, we would recommend leaning right towards the more aggressive pole in terms of operative management – performing wide posterior decompression, adequate duraplasty, and primary spinal fixation in our opinion poses the best possibility to yield sustained symptomatic relief in the long-term and will likely decrease the necessity for additional interventions in the future. However, the sacrifice of neural elements should be discouraged regardless of intra-operatively recorded evoked potentials data, as the risk of complications will likely exceed potential benefits.

Redundant nerve root syndrome is another perplexing condition which requires pathological assessment in order to differentiate from CENF. The syndrome has analogous clinical and radiological picture as it manifests with thickened, large, tortuous, and elongated nerve roots in the area of cauda equina. Although it is believed that mechanical trapping at the level of lumbar spinal stenosis is the mechanism of pathogenesis, the clinical relevance of the syndrome remains a matter of debate[12,13]. Some authors suggest that at least a part of the previously described cases of redundant nerve root syndrome could actually be misdiagnosed plexiform neurofibromas and vice versa[14]. Given the similar clinical, radiological, and gross visual appearance, emphasis should be placed on the importance of histopathological evaluation in every case of suspected redundant nerve root syndrome, as at least part of these lesions could turn out neoplastic in origin.

CONCLUSION

Cauda equina is an extremely rare location for plexiform neurofibromas to manifest. This case report illustrates complicated diagnostic process as clinical presentation may mimic other polyneuropathies, and challenges associated with management of such individuals. We would strongly recommend a generous posterior decompression with duraplasty and primary spinal fixation in order to achieve the optimal long-term results. Tumor resection, even in the electroneurographically silent roots, should be discouraged.

FOOTNOTES

Author contributions: Chomanskis Z, Cepkus S and Rocka S were the patient's neurosurgeons, reviewed the literature and contributed to manuscript drafting; Chomanskis Z followed the patient; Jusky R and Dulko J reviewed the literature, contributed to manuscript drafting and edition; Hendrixson V, Ruksenas O, Chomanskis Z were responsible for the revision of the manuscript for important intellectual content; all authors issued final approval for the version to be submitted.

Informed consent statement: Informed written consent was obtained from the patient for publication of this report and any accompanying images.

Conflict-of-interest statement: The authors declare that they have no conflict of interest.

CARE Checklist (2016) statement: The authors have read the CARE Checklist (2016), and the manuscript was prepared and revised according to the CARE Checklist (2016).

Open-Access: This article is an open-access article that was selected by an in-house editor and fully peer-reviewed by external reviewers. It is distributed in accordance with the Creative Commons Attribution NonCommercial (CC BY-NC 4.0) license, which permits others to distribute, remix, adapt, build upon this work non-commercially, and license their derivative works on different terms, provided the original work is properly cited and the use is non-commercial. See: <https://creativecommons.org/licenses/by-nc/4.0/>

Country/Territory of origin: Lithuania

ORCID number: Zilvinas Chomanskis 0000-0002-0381-0346; Raimondas Jusky 0000-0003-4303-3542; Saulius Cepkus 0000-0003-2674-4975; Justyna Dulko 0000-0003-3409-3527; Vaiva Hendrixson 0000-0003-2585-3782; Osvaldas Ruksenas 0000-0002-4177-9351; Saulius Rocka 0000-0002-9715-641X.

S-Editor: Chang KL

L-Editor: A

P-Editor: Chang KL

REFERENCES

- 1 **Louis DN**, Perry A, Reifenberger G, von Deimling A, Figarella-Branger D, Cavenee WK, Ohgaki H, Wiestler OD, Kleihues P, Ellison DW. The 2016 World Health Organization Classification of Tumors of the Central Nervous System: a summary. *Acta Neuropathol* 2016; **131**: 803-820 [PMID: 27157931 DOI: 10.1007/s00401-016-1545-1]
- 2 **Hirbe AC**, Gutmann DH. Neurofibromatosis type 1: a multidisciplinary approach to care. *Lancet Neurol* 2014; **13**: 834-843 [PMID: 25030515 DOI: 10.1016/S1474-4422(14)70063-8]
- 3 **Prada CE**, Rangwala FA, Martin LJ, Lovell AM, Saal HM, Schorry EK, Hopkin RJ. Pediatric plexiform neurofibromas: impact on morbidity and mortality in neurofibromatosis type 1. *J Pediatr* 2012; **160**: 461-467 [PMID: 21996156 DOI: 10.1016/j.jpeds.2011.08.051]

- 4 **Nguyen R**, Dombi E, Akshintala S, Baldwin A, Widemann BC. Characterization of spinal findings in children and adults with neurofibromatosis type 1 enrolled in a natural history study using magnetic resonance imaging. *J Neurooncol* 2015; **121**: 209-215 [PMID: 25293439 DOI: 10.1007/s11060-014-1629-5]
- 5 **Joseffer SS**, Babu RP, Kleinman G. Plexiform neurofibroma of the cauda equina: case report. *Surg Neurol* 2005; **63**: 182-4; discussion 184 [PMID: 15680670 DOI: 10.1016/j.surneu.2004.02.037]
- 6 **Berciano J**, Figols J, Combarros O, Calleja J, Pascual J, Oterino A. Plexiform neurofibroma of the cauda equina presenting as peroneal muscular atrophy. *Muscle Nerve* 1996; **19**: 250-253 [PMID: 8559180 DOI: 10.1002/(SICI)1097-4598(199602)19:2<250::AID-MUS24>3.0.CO;2-X]
- 7 **Schumacher M**, Gilsbach J, Friedrich H, Mennel HD. Plexiform neurofibroma (Rankenneurofibrom) of the cauda equina. *Neuroradiology* 1978; **15**: 221-224 [PMID: 692868 DOI: 10.1007/BF00327530]
- 8 **Kara M**, Akyüz M, Yılmaz A, Hatipoğlu C, Özçakar L. Peripheral nerve involvement in a neurofibromatosis type 2 patient with plexiform neurofibroma of the cauda equina: a sonographic vignette. *Arch Phys Med Rehabil* 2011; **92**: 1511-1514 [PMID: 21878222 DOI: 10.1016/j.apmr.2011.04.011]
- 9 **Azarpira N**, Derakhshan N, Esfahani MH. Plexiform Neurofibroma of the Cauda Equina With Ectopic Bone Formation. *Neurosurg Q* 2015; **25**: 97-99 [DOI: 10.1097/WNQ.0b013e3182a2fe01]
- 10 **Simou N**, Zioga A, Zygouris A, Pahatouridis D, Charalabopoulos K, Batistatou A. Plexiform neurofibroma of the cauda equina: a case report and review of the literature. *Int J Surg Pathol* 2008; **16**: 78-80 [PMID: 18203792 DOI: 10.1177/1066896907304521]
- 11 **Nadkarni TD**, Rekate HL, Coons SW. Plexiform neurofibroma of the cauda equina. Case report. *J Neurosurg* 1999; **91**: 112-115 [PMID: 10419355 DOI: 10.3171/spi.1999.91.1.0112]
- 12 **Poureisa M**, Daghighi MH, Eftekhari P, Bookani KR, Fouladi DF. Redundant nerve roots of the cauda equina in lumbar spinal canal stenosis, an MR study on 500 cases. *Eur Spine J* 2015; **24**: 2315-2320 [PMID: 26071946 DOI: 10.1007/s00586-015-4059-y]
- 13 **Nogueira-Barbosa MH**, Savarese LG, Herrero CFP da S, et al. Redundant nerve roots of the cauda equina: review of the literature. *Radiol Bras* 2012; **45**: 155-159 [DOI: 10.1590/S0100-39842012000300007]
- 14 **Hakan T**, Celikoğlu E, Aydoseli A, Demir K. The redundant nerve root syndrome of the Cauda equina. *Turk Neurosurg* 2008; **18**: 204-206 [PMID: 18597240]



Published by **Baishideng Publishing Group Inc**
7041 Koll Center Parkway, Suite 160, Pleasanton, CA 94566, USA
Telephone: +1-925-3991568
E-mail: bpgoffice@wjgnet.com
Help Desk: <https://www.f6publishing.com/helpdesk>
<https://www.wjgnet.com>

