

Cerebellar Ataxia and Peripheral Neuropathy in a Family With *PNPLA8*-Associated Disease

Birute Burnyte, MD, PhD, Ramune Vilimiene, MD, Kristina Grigalioniene, MSc, Irina Adomaitiene, MD, and Algirdas Utkus, MD, PhD

Correspondence

Dr. Burnyte
birute.burnyte@santa.lt

Neurol Genet 2023;9:e200068. doi:10.1212/NXG.000000000200068

Abstract

Objectives

To describe clinical and genetic findings in 2 siblings with slowly progressive ataxia.

Methods

We studied 2 adult siblings through detailed physical and instrumental examinations. Whole-exome sequencing was used to identify an underlying genetic cause.

Results

Both siblings presented with adolescence-onset ataxia, progressive sensorimotor polyneuropathy, and preserved cognition over time. The onset of symptoms was between 10 and 14 years of age. A brain MRI demonstrated mild cerebellar atrophy in the older brother at age 45 years. Exome sequencing revealed compound heterozygous loss-of-function variants c.2269del (p.(Thr757GlnfsTer10)) and c.2275_2276del (p.(Leu759AlafsTer4)) in *PNPLA8*. The novel variant c.2269del results in frameshift with a premature stop codon p.(Thr757GlnfsTer10) and loss of normal enzyme function.

Discussion

Our findings support the theory that biallelic loss-of-function *PNPLA8* variants are involved in neurodegenerative mitochondrial disease. Compared with patients previously described, these patients' phenotype may be interpreted as a milder phenotype associated with a slight progression of ataxia throughout adulthood.

From the Institute of Biomedical Sciences (B.B., K.G., A.U.), Faculty of Medicine, Vilnius University, Vilnius, Lithuania; Institute of Clinical Medicine (R.V.), Faculty of Medicine, Vilnius University, Vilnius, Lithuania; and Vilnius University Hospital Santaros Klinikos (I.A.), Vilnius, Lithuania.

Funding information and disclosures are provided at the end of the article. Full disclosure form information provided by the authors is available with the full text of this article at [Neurology.org/NG](https://neurology.org/NG).

This is an open access article distributed under the terms of the Creative Commons Attribution-NonCommercial-NoDerivatives License 4.0 (CC BY-NC-ND), which permits downloading and sharing the work provided it is properly cited. The work cannot be changed in any way or used commercially without permission from the journal.

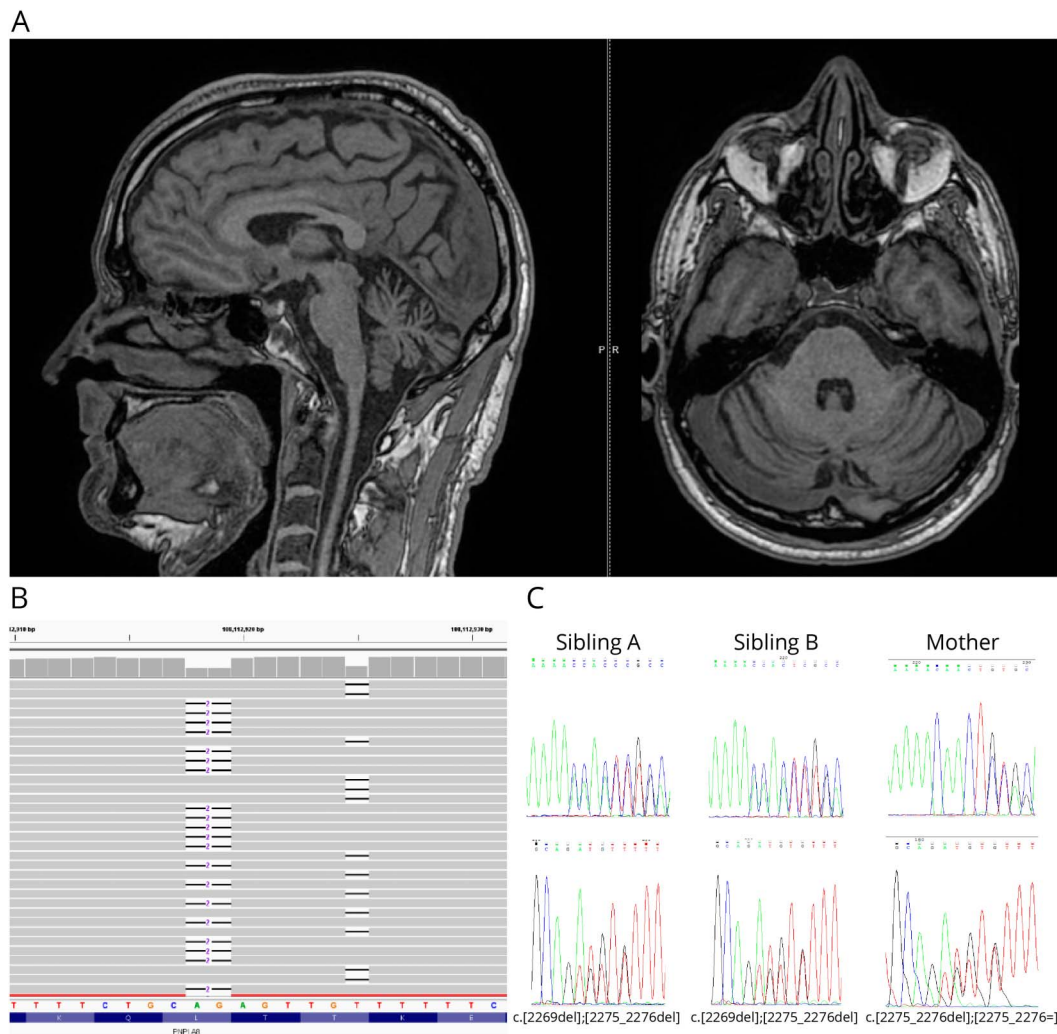
PNPLA8 is a gene that encodes a mitochondrial membrane-associated calcium-independent phospholipase A2 γ , which in general maintains the lipid homeostasis of mitochondria and peroxisomes.¹ Biallelic loss-of-function *PNPLA8* variants have very recently been associated with a mitochondrial neurodegenerative disease characterized by microcephaly, hypotonia, weakness, epilepsy, global developmental delay, poor weight gain, and lactic acidosis.²⁻⁴ We identified a new variant in *PNPLA8* and present clinical findings that help to expand the phenotype and genotype spectrum of this rare disease.

Case Presentation

Sibling A is currently a 49-year-old man. His first symptoms occurred at the age of 14 years when he developed weakness and distal muscle atrophy of his lower limbs. These symptoms were accompanied by ataxia and gait disturbance, which were

more pronounced after psychological stress. Walking difficulties slowly worsened over time. He has been unable to walk without assistance since the age of 17 years. At the age of 30 years, he had marked axial ataxia. Then, an evaluation of muscle strength revealed tetraparesis, decreased muscle tone, and muscle wasting, which was more prominent in the calves and feet. Muscle strength of the upper limbs was 4/5 (Medical Research Council) and that of the lower limbs was 3/5. Tendon reflexes were absent in the lower limbs. Sibling A presented with prominent deformities of the feet. The Babinski sign was positive on both sides. Heel-to-shin and finger-to-nose tests revealed marked dysmetria, which was more pronounced in the lower limbs. He reported mild symmetric length-dependent hypoesthesia in the lower limbs. There was no speech, visual, or cognitive function impairment. The laboratory evaluation was unremarkable. Nerve conduction studies showed sensorimotor axonal polyneuropathy. Sibling A became nonambulant at the age

Figure Brain MRI and Genetic Features



(A) Brain MRI of Sibling A T1-weighted images show moderate diffuse cerebellar volume loss, enlarged interfolial spaces, normal cerebral hemispheres. (B) IGV view of WES analysis of Sibling A showing the compound heterozygosity of c.2269del and c.2275_2276del variants in exon 11 of *PNPLA8*. (C) Sequence electropherograms (forward and reverse) showing the identified *PNPLA8* variants in both siblings and the heterozygous c.2275_2276del in their mother.

Table Summary of *PNPLA8* Cases Published So Far in Literature

	This study		Shukla et al. ³			
	Sibling A	Sibling B	Saunders et al. ²	Patient 1	Patient 2	Masih et al. ⁴
cDNA variant	c.2269del/c.2275_2276del	c.2269del/c.2275_2276del	c.334_337delAATT/c.1975_1976delAG	c.517G>T	c.419C>A/c.2275_2276delCT	c.1874A>G
Protein variant	p.Thr757Glnfs*10/p.Leu759Alafs*4	p.Thr757Glnfs*10/p.Leu759Alafs*4	p.Asn112Hisfs*29/p.Leu659Alafs*4	p.Glu173*	p.Ser140*/p.Leu759Alafs*4	(p.His625Arg)
Zygosity	Com Het	Com Het	Com Het	Hom	Com Het	Hom
Age (in report), sex	49 y, male	21 y, female	7 y, female	Newborn, female	15 y, female	5 mo, female
Age at onset	Adolescence	Adolescence	2 y	Prenatal	13 mo	Prenatal
Initial symptoms	Slowly progressive cerebellar ataxia, distal muscle weakness, and atrophy	Slowly progressive cerebellar ataxia, distal muscle weakness, and atrophy	Toe-walking, proximal muscle weakness, and dysarthria	Congenital microcephaly, spasticity, and seizures	Neuroregression, multiple episodes of epilepsy partialis continua, focal seizures, progressive weakness, and involuntary movements	Congenital microcephaly, intractable seizures and generalized hypertonias, and global developmental delay
Dysarthria	Yes (mild)	Yes (mild)	Yes	NA	NA	Nonverbal
Ataxia	Yes	Yes	NA	NA	NA	NA
Spasticity	No	No	Yes	Yes	Yes	Yes
Cognitive dysfunction	No	No	Yes	NA	Yes	NA
Brain MRI	Mild cerebellar atrophy	NA	Subtle signs of delayed myelination	Microcephaly with simplified gyral pattern, hypoplasia of corpus callosum, prominent cisterna magna with hypoplastic cerebellum, and brainstem atrophy	Cortical volume loss in the cerebellum, brainstem, bilateral parietal and occipital lobes, and corpus callosum thinning	Severe cerebral atrophy, hypoplasia of cerebellum and pons, fourth ventricular communication with cisterna magna
Lactic acidosis	No	No	Yes	NA	Yes	NA

Abbreviations: Com Het = compound heterozygote; Hom = homozygote.

of 44 years. A neurologic examination at the age of 45 years showed mild dysarthria and horizontal nystagmus. He was not able to maintain an upright stance without constant support. Ataxia, dysmetria, and limb muscle wasting had progressed. Mini-Mental State Examination scores were 30/30. Four years later, his Scale for the Assessment and Rating of Ataxia score was 26 (range 0–40 points). An MRI of the brain demonstrated mild cerebellar atrophy (Figure 1A).

Sibling B developed difficulty in walking and weakness in both lower limbs at the age of 14 years. A neurologic examination at the age of 21 years showed muscle atrophy in the lower parts of the upper and lower limbs. Tendon reflexes were absent in the lower limbs. The Babinski sign was observed on both sides. Coordination testing revealed severe axial ataxia and appendicular dysmetria, which was more pronounced in the lower limbs. She was unable to maintain an upright posture. Cranial nerve examination and cognitive evaluation were normal. A nerve conduction study showed axonal sensorimotor polyneuropathy in the lower limbs. Sensory nerves in both upper limbs were slightly affected too. EMG revealed sparse abnormal spontaneous activity in the distal muscles of the lower limbs without myopathic changes.

The study was approved by the Vilnius Regional Biomedical Research Ethics Committee of Lithuania. All patients provided written informed consent.

Whole-exome sequencing led to the identification of the novel heterozygous deletion c.2269del (p.(Thr757Glnfs*10)) and previously reported c.2275_2276del (p.(Leu759Alafs*4)) variant in *PNPLA8* (RefSeq: NM_001256007.3). The novel *PNPLA8* variant c.2269del causes a frameshift starting with codon threonine 757, changes this amino acid to a glutamine residue, and creates a premature termination codon at position 10 of the new reading frame denoted p.(Thr757Glnfs*10). According to ACMG Guidelines, the novel deletion c.2269del is pathogenic (evidence PVS1, PM2, and PM3).⁵ This variant is not reported in the ExAC, 1000G, or gnomAD databases. The previously described c.2275_2276del variant was maternally inherited. Unfortunately, the paternal DNA sample could not be obtained for segregation analysis, but results of whole-exome sequencing and Sanger sequencing allowed us to ascertain that both changes were on different alleles (*in trans*) (Figure 1, B and C). The presence of these variants was confirmed in the affected sister by Sanger sequencing.

Discussion

This appears to be the first report of a pathogenic variant in *PNPLA8* leading to an unusual phenotype. The clinical spectrum of the siblings described in this study differs with those previously reported, including onset in adolescence. Both patients manifest a unique course of cerebellar ataxia and peripheral neuropathy with a remarkable advance in their teens but only a slight progression throughout adulthood.

Remarkably, both patients were ambulant until their fifth decade. Ataxia is a common manifestation of mitochondrial disease usually associated with other neurologic and multi-systemic symptoms.⁶ Both patients avoided a decline in cognitive function and typical systemic manifestations including visual, auditory, cardiac, and liver dysfunctions. At least 6 pathogenic or likely pathogenic variants in *PNPLA8* have been identified to date in ClinVar.⁷ The clinical and genetic data of the described patients in this study and a literature overview of the reported patients are summarized in Table.

Of interest, c.2275_2276del has been reported in a compound heterozygous state with other variant leading to protein truncation and resulting in severe neurodegeneration manifesting in early childhood.³ In our study, the compound heterozygous *PNPLA8* genotype for the c.2275_2276del variant and the novel frameshift variant c.2269del resulted in a less severe neurologic phenotype. Both protein-truncating variants were identified in the last coding exon of *PNPLA8* gene, suggesting that such transcripts may escape nonsense-mediated decay and possibly result in preserved partial enzyme activity and less severe clinical manifestation. Other case reports, particularly of adults, are needed to accurately define the clinical spectrum and the course of *PNPLA8*-associated disease and to characterize the genotype and phenotype in more detail.

Study Funding

The authors report no targeted funding.

Disclosure

The authors report no relevant disclosures. Full disclosure form information provided by the authors is available with the full text of this article at [Neurology.org/NG](https://www.neurology.org/NG).

Publication History

Received by *Neurology: Genetics* September 14, 2022. Accepted in final form February 13, 2023. Submitted and externally peer reviewed. The handling editor was Editor Stefan M. Pulst, MD, Dr med, FAAN.

Appendix Authors

Name	Location	Contribution
Birute Burnyte, MD, PhD	Institute of Biomedical Sciences, Faculty of Medicine, Vilnius University, Vilnius, Lithuania	Drafting/revision of the article for content, including medical writing for content; major role in the acquisition of data; study concept or design; and analysis or interpretation of data
Ramune Vilimiene, MD	Institute of Clinical Medicine, Faculty of Medicine, Vilnius University, Vilnius, Lithuania	Major role in the acquisition of data; analysis or interpretation of data
Kristina Grigalioniene, MSc	Institute of Biomedical Sciences, Faculty of Medicine, Vilnius University, Vilnius, Lithuania	Analysis or interpretation of data

Appendix (continued)

Name	Location	Contribution
Irina Adomaitiene, MD	Vilnius University Hospital Santaros Klinikos, Vilnius, Lithuania	Analysis or interpretation of data
Algirdas Utkus, MD, PhD	Institute of Biomedical Sciences, Faculty of Medicine, Vilnius University, Vilnius, Lithuania	Drafting/revision of the article for content, including medical writing for content

References

1. Hara S, Yoda E, Sasaki Y, Nakatani Y, Kuwata H. Calcium-independent phospholipase A2 γ (iPLA2 γ) and its roles in cellular functions and diseases. *Biochim Biophys Acta Mol Cell Biol Lipids*. 2019;1864(6):861-868.
2. Saunders CJ, Moon SH, Liu X, et al. Loss of function variants in human PNPLA8 encoding calcium-independent phospholipase A2 γ recapitulate the mitochondriopathy of the homologous null mouse. *Hum Mutat*. 2015;36(3):301-306.
3. Shukla A, Saneto RP, Hebbar M, Mirzaa G, Girisha KM. A neurodegenerative mitochondrial disease phenotype due to biallelic loss-of-function variants in PNPLA8 encoding calcium-independent phospholipase A2 γ . *Am J Med Genet A*. 2018;176(5):1232-1237.
4. Masih S, Moirangthem A, Phadke SR. Homozygous missense variation in PNPLA8 causes prenatal-onset severe neurodegeneration. *Mol Syndromol*. 2021;12(3):174-178.
5. Richards S, Aziz N, Bale S, et al; ACMG Laboratory Quality Assurance Committee. Standards and guidelines for the interpretation of sequence variants: a joint consensus recommendation of the American College of Medical genetics and Genomics and the Association for Molecular pathology. *Genet Med*. 2015;17(5):405-424.
6. Bargiela D, Shanmugarajah P, Lo C, et al. Mitochondrial pathology in progressive cerebellar ataxia. *Cerebellum Ataxias*. 2015;2(1):16.
7. Landrum MJ, Lee JM, Benson M, et al. ClinVar: improving access to variant interpretations and supporting evidence. *Nucleic Acids Res*. 2018;46(D1):D1062-D1067.