

Clinical features and treatment outcomes of progressive uveal melanoma

Milda Rancelyte^{1,2,*}, Justinas Pamedys³, Ruta Grigiene⁴, Birute Brasiuniene^{1,2}

¹Clinic of Internal Diseases, Family Medicine and Oncology, Institute of Clinical Medicine, Faculty of Medicine, Vilnius University, Vilnius, Lithuania.

²Department of Medical Oncology, National Cancer Institute, Vilnius, Lithuania. ³National Center of Pathology Affiliated to Vilnius University Hospital Santaros Klinikos, Vilnius, Lithuania. ⁴Diagnostic Radiology Department, National Cancer Institute, Vilnius, Lithuania.

*Correspondence: Milda Rancelyte, Clinic of Internal Diseases, Family Medicine and Oncology, Institute of Clinical Medicine, Faculty of Medicine, Vilnius University, 08661 Vilnius, Lithuania. Email: milda.rancelyte@nvi.lt

How to cite this article: Rancelyte M, Pamedys J, Grigiene R, et al. Clinical features and treatment outcomes of progressive uveal melanoma. Arch Clin Cases. 2023;10(2):102-106. doi: 10.22551/2023.39.1002.10251

ABSTRACT

Uveal melanoma (UM) is a rare malignant tumor that differs from cutaneous melanoma in terms of pathogenesis, clinical behavior, and treatment response. Despite treatment for the primary tumor, 50% of UM patients develop metastatic disease, with the liver being the most affected organ. Furthermore, UM responds poorly to chemotherapy and immune checkpoint inhibitors. We present a clinical case of a 58-year-old female patient who was diagnosed with right eye choroidal melanoma cT2aN0M0. For the treatment of the initial tumor, the patient received stereotactic radiotherapy. However, 11 months after the initial diagnosis, the disease had progressed to the liver. The patient underwent radiofrequency ablation of liver metastases, then as the UM progressed - anti-PD-1 immunotherapy with nivolumab and ipilimumab were prescribed for the first-line palliative systemic treatment, later chemotherapy with dacarbazine (5 cycles) as the second-line systemic treatment. Based on the FoundationOne®CDx findings and an overview of clinical trials data, the MEK inhibitor trametinib was prescribed as a third-line palliative treatment. The patient died due to cancerous intoxication, with overall survival (OS) of 28 months (~2.33 years) and a progression-free survival (PFS) of 11 months (~0.92 years) since the initial diagnosis. Treatment-related adverse events could have an impact on the general health condition of the patient.

KEYWORDS: uveal melanoma; immunotherapy; targeted therapy; chemotherapy; next-generation sequencing

INTRODUCTION

Uveal melanoma (UM) is a rare malignant tumor comprising around 5-6 cases per million population per year in Europe and the USA [1,2]. This diagnosis includes melanomas of the choroid, ciliary body, and iris of the eye. It is more prevalent in Caucasians, with an average presentation age of 50 to 70 years [2]. Although some studies reported conflicting results, fair skin color and blue or gray eye color were found to be statistically significant risk factors for uveal melanoma [3] as well as choroidal nevus, dysplastic nevus syndrome, and nevus of Ota [4]. Exposure to ultraviolet (UV) radiation was suggested to increase the risk of UM in people with light iris color [5,6].

The underlying pathogenesis and clinical behavior of uveal and cutaneous melanomas are very different from one another, even though both types of melanomas arise from melanocytes [7]. In contrast to cutaneous melanomas, which typically carry a *BRAF* or *NRAS* mutation, UMs are typically caused by a mutation in either the *GNAQ* or *GNAI1* genes [2]. Moreover, according to the molecular profile, uveal melanomas can be classified into four subtypes: two subtypes of tumors

with disomy 3 and *EIF1AX* or *SF3B1* mutations are associated with low and intermediate risk, while monosomy 3 occurrence followed by *BAP-1* loss (two subtypes excluded according to the different genomic aberrations, transcriptional features) are associated with high-risk disease and poor prognosis [8]. The cytogenetic and molecular genetic features of uveal cells have been shown to have a substantial prognostic significance in UM [9].

Despite the treatment for the initial tumor, 50% of UM patients develop metastatic disease [1,10]. Because of the anatomical features (no lymphatic vessels have been detected within the uvea, but it has a rich blood supply), uveal melanoma spreading is thought to be almost entirely hematogenous, with the liver being the most likely to be affected [11]. The advanced UM is typically lethal within 1 year after the beginning of symptoms except for the cases with isolated liver metastases when surgical resection of liver lesions is possible [12,13]. Moreover, UM usually has a poor response rate to chemotherapy and immune checkpoint inhibitors [14].

CASE PRESENTATION

We present a clinical case of a 58-year-old female patient who was diagnosed with right eye choroidal melanoma

Received: March 2023; Accepted after review: June 2023;

Published: June 2023.



cT2aN0M0. At the beginning of diagnosis, an MRI scan revealed a 10 x 10 x 4.7 mm size flat mass in the lateral part of the right eyeball on the T1 post-contrast image without any signs of transbulbar growth and soft tissue invasion out of the eyeball (Figure 1). During the systemic examination, no distant metastases were detected. The patient underwent stereotactic radiotherapy (21 Gy).

Clinical and radiological follow-ups were unremarkable until the disease progression 11 months after the initial diagnosis. The abdominal MRI scan and PET CT showed a 20.9 x 16 mm liver lesion in S6 (Figure 2). Based on the multidisciplinary tumor board decision, radiofrequency ablation and core-needle biopsy of liver metastases were performed. Pathological examination identified a tumor composed of epithelioid cells with eosinophilic cytoplasm, polymorphic, hyperchromatic nuclei, and focally conspicuous nucleoli (Figure 3). Some tumor cells contained coarsely granular cytoplasmic melanin. Immunohistochemistry of the tumor was positive for Melan-A, MiTF, and SOX-10 (Figure 3); negative for PanCK (AE1/AE3). Systemic examination did not reveal other metastases. Eye examination showed no signs of local progression.

Disease progression was again confirmed 3 months after local treatment by radiofrequency ablation when an MRI scan revealed multiple metastases in the liver. A biopsy of the liver was repeated. Pathological examination confirmed metastases of melanoma in the liver; positive Melan-A, MiTF, and SOX-10; negative for PanCK (AE1/AE3). Considering the multiplicity of the metastases four cycles of anti-PD-1 immunotherapy with nivolumab (1 mg/kg) and ipilimumab

(3 mg/kg) were prescribed for the first-line palliative systemic treatment. Following the first cycle of treatment (7 days after the treatment was started), the patient developed immunotherapy-induced dermatitis of grade 1. Furthermore, increased aspartate aminotransferase and alanine aminotransferase (immunotherapy-induced hepatitis, grade 1) were observed 2 weeks after the treatment was started. Immune-related thyroiditis, grade 2, was diagnosed after the second cycle of treatment (1.5 months since the beginning of immunotherapy). Thyroid-stimulating hormone (TSH) concentration was 22.781 μ IU/ml. Therefore, treatment with levothyroxine was prescribed: starting from 37.5 mg, then increasing the dose up to the 75 mg per day. Two months after the treatment was started patient developed immunotherapy-related colitis, grade 2. Colitis management required outpatient treatment with systemic glucocorticoids: methylprednisolone 0.5 mg/kg followed by 1 mg/kg. As the clinical condition of the patient improved, immunotherapy was continued 4 weeks after the previous cycle of treatment.

Six months after the beginning of first-line systemic treatment MRI scan showed new signs of disease progression: new multiple lesions in the liver. The patient was given palliative chemotherapy with dacarbazine (5 cycles) as the second-line systemic treatment. The patient tolerated the medication well, with only minor adverse effects. Despite the treatment with dacarbazine, the disease progressed in 4 months. Next-generation sequencing was performed as a part of FoundationOne[®]CDx testing. The genetic assay revealed microsatellite stable (MSS) status, low mutational tumor burden, and gene alterations in *GNAQ*, *BAP1*, *MLH1*, and *RAD21*. Based on the FoundationOne[®]CDx findings and an overview of clinical trials data, treatment with MEK inhibitor trametinib was proposed for the third-line palliative treatment. Treatment was started with a 2 mg initial dose but the treatment was discontinued for 2 weeks due to the toxic skin reaction. Twelve days after the treatment with trametinib began, a maculopapular rash emerged on the face, chest, back and arms along with the pustules on the face, evaluated as grade 2. Treatment was resumed with a 1.5 mg daily dose. Two months later, a head MRI scan revealed a reduced in size tumor in the lateral part of the right eyeball, no brain metastases were detected, otherwise stable disease. Treatment was continued. Although according to the radiological assessment, the patient had stable disease 4 months since trametinib was started, the clinical condition of the patient deteriorated, specific treatment was discontinued, palliative care was provided to the patient. The patient developed multiple organ failure (acute kidney injury, liver dysfunction) and died with overall survival (OS) of 28 months (~2.33 years) and a progression-free survival (PFS) of 11 months (~0.92 years) since the initial diagnosis.

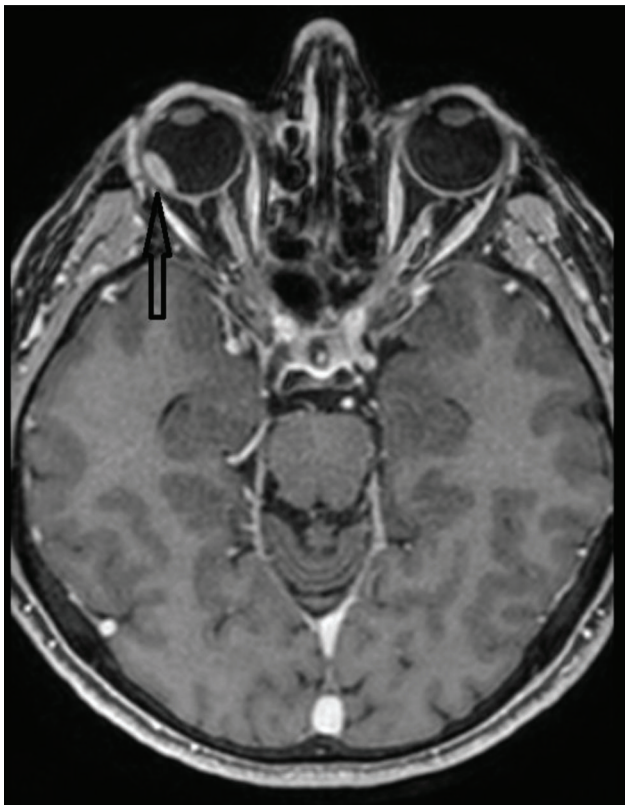


Fig. 1. The head MRI scan. Contrast-enhanced flat mass in the lateral part of the right eyeball (arrow) on the T1 post-contrast image.

DISCUSSION

In this clinical case, the patient received adequate treatment for the local disease. Unfortunately, as it is prevalent in patients with UM, the disease progressed to the liver. Radiofrequency ablation was used to treat isolated liver metastasis, but it did not prevent further cancer progression. Despite the novel treatment with immunotherapy and targeted therapy, multiple liver metastases determined the unfavorable outcome of the disease. Treatment-related adverse events could have an impact on the general health condition of the patient.

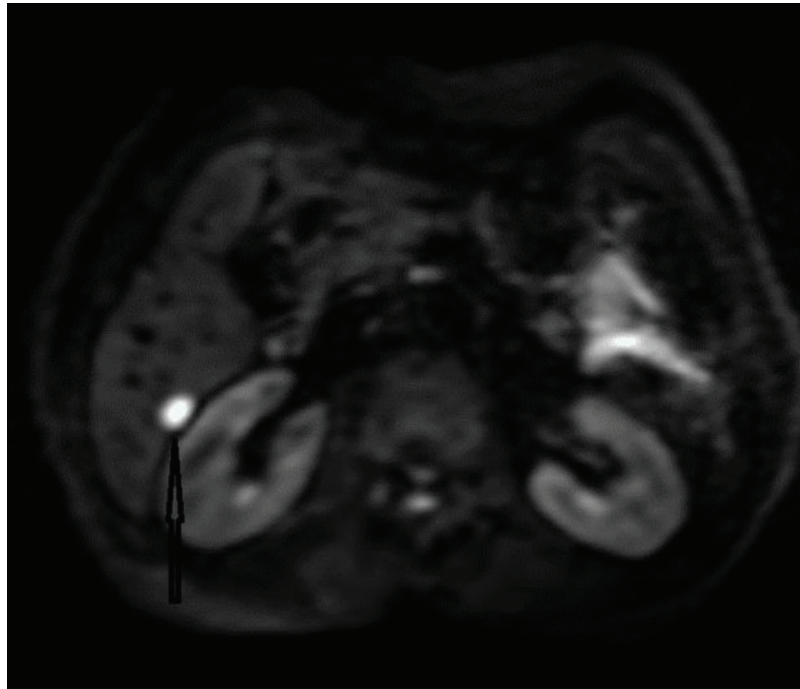


Fig. 2. The abdominal MRI. Hyperintense lesion in segment 6 of the liver (arrow) on diffusion-weighted imaging – progression.

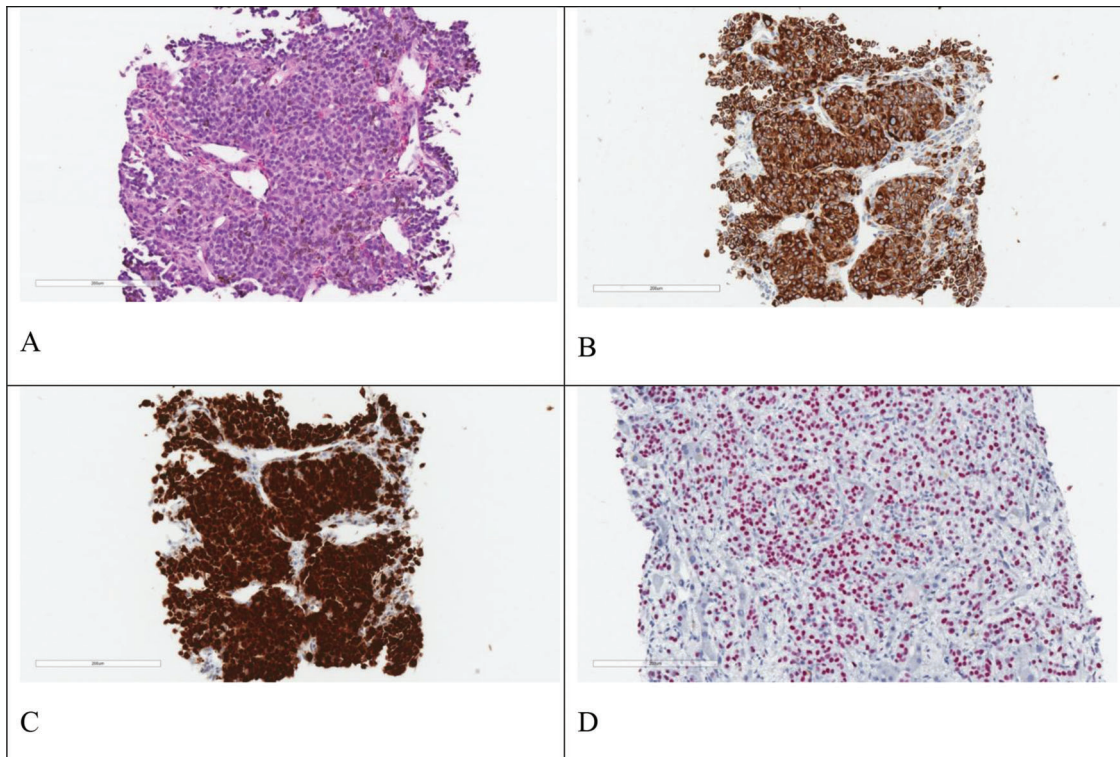


Fig. 3. Microscopical aspects of melanoma. A. The tumor is composed of epithelioid cells with eosinophilic cytoplasm, polymorphic, hyperchromatic nuclei, and focally conspicuous nucleoli (HE, x50); Immunohistochemistry tests showed tumor cells positive for: B. Melan-A (anti-Melan-A Ab, x50), C. MiTF (anti-MiTF Ab, x50) and D. SOX-10 (anti-SOX-10 Ab, x100).

According to clinical data, MSS tumors are much less sensitive to anti-PD-1 immune checkpoint drugs such as Nivolumab and Ipilimumab [15], which were used as

first-line systemic therapy in the metastatic setting before the genetical assay was performed. Our patient demonstrated 6 months of PFS while treated with Ipilimumab and

Nivolumab, which is non-inferior compared to the median PFS of 2.8 months reported in the previously conducted meta-analysis [16].

Potential immunotherapy-related adverse events (irAEs) are more likely to occur with the use of combination therapies. The frequency of irAEs was calculated in a systematic review and meta-analysis conducted in 2020 [17]. It has been shown that following antiPD-1 medication (nivolumab or pembrolizumab), hypothyroidism occurs in 7.0–8.3 percent of patients. The use of ipilimumab was linked to the development of diarrhea (all grades in 29.2% and grade ≥ 3 in 5.9%) and colitis (all grades in 8.0% and grade ≥ 3 in 5.4%). All-grade and grade ≥ 3 hepatitis was detected in 4.9 and 3.5 percent of patients after the combination of nivolumab and ipilimumab, respectively. After the administration of nivolumab and ipilimumab, the incidence of pruritus and rash of all grades and rash of grade ≥ 3 was 33.7%, 30.7%, and 3%, respectively [18]. Acute immune-related adverse events are most common in the first few weeks or months of treatment, although they can develop at any time throughout therapy.

Oncogene and tumor suppressor mutations, which are prevalent in other malignancies, are noticeably missing in UM. However, previous studies analyzing the genetics of UM have demonstrated several patterns of tumor development at the molecular level. It appears that *GNAQ* and *GNA11*-encoded mutations in the Gq alpha subunits are the beginning or initiating events that require further mutations to develop into malignancy [19]. Inactivating mutations of the *BRCA1-associated protein-1 (BAP1)* gene seem to develop later and appear to mark a molecular threshold at which the risk of metastatic disease increases dramatically [20]. It is possible for *BAP1* mutations to appear in the germline, which can result in a cancer predisposition [21]. Chromosomal abnormalities such as disomy 3 (low risk), a gain of chromosome 6p (low risk), monosomy 3 (high risk), and gain of chromosome 8q (high risk) are regarded as prognostic factors for developing a metastatic disease as well as mutations in several genes: *EIF1AX* (low risk), *SF3B1* (medium risk), and *BAP1* (high risk) [22,23]. Mutations such as this appear to be important targets for the development of personalized medicine. In this clinical case, the genetic assay of the patient has shown microsatellite stable (MSS) status, low mutational tumor burden, and gene alterations in *GNAQ*, *BAP1*, *MLH1*, and *RAD21*, which are common with uveal melanoma and are associated with high-risk disease. There are no standard treatment options or clinical trials to target alterations in *BAP1*, *MLH1*, and *RAD21* genes. However, *GNAQ* activating mutation may predict sensitivity to MEK inhibitors, therefore trametinib was given as the third-line palliative treatment in this clinical case.

Although our patient was diagnosed with local disease, according to the molecular profile it was considered to be in the high-risk clinical group; the OS of the patient was 2.33 years. Patients with uveal melanoma have a low long-term survival rate, with the risk of liver metastasis being notably significant, especially in those with high-risk genetic variants. The median OS across in the metastatic setting is around 1 year (range from 0.59 to 2.50 years) [24]. Even when radiotherapy and surgery procedures achieve satisfactory local disease management, metastatic UM treatment is challenging. In the case of UM, early detection and treatment are both crucial for a good long-term outcome. Prioritizing the quality of life is especially important when treating patients with aggressive cancer types like melanoma, when

treatment effectiveness is limited and available treatment options such as immunotherapy can cause severe adverse events. Weighing the perspectives of the patient, his relatives, and the medical team is crucial to achieving a consistent and reasonable solution. Further research is required to expand our understanding of this rare tumor type.

CONCLUSION

This clinical case demonstrated the importance of further research on uveal melanoma and its molecular pathways, therefore patient enrollment in clinical trials is critical for collecting clinical data and analyzing tumor biology to gain a better knowledge of rare malignancies and discover innovative therapeutic options.

REFERENCES

- Singh AD, Turell ME, Topham AK. Uveal melanoma: trends in incidence, treatment, and survival. *Ophthalmology*. 2011;118(9):1881-1885. PMID: 21704381. doi: 10.1016/j.ophtha.2011.01.040.
- Jager MJ, Shields CL, Cebulla CM, et al. Uveal melanoma. *Nat Rev Dis Primers*. 2020;6(1):24. doi: 10.1038/s41572-020-0158-0. Erratum in: *Nat Rev Dis Primers*. 2022;8(1):4. PMID: 32273508.
- Weis E, Shah CP, Lajous M, et al. The association between host susceptibility factors and uveal melanoma: a meta-analysis. *Arch Ophthalmol*. 2006;124(1):54-60. PMID: 16401785. doi: 10.1001/archophth.124.1.54.
- Hammer H, Oláh J, Tóth-Molnár E. Dysplastic nevi are a risk factor for uveal melanoma. *Eur J Ophthalmol*. 1996;6(4):472-474. PMID: 8997595. doi: 10.1177/112067219600600423.
- Singh AD, Rennie IG, Seregard S, et al. Sunlight exposure and pathogenesis of uveal melanoma. *Surv Ophthalmol*. 2004;49(4):419-428. PMID: 15231397. doi: 10.1016/j.survophthal.2004.04.009.
- Schmidt-Pokrzywniak A, Jöckel KH, Bornfeld N, et al. Positive interaction between light iris color and ultraviolet radiation in relation to the risk of uveal melanoma: a case-control study. *Ophthalmology*. 2009;116(2):340-348. PMID: 19091418. doi: 10.1016/j.ophtha.2008.09.040.
- Yonekawa Y, Kim IK. Epidemiology and management of uveal melanoma. *Hematol Oncol Clin North Am*. 2012;26(6):1169-1184. PMID: 23116575. doi: 10.1016/j.hoc.2012.08.004.
- Robertson AG, Shih J, Yau C, et al. Integrative Analysis Identifies Four Molecular and Clinical Subsets in Uveal Melanoma. *Cancer Cell*. 2017;32(2):204-220.e15. doi: 10.1016/j.ccell.2017.07.003. Erratum in: *Cancer Cell*. 2018 Jan 8;33(1):151. PMID: 28810145; PMCID: PMC5619925.
- Landreville S, Agapova OA, Harbour JW. Emerging insights into the molecular pathogenesis of uveal melanoma. *Future Oncol*. 2008;4(5):629-636. PMID: 18922120; PMCID: PMC2577578. doi: 10.2217/14796694.4.5.629.
- Kujala E, Mäkitie T, Kivelä T. Very long-term prognosis of patients with malignant uveal melanoma. *Invest Ophthalmol Vis Sci*. 2003;44(11):4651-4659. PMID: 14578381. doi: 10.1167/iovs.03-0538.
- Chen L. Ocular lymphatics: state-of-the-art review. *Lymphology*. 2009;42(2):66-76. PMID: 19725271; PMCID: PMC4725303.
- Xie L, Yang Y, Shen J. Efficient inhibition of uveal melanoma via ternary siRNA complexes. *Int J Pharm*. 2020;573:118894. PMID: 31765784; PMCID: PMC6954003. doi: 10.1016/j.ijpharm.2019.118894.
- Frenkel S, Nir I, Hendler K, et al. Long-term survival of uveal melanoma patients after surgery for liver metastases. *Br J Ophthalmol*. 2009;93(8):1042-1046. PMID: 19429579. doi: 10.1136/bjo.2008.153684.
- Augsburger JJ, Corrêa ZM, Shaikh AH. Effectiveness of treatments for metastatic uveal melanoma. *Am J Ophthalmol*. 2009;148(1):119-127. PMID: 19375060. doi: 10.1016/j.ajo.2009.01.023.
- Kroemer G, Galluzzi L, Zitvogel L, et al. Colorectal cancer: the first neoplasia found to be under immunosurveillance and the last one to respond to immunotherapy? *Oncoimmunology*. 2015;4(7):e1058597.

- PMID: 26140250; PMCID: PMC4485723. doi: 10.1080/2162402X.2015.1058597.
16. Khoja L, Atenafu EG, Suci S, et al. Meta-analysis in metastatic uveal melanoma to determine progression free and overall survival benchmarks: an international rare cancers initiative (IRCI) ocular melanoma study. *Ann Oncol.* 2019;30(8):1370-1380. PMID: 31150059. doi: 10.1093/annonc/mdz176.
 17. Almutairi AR, McBride A, Slack M, et al. Potential Immune-Related Adverse Events Associated With Monotherapy and Combination Therapy of Ipilimumab, Nivolumab, and Pembrolizumab for Advanced Melanoma: A Systematic Review and Meta-Analysis. *Front Oncol.* 2020;10:91. PMID: 32117745; PMCID: PMC7033582. doi: 10.3389/fonc.2020.00091.
 18. Thompson JA, Schneider BJ, Brahmer J, et al. Management of Immunotherapy-Related Toxicities, Version 1.2019. *J Natl Compr Canc Netw.* 2019;17(3):255-289. PMID: 30865922. doi: 10.6004/jnccn.2019.0013.
 19. Onken MD, Worley LA, Long MD, et al. Oncogenic mutations in GNAQ occur early in uveal melanoma. *Invest Ophthalmol Vis Sci.* 2008;49(12):5230-5234. PMID: 18719078; PMCID: PMC2634606. doi: 10.1167/iovs.08-2145.
 20. Harbour JW, Onken MD, Roberson ED, et al. Frequent mutation of BAP1 in metastasizing uveal melanomas. *Science.* 2010;330(6009):1410-1413. PMID: 21051595; PMCID: PMC3087380. doi: 10.1126/science.1194472.
 21. Masoomian B, Shields JA, Shields CL. Overview of BAP1 cancer predisposition syndrome and the relationship to uveal melanoma. *J Curr Ophthalmol.* 2018;30(2):102-109. PMID: 29988936; PMCID: PMC6034168. doi: 10.1016/j.joco.2018.02.005.
 22. Petrusch U, Martus P, Tönnies H, et al. Significance of gene expression analysis in uveal melanoma in comparison to standard risk factors for risk assessment of subsequent metastases. *Eye (Lond).* 2008;22(8):997-1007. PMID: 17384575. doi: 10.1038/sj.eye.6702779.
 23. Decatur CL, Ong E, Garg N, et al. Driver Mutations in Uveal Melanoma: Associations With Gene Expression Profile and Patient Outcomes. *JAMA Ophthalmol.* 2016;134(7):728-33. PMID: 27123562; PMCID: PMC4966162. doi: 10.1001/jamaophthalmol.2016.0903.
 24. Rantala ES, Hernberg M, Kivelä TT. Overall survival after treatment for metastatic uveal melanoma: a systematic review and meta-analysis. *Melanoma Res.* 2019;29(6):561-568. PMID: 30664106; PMCID: PMC6887637. doi: 10.1097/CMR.0000000000000575.