

De novo renal cell carcinoma in a kidney allograft treatment with percutaneous radiofrequency ablation: a case report

Inksto transplantato *de novo* karcinomos gydymas perkutanine radiodažnine abliacija: klinikinis atvejis

Marius Paškoniš^{1, 4}, Laimutis Andreika^{3, 4}, Linas Andreika⁴, Jonas Jurgaitis^{1, 4}, Feliksas Jankevičius^{2, 4}, Kęstutis Strupas^{1, 4}

¹ *Pilvo chirurgijos centras, Vilniaus universiteto ligoninė Santariškių klinikos, Santariškių g. 2, LT-08661 Vilnius, Lietuva*

² *Urologijos centras, Vilniaus universiteto ligoninė Santariškių klinikos, Santariškių g. 2, LT-08661 Vilnius, Lietuva*

³ *Urologijos skyrius, Vilniaus miesto klinikinė ligoninė, Antakalnio g. 57, LT-10207 Vilnius, Lietuva*

⁴ *Vilniaus universiteto Medicinos fakultetas, M. K. Čiurlionio g. 21, LT-03101 Vilnius, Lietuva*
El. paštas: marius.paskonis@santa.lt,

¹ *Centre of Abdominal Surgery, Vilnius University Hospital "Santariskiu klinikos", Santariškių Str. 2, LT-08661 Vilnius, Lithuania*

² *Centre of Urology, Vilnius University Hospital Santariskiu klinikos, Santariškių Str. 2, LT-08661 Vilnius, Lithuania*

³ *Department of Urology, Vilnius City Clinical Hospital, Antakalnio Str. 57, LT-10207 Vilnius, Lithuania*

⁴ *Vilnius University Faculty of Medicine, M. K. Čiurlionio Str. 21, LT-03101 Vilnius, Lithuania*
El. paštas: marius.paskonis@santa.lt,

The incidence of malignant tumors in renal allograft recipients is higher than in the general population. Kidney carcinomas represent 4.8% of the tumors in transplant patients. Only 10% of them occur in the transplanted kidney. Graft tumors can be transmitted by donors, metastases from the recipient's native organs, or *de novo* development after transplantation. The mean time to diagnosis of the tumor after transplantation is 10 years. We report the case of a 45-year old male patient with an incidental locally confined 15 mm renal cell carcinoma detected in allograft kidney's lower pole 16 years after the transplantation. The patient successfully underwent a minimally invasive procedure - percutaneous radiofrequency ablation, completely eliminating the tumor and preserving graft function with no signs of early complications. One year after the procedure, there is no evidence of oncological disease recurrence or late complications and the patient maintains an adequate graft function with no need for hemodialysis.

Key words: De novo allograft tumor, percutaneous radiofrequency ablation, renal cell carcinoma

Pastebėta, jog piktybinių navikų dažnis žmonėms, kuriems persodinti inkstai, yra didesnis nei bendrojoje populiacijoje. Inkstų karcinomos sudaro 4,8 % visų navikų, nustatomų recipientams, ir vos 10 % – transplantate. Transplantato navikai gali būti perduoti donoro, metastazės iš kitų recipiento organų arba *de novo* (naujai) vystytis po transplantacijos. *De novo* navikai transplantate nustatomi vidutiniškai 10 metų po transplantacijos. Mes aprašome klinikinį atvejį 45 metų vyro, kuriam 16 metų po inksto persodinimo atsitiktinai aptikta besimptomė neišplitusi 15 mm dydžio papilinė inksto karcinoma apatiniame transplantato poliuje. Ligonii sėkmingai atlikta minimaliai invazyvi procedūra – perkutaninė radiodažninė abliacija, kuri visiškai sunaikino naviką išsaugodama transplantato funkciją. Ankstyvųjų komplikacijų nenustatyta. Praėjus vieneriems metams po procedūros vėžinės ligos atsinaujinimo ar vėlyvųjų komplikacijų požymių nėra, išlieka adekvati transplantato funkcija be hemodializės poreikio.

Reikšminiai žodžiai: *de novo* transplantato navikas, perkutaninė radiodažninė abliacija, inkstų karcinoma.

Introduction

Kidney transplantation still remains the best treatment choice for patients with end-stage renal disease taking into account the survival and quality of life. However, it is estimated, that in about 6% of transplant recipients some kind of neoplasm will develop, mostly skin malignancies and non-Hodgkin lymphomas [1, 2]. Kidney carcinomas represent 4.8% of post-transplant cancers, as compared with 2.3% of tumors in the general population. However, among these carcinomas, only 10% occur in kidney grafts [3, 4]. Graft tumors can be transmitted by donors, metastases from the recipient's native organs, or *de novo* development after transplantation [5]. An increase in the detection of mostly incidental tumors in renal transplants is associated with the increasing use of transplants from elderly donors and long-term immunosuppression [6]. Moreover, monitoring alone (regular ultrasound screening) can enhance the number of incidental tumors detected [6, 7]. The mean time to diagnosis of the tumor after transplantation is 10 years, although, in our case, it took 16 years [7]. Radical and nephron-sparing nephrectomies have been the treatments of choice for transplant patients for a long time but percutaneous ablative therapy, which is minimally invasive procedure with lower morbidity, is now considered as a well-established therapeutic approach and taking its place in treatment algorithms [8]. Due to the rarity of allograft kidney tumors and very few articles involving treatment with percutaneous thermal ablation, our aim is to share our experience and short-term results.

Clinical case presentation

We present the case of a 45-year old male patient with medical history of arterial hypertension, gastric ul-

cers and an end-stage renal disease caused by chronic glomerulonephritis. In 1998, the patient received a kidney transplant from a live donor (his brother) in the right iliac fossa. Maintenance immunosuppressive therapy included Methylprednisolone, Azathioprine and Cyclosporine. In 2009, a routine ultrasound showed 1st grade hydronephrosis, which progressed. A computer tomography (CT) scan was carried out but no clear cause of hydronephrosis or any lesions were identified at that time. The kidney graft function was limited: glomerular filtration rate 30 (ml/min/1.73 m²), and creatinine levels stable in an 18-month period (221→198→264→222 μmol/l). In September 2014, a CT scan (without contrast since the serum creatinine level was high) detected a pyeloureteral stricture and a solid ~15 mm lesion in the transplant kidney's lower pole parenchyma. It should be noted that the lesion had no influence to the nephrostasis and was incidental. By revising the prior CT scans made in 2009, a smaller lesion in the same location that had not been reported earlier was detected. The tumor was slowly growing from <10 mm to ~15 mm in a 5 years' period. After the needle biopsy, primary results showed xanthogranulomatous pyelonephritis and nephrosclerosis. It was decided to perform pyeloplasty and ureter stenting to eliminate the cause of hydronephrosis (pyeloureteral stricture) and preserve the graft kidney function. The further treatment tactics were planned to be discussed after the final histology results. The final biopsy results confirmed the disease corresponded to papillary carcinoma (G3, grade 3 Fuhrman). Taking into consideration eligible tumor size (TNM T1a), location, graft function and available equipment, a minimally invasive procedure would have been the best choice of treatment. Thus it was proposed to carry out percutaneous radiofrequency

ablation therapy (RFA). RFA with intraoperative ultrasound targeting was performed in October 2014. Graft's lower pole ~13 mm solid tumor was destructed using two T20 (15 cm) needles, 40W power, 30 KJ energy (in 66 minutes). Prophylactic antibiotics were prescribed before and after the procedure. The patient was released from the hospital 3 days after the operation with no complications and adequate renal function. CT scan control after 2, 6 and 12 months detected no evidence of disease recurrence or late complications. The patient maintained an adequate allograft function with no need for hemodialysis.

Discussion

Transplant patients must stay on immunosuppressive therapy, therefore, they gain a higher risk of developing some kind of neoplasm. The risk of renal cell carcinoma (RCC) is two times bigger in transplant patients than in general population [3]. The incidence of *de novo* carcinoma in kidney allografts is reported to be 0.19–0.5% [8, 9]. Graft tumors can be transmitted by donors, metastases from the recipient's native organs, or *de novo* development after transplantation [5]. Penn considered kidney graft tumors detected within 2 years after the transplantation to be most likely transmitted [4]. However, the reported time between the transplantation and the development of *de novo* RCC in transplanted kidneys is ranging from 9 months to 27 years [7, 11]. Based on Tillou et al. exhaustive literature review, the mean time to diagnosis of the tumor after transplantation is 126.2 ± 69.8 months [7]. The estimated growth of these tumors is between 5 and 10 mm per year, thus identical to the tumors found in native kidneys and in patients without transplants [12]. In our case, the tumor is diagnosed 16 years after the transplantation, although, a small lesion was detected revising CT scans made in 2009. Comparing CT scans done in 2009 and 2014, the tumor size enlarged only ~1 cm in 5 years.

The diagnosis of a graft kidney malignancy is typically incidental, usually during the regular follow-up imaging. The diagnosis is made using abdominal ultrasound or a CT scan. Similar to native kidney tumors, symptomatic kidney graft tumors have a worse prognosis [13].

Cornelis et al. found that renal papillary carcinoma accounted for 85% of the histologic subtypes found in

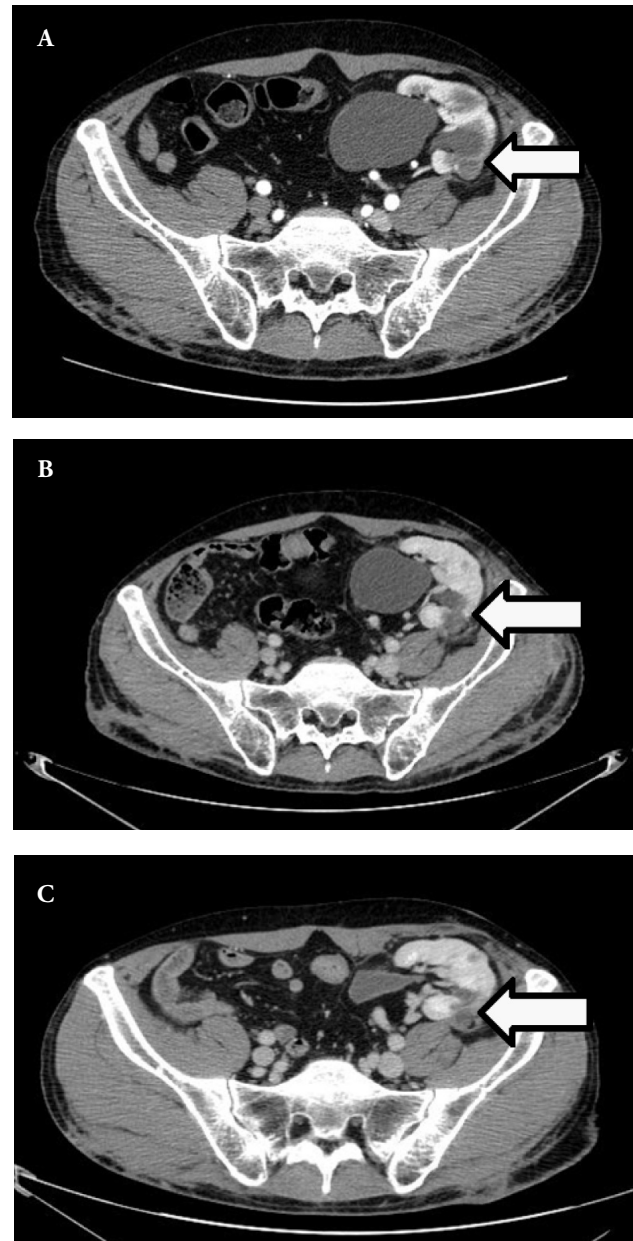


Figure 1. A – CT scan before RFA, B – CT scan 6 months after RFA, C – CT scan 12 months after RFA

transplant patients, compared with the 10%–15% of these subtypes encountered in the general population [6, 12]. According to Gelb, this type of tumor has a better prognosis in comparison to clear cell carcinoma [14]. Papillary carcinoma represented 55.7% of the tumors in the Tillou et al. study (2012) [9], although the later systematic review revealed the most common tumor was clear cell carcinoma (46.4% versus 43.7%). Study found

an overall 79.1% of low-grade tumors (Grade 1 and 2 of Fuhrman), therefore concluded that *de novo* graft tumors seemed to be predominantly low-grade and not aggressive [7]. In our case the tumor was a high-grade (G3, grade 3 Fuhrman) confined (TNM T1a) papillary carcinoma.

Renal transplant recipients with graft RCC present a dilemma: if a conservative approach was chosen to preserve the graft, the patient would be placed at a greater risk of cancer progression due to immunosuppressant induced immune incompetence. Therefore, such tumors are approached surgically at the risk of losing the only functioning kidney. Transplantectomy is usually justified by symptomatic and >40 mm graft tumors (TNM T2 or higher) [7, 15]. Nephron sparing surgery (NSS) is recommended for graft kidney tumors ≤40 mm (TNM T1b) with an eccentric location and a good blood supply to the rest of the allograft parenchyma [9, 10, 16]. However, NSS is now recommended by the European Association of Urology guidelines for native kidney tumors >40 mm (TNM T1b) [7, 15]. NSS preserves graft functions and helps patients to avoid returning to dialysis that is associated with inferior life expectancy and quality of life. Nevertheless, NSS can appear technically difficult because it is performed in a non-naive surgical field making kidney mobilization, parenchymal resection and other manipulations complex [17].

The growth of interest in minimally invasive procedures has been triggered by finding the relation between the number of functional nephrons left after the tumor resection and patient survival [18]. Two minimally invasive techniques used in <40 mm (TNM T1a) RCC treatment are RFA and cryoablation. RFA is perfectly

suitable in such cases as it only slightly reduces the number of nephrons (RFA 11% versus NSS 35%) and does not require intraoperative ischemia that might induce associated parenchymal injury [19]. Based on Regier and Chun systematic review, the primary technical success rate of RFA in non-transplant patients ranged from 88% to 100% with the complication rate from 1% to 7%. [20]. Cornelis et al. had 100% success rate with one complication in their 24 graft RCC patient group, which resembled to other studies [6]. Therefore, it can be assumed that the results in transplant and non-transplant patients are similar. The few authors who reported their primary success rates after cryoablation found them somewhat higher compared to RFA. Moreover, the result of the ablation can be instantly visualised with ultrasound control during the intervention as a hypodense ice ball. However, there are no randomized controlled trials comparing the two techniques [20]. In the present case, the tumor in a graft kidney with limited function was successfully treated with RFA with no cancer progression after 12 months as verified by CT.

Conclusions

Percutaneous radiofrequency ablation therapy is a feasible option for patients with small (TNM T1a) kidney graft tumors or in such cases, when the patient is not eligible for surgery (surgery refusal, old age or other treated cancers). Due to minimal invasiveness, high success rate, low complication rate, low mortality and short hospital stay, percutaneous radiofrequency ablation technique is an important addition to the selection of effective treatments for locally confined renal tumors, especially in functioning allografts.

BIBLIOGRAPHY

1. Naroienejad M, Salouti R. Renal cell carcinoma in transplanted kidney. *Iran J Radiol.* 2005; 2: 3–4.
2. Kasiske BL, Snyder JJ, Gilbertson DT, Wang C. Cancer after kidney transplantation in the United States. *Am J Transpl.* 2004; 4: 905–13.
3. Penn I. Primary kidney tumors before and after renal transplantation. *Transplantation.* 1995; 59: 480–5.
4. Penn I. Occurrence of cancers in immunosuppressed organ transplant recipients. *Clin Transplant.* 1998; 147–58.
5. Banshodani M, Kawanishi H, Marubayashi S, Shinta-

ku S, Moriishi M, Shimamoto F, Tsuchiya S, Dohi K, Ohdan H. De novo renal cell carcinoma in a kidney allograft 20 years after transplant. *Case reports in transplantation*, <http://dx.doi.org/10.1155/2015/679262>.

6. Cornelis F, Buy X, Andre M, Oyen R, Bouffard-Vercelli J. De novo renal tumors arising in kidney transplants: midterm outcome after percutaneous thermal ablation. *Radiology.* 2011; 260: 900–7.

7. Tillou X, Guleryuz K, Collon S, Doerfler A. Renal cell carcinoma in functional renal graft: Toward ablative tre-

atments. *Transplant Rev* 2015. <http://dx.doi.org/10.1016/j.tre.2015.07.001>.

8. Goeman L, Joniau S, Oyen R, Van Poppel H. Percutaneous ultrasound-guided radiofrequency ablation of recurrent renal cell carcinoma in renal allograft after partial nephrectomy. *Urology*. 2006; 67: 199.
9. Tillou X, Doerfler A, Collon S, Kleinclauss F, Patard JJ et al. De novo kidney graft tumors: results from a multicentric retrospective national study. *Am J Transplant*. 2012; 12: 3308–15.
10. Barama A, St-Louis G, Nicolet V, Hadjeres R, Daloze P. Renal cell carcinoma in kidney allografts: a case series from a single center. *Am J Transplant*. 2005; 5: 3015–8.
11. Gunji Y, Sakamoto K, Yamada K, Hamaguchi K, Kashiwabara H. Successful surgical treatment of renal cell carcinoma in a transplanted kidney from a cadaveric donor: report of a case. *Surg Today*. 2001; 31: 374–7.
12. Moudoni SM, Lakmichi A, Tligui M, Rafii A, Tchala K, Haab F. Renal cell carcinoma of native kidney in renal transplant recipients. *BJU Int*. 2006; 98: 298–302.
13. Patard JJ, Leray E, Rodriguez A, Rioux-Leclercq N, Guille F, Lobel B. Correlation between symptom graduation, tumor characteristics and survival in renal cell carcinoma. *Eur Urol*. 2003; 44: 226–32.
14. Gelb AB. Renal cell carcinoma: Current prognostic factors. *UICC and AJCC. Cancer*. 1997; 80: 981–6.
15. Ljungberg B, Bensalah K, Bex A, Canfield S, Dabestani S, Hofmann F, Hora M, Kuczyk MA, Lam T, Marconi L, Merseburger AS, Mulders PFA, Powles T, Staehler M, Volpe A. European association of urology guidelines on renal cell carcinoma: 2014 Update. *Eur Urol*. 2015; 67: 913–24.
16. Aguilera Tubet C, Gutierrez Banos JL, Del Valle Schaan JI, Martin Garcia B, Ballesteros Diego R, Zubillaga Guerrero S. Multifocal renal cell carcinoma on renal allograft. *Acta Urol Esp*. 2007; 31: 553–5.
17. Li JYZ, Yong TY, Rao M, Coates PTH. Partial nephrectomy for renal cell carcinoma in an allograft kidney with limited functional reserve. *NDT Plus*. 2009; 2: 312–3.
18. Weight CJ, Larson BT, Fergany AF, Gao T, Lane BR. Nephrectomy induced chronic renal insufficiency is associated with increased risk of cardiovascular death and death from any cause in patients with localized cT1b renal masses. *J Urol*. 2010; 183: 1317–23.
19. Al-Alem I, Pillai K, Akhter J, Chua TC, Morris DL. Heat sink phenomenon of bipolar and monopolar radiofrequency ablation observed using polypropylene tubes for vessel simulation. *Surg Innov*. 2014; 21: 269–76.
20. Regier M, Chun F. Thermal ablation of renal tumors: indications, techniques and results. *Dtsch Arztebl Int*. 2015; 112: 412–8.