

Successful surgical treatment of coronary cameral fistula

Sigita Glaveckaitė¹, Matačiūnas Mindaugas², Valevičienė Nomedā², Virgilijus Tarutis¹

¹Department of Cardiovascular Diseases, Institute of Clinical Medicine, Vilnius University Faculty of Medicine, Vilnius, Lithuania

²Department of Radiology, Nuclear Medicine and Medical Physics, Institute of Biomedical Sciences, Vilnius University Faculty of Medicine, Vilnius, Lithuania

Correspondence to:

Prof. Sigita Glaveckaitė, MD, PhD,
Department of Cardiovascular
Diseases,
Institute of Clinical Medicine,
Vilnius University Faculty
of Medicine,
Santariškių st. 2, 08661, Vilnius,
Lithuania,
phone: +37 0 68 240 937,
e-mail:
sigita.glaveckaite@gmail.com

Copyright by the Author(s), 2023

DOI: 10.33963/KPa2023.0027

Received:

November 7, 2022

Accepted:

December 16, 2022

Early publication date:

January 27, 2023

Coronary artery fistula (CAF) or coronary arteriovenous fistula is a rare congenital or acquired anomaly of coronary arteries (CA) that involves an abnormal vascular communication between a CA and either a cardiac chamber (coronary-cameral fistula) or any segment of the systemic or pulmonary circulation (coronary-arteriovenous fistula), without an intervening capillary network [1].

A 42-year-old woman reporting palpitations, exertional chest pain, and dyspnea during ordinary physical exercise underwent a cardiologist consultation. Her physical examination showed a loud continuous murmur at the upper left sternal border. Electrocardiography (ECG) showed sinus rhythm, 64 bpm, Q waves in leads II, III, aVF, and signs of left ventricular (LV) hypertrophy. TTE demonstrated dilated and slightly hypertrophied LV with normal contractile function. Additionally, aneurysmatic CA changes in the left main artery (LM) and left circumflex artery (LCx) were observed. Besides the above-mentioned findings, up to 12-mm wide communication between LCx and LV chambers just under the mitral valve (MV) posterior leaflet was noticed with big shunt flow through this communication (Figure 1A, Supplementary material, Videos S1, S2).

For clarification of TTE findings, computed tomography angiography (CTA) was performed. It demonstrated normal right coronary artery (RCA) but aneurysmatic (up to 18 mm in diameter) LM and widened proximal LCx segment. The LCx middle segment was curved, and the distal LCx segment entered the LV under the posterior MV leaflet (with fistula diameter of about 10 mm) (Figure 1B, C). The diagnosis of coronary-cameral fistula was confirmed while performing invasive coronary angiography (Figure 1D). After

a multidisciplinary team decision, surgical ligation of the fistula was performed successfully. Postoperative CTA confirmed successful surgery (Figure 1E).

CAFs are uncommon CA abnormalities, accounting for 0.002% to 0.3% of the population, according to a series of studies [1]. The origin of CAFs can be any of the three major CAs and CAFs drainage sites commonly involve low-pressure structures: the right ventricle (41%), right atrium (26%), pulmonary artery (17%), coronary sinus (7%), left atrium (5%), left ventricle (3%) and superior vena cava (1%) [2].

Although most CAFs are asymptomatic, patients with larger CAFs, depending on whether the coronary steal syndrome is present and on the severity of the left-to-right shunt, have various symptoms, including mild dyspnea, fatigue, angina, congestive heart failure, pulmonary hypertension, and myocardial ischemia [3]. With a left-to-left shunt, the risk of left heart volume overload increases.

Although conventional invasive angiography historically has been considered the gold standard method for detection of CAFs, multidimensional CTA has emerged as a non-invasive and widely available alternative modality of choice [4].

Spontaneous closure of CAF is rare, thus the management strategy for patients with CAFs depends on the size of the fistula, presence of symptoms, anatomy of the fistula, the patient's age, and presence of associated cardiovascular abnormalities. According to the American College of Cardiology/American Heart Association (ACC/AHA) guidelines, percutaneous closure or surgical ligation is a class I recommendation for large fistula regardless of symptoms and for small-to-moderate-size fistula with symptoms, including

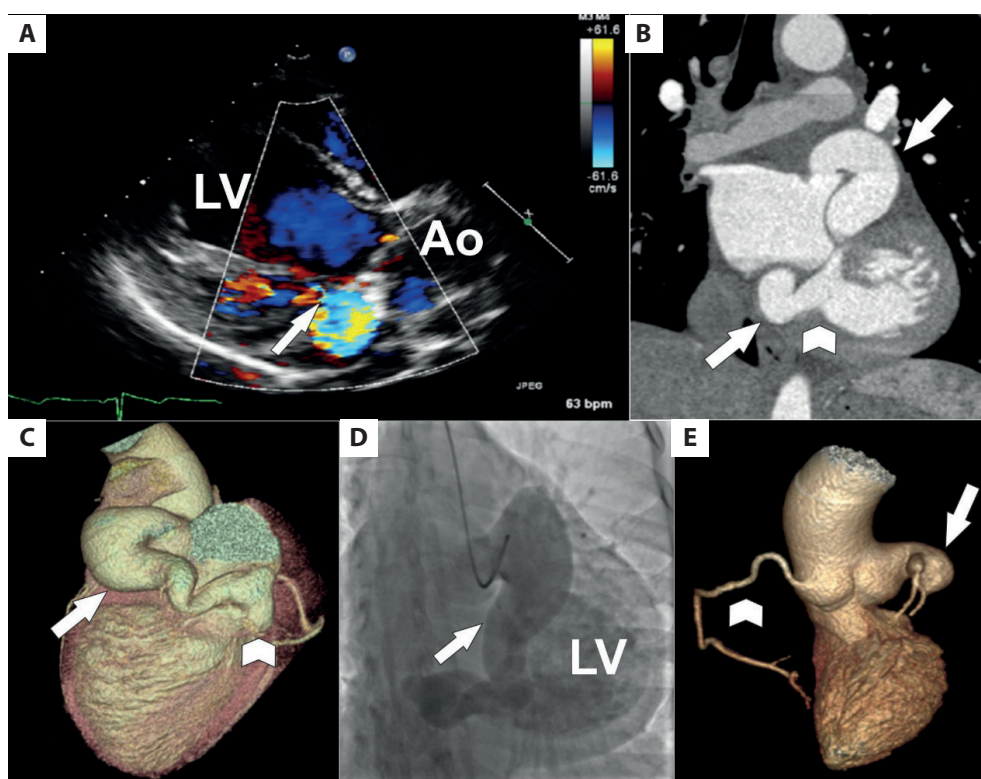


Figure 1. Clinical images of a 42-year-old woman with a left circumflex artery (LCx) to left ventricle (LV) fistula. **A.** TTE parasternal long axis view showing a hemodynamically significant shunt from the LCx to the LV chamber just under the mitral valve posterior leaflet (arrow shows shunt jet). **B.** CT angiography curved multiplanar reconstruction showing an ectatic and tortuous LCx (arrow) draining into the LV (arrowhead shows draining site). **C.** CT angiography volume-rendering reconstruction showing the ectatic and tortuous LCx (arrow) draining into the LV (arrowhead denotes draining site). **D.** Specialized LCx (arrow) invasive angiogram showing the ectatic and tortuous LCx with evidence of communication with the LV because of concomitant opacification of the LV by contrast media. **E.** CT angiography volume-rendering reconstruction (LV and ascending aorta reconstruction) showing the ligated LCx (arrow) without signs of shunting

Abbreviations: Ao, aorta; CT, computed tomography; LCx, left circumflex artery; LV, left ventricle; TTE, transthoracic echocardiography

myocardial ischemia, arrhythmia, ventricular dysfunction, ventricular enlargement, or endarteritis [5]. Regular follow-up is essential in patients with small asymptomatic CAFs and after CAF closure.

Supplementary material

Supplementary material is available at https://journals.viamedica.pl/kardiologia_polska.

Article information

Conflict of interest: None declared.

Funding: None.

Open access: This article is available in open access under Creative Commons Attribution-Non-Commercial-No Derivatives 4.0 International (CC BY-NC-ND 4.0) license, which allows downloading and sharing articles with others as long as they credit the authors and the publisher, but without permission to change them in any way or use them commercially. For commercial use, please contact the journal office at kardiologiapolska@ptkardio.pl.

REFERENCES

1. Yun G, Nam TH, Chun Eju. Coronary artery fistulas: pathophysiology, imaging findings, and management. *Radiographics*. 2018; 38(3):688–703, doi: [10.1148/rg.2018170158](https://doi.org/10.1148/rg.2018170158), indexed in Pubmed: 29601265.
2. Jha NK, Kiraly L, Shah N, et al. Congenital aneurysmal right coronary artery with a fistula to the left atrium in an adult. *J Cardiothorac Surg*. 2019; 14(1):33, doi: [10.1186/s13019-019-0854-6](https://doi.org/10.1186/s13019-019-0854-6), indexed in Pubmed: 30736865.
3. Shiga Y, Tsuchiya Y, Yahiro E, et al. Left main coronary trunk connecting into right atrium with an aneurysmal coronary artery fistula. *Int J Cardiol*. 2008; 123(2): e28–e30, doi: [10.1016/j.ijcard.2006.11.108](https://doi.org/10.1016/j.ijcard.2006.11.108), indexed in Pubmed: 17306898.
4. Junco-Vicente A, Flórez P, Suárez A, et al. Uncommon giant fistula in the circumflex coronary artery. *Kardiol Pol*. 2020; 78(7-8): 794–795, doi: [10.33963/KP.15390](https://doi.org/10.33963/KP.15390), indexed in Pubmed: 32458673.
5. Warnes CA, Williams RG, Bashore TM, et al. ACC/AHA 2008 guidelines for the management of adults with congenital heart disease: a report of the American College of Cardiology/American Heart Association Task Force on Practice Guidelines (Writing Committee to Develop Guidelines on the Management of Adults With Congenital Heart Disease). Developed in Collaboration With the American Society of Echocardiography, Heart Rhythm Society, International Society for Adult Congenital Heart Disease, Society for Cardiovascular Angiography and Interventions, and Society for Thoracic Surgeons. *J Am Coll Cardiol*. 2008; 52(23):e143–e263, doi: [10.1016/j.jacc.2008.10.001](https://doi.org/10.1016/j.jacc.2008.10.001), indexed in Pubmed: 19038677.