

CLINICAL CASES

Dent. Med. Probl. 2015, 52, 4, 512–515
DOI: 10.17219/dmp/60130

© Copyright by Wrocław Medical University and Polish Dental Society
ISSN 1644-387X

BARBARA ZAWADZKA^{B-D,F}, ALINA PŪRIENĖ^{A-F}, ARŪNAS RIMKEVIČIUS^{A-F}

Malignant Transformation of Oral Lichen Planus in Labial Location in a 23-Year-Old Woman – Case Report

Transformacja nowotworowa liszaja płaskiego zlokalizowanego na wardze u 23-letniej kobiety – opis przypadku

Institute of Odontology, Faculty of Medicine, Vilnius University, Vilnius, Lithuania

A – research concept and design; B – collection and/or assembly of data; C – data analysis and interpretation;
D – writing the article; E – critical revision of the article; F – final approval of article

Abstract

Lichen planus (LP) having a potential for malignant transformation is a rare mucocutaneous disease most frequently observed in middle-aged women than in men. LP is uncommon in young patients and the involvement of a labial site and desquamative gingivitis are also rare. LP mainly affects oral mucosa, and skin involvement is rare. Mucosal lesions are usually multiple and have a bilateral, symmetrical manifestation. Mucosal lesions frequently appear on the tongue, gingiva, and mucobuccal fold. Nearly half of the patients has multiple sites of involvement. Oral biopsy with a histopathological evaluation is necessary to validate the clinical diagnosis of LP. Malignant transformation is uncommon for young patients with a short history of LP and without the presence of other co-morbidities. The aim of the present report was to present a 23-year-old patient with an LP lesion which developed into a squamous cell carcinoma on a facial labial site. Different subject-related pathological, diagnostic and treatment aspects are discussed (*Dent. Med. Probl.* 2015, 52, 4, 512–515).

Key words: lichen planus, dysplasia, malignant transformation, young age, lip.

Słowa kluczowe: liszaj płaski, dysplazja, transformacja nowotworowa, młody wiek, warga.

Lichen planus, a rare mucocutaneous disease affecting around 0.1–4.0% of the population [1], has been associated with a cell-mediated immunological dysfunction. It commonly affects middle-aged adults and it is more frequently observed in women than in men [2]. LP mainly affects oral mucosa, and skin involvement is rare [3]. Mucosal lesions are usually multiple and have a bilateral, symmetrical manifestation. Mucosal lesions frequently appear on the tongue, gingiva, and mucobuccal fold [4]. Nearly half of the patients, 47.6%, has multiple sites of involvement [5, 6].

A labial site and gum involvement are rare. The following clinical forms of LP have been identified: papular, reticular, ulcerative, plaque and atrophic [5, 7]. Oral biopsy with a histopathological evaluation is necessary to validate the clinical

diagnosis of LP. Most importantly, LP can develop into an oral squamous cell carcinoma [8, 9]. There are several long-term prospective studies that show a malignant transformation rate of 4.0% [10, 11].

The present case report presents a case about a 23-year-old patient with an LP lesion that developed into a squamous cell carcinoma on a labial site. Different subject-related pathological, diagnostic and treatment aspects will be discussed.

Case Report

A 23-year-old female was referred in June 2004 to a dermatologist for the evaluation of a lip fissure lesion. The patient reported both esthetic and psychological LP lesion-related discomfort.

The lesion was first noticed almost a year before but it had not been previously treated. The clinical examination revealed that a lesion that was located on the right side of the lower lip and it was around two centimeters diameter. No additional oral lesions were found. A cytology specimen test did not show any specific marks. The lesion was treated with a Zn ointment.

A year later, the patient contacted a dermatologist again and complained of a rankling wound on the lower lip and sensitivity of the oral mucosa, reporting that the treatment had had no positive effect. Oral examination revealed multiple lichen planus lesions, which were clinically and histologically diagnosed as oral LP, but there was no skin or genital mucosa involvement. The photomicrograph showed hypertrophic LP with acanthosis and lichenoid mononuclear dermal infiltrate but no dysplasia elements were found. The patient was further referred to the Vilnius University Dental Hospital, Lithuania. The patient complained of rankling painful wounds on the lower lip and oral mucosa. Oral examination revealed multiple erosive lichen planus manifestations on the lips and minor visible desquamative gingivitis (Fig. 1). A cytology test identified dysplasia in a specimen from the lower lip (Fig. 2). The patient was further referred to the Institute of Oncology of Vilnius University, Lithuania.

Surgical treatment of the lower lip squamous cell carcinoma lesion was done at the Institute of

Oncology of Vilnius University in 2007. Surgical biopsy material revealed an invasive proliferation of atypical squamoid cells (Fig. 3) and stage II of oral squamous cell carcinoma was diagnosed. After the surgical treatment, the lower lip had a cosmetic defect (Fig. 4).

The patient was unhappy with the cosmetic defect left after the surgical treatment; therefore she consulted a plastic surgeon in October 2012 at the Zalgiris Clinic of Vilnius University Hospital. An additional plastic surgical procedure was employed to correct the esthetic defect on the lower left lip. The lip plastic surgery was performed in 2013. Despite the multiple local, surgical and plastic surgery treatments, the oral examination revealed minor visible desquamative gingivitis (Fig. 5). No sign of dysplasia was found

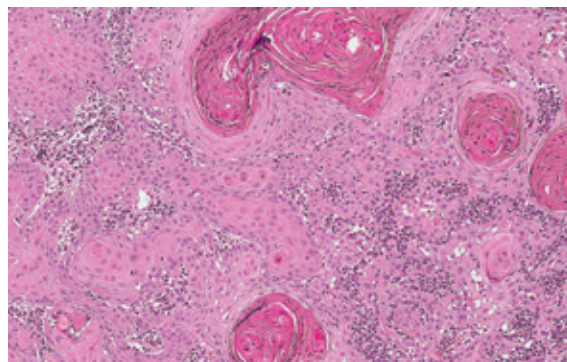


Fig. 3. Histopathological picture

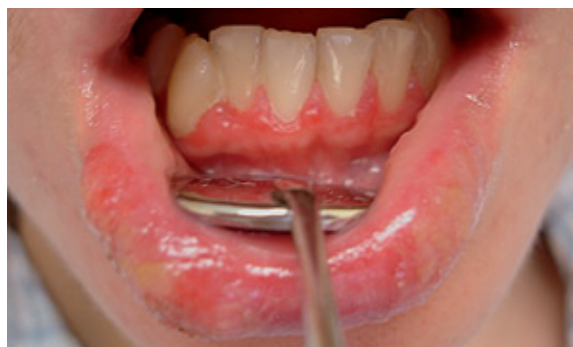

Fig. 1. Erosive lichen planus manifestations and desquamative gingivitis

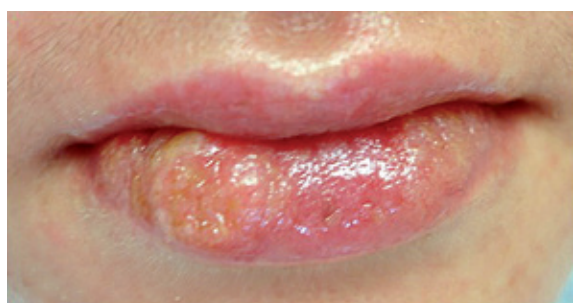

Fig. 2. Malignant transformation of oral lichen planus

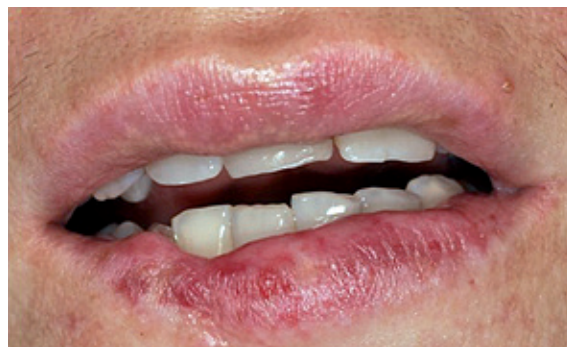

Fig. 4. The lower lip esthetic defect

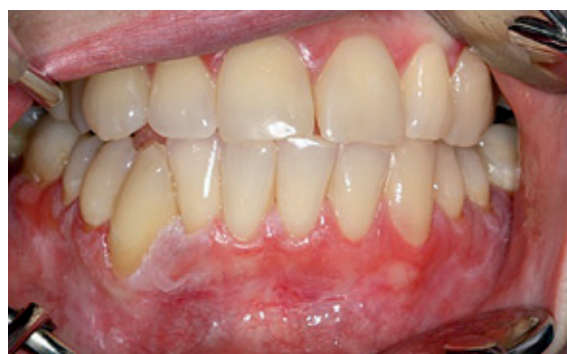

Fig. 5. Lichen planus manifestations

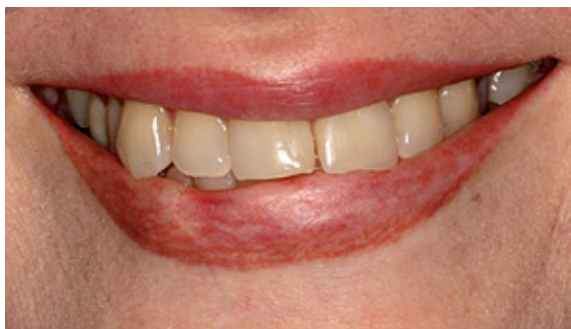

Fig. 6. Final result after multiple surgeries

but lichenoid mononuclear infiltrate still showed LP elements. Therefore, the patient needed a regular professional monitoring of oral and general health. Figure 6 presents the patient's photo after multiple surgeries. The patient was informed that the lesion may reoccur.

Discussion

The World Health Organization (WHO) defines oral lichen planus as a precancerous condition, associated with an increase in the risk of oral cancer [12]. According to the current definition, a precancerous lesion is "a morphologically altered tissue in which cancer is more likely to occur than in an apparently normal counterpart". The frequency of oral cancer among oral LP patients reported in 3 of the 4 retrospective studies available from 1985 to the present was 1.5%, with the follow up from 4.5 to 7.5 years [13]. The retrospective studies are quite heterogeneous and differ in source of data (clinical records and database of histological reports), inclusion criteria, length of follow-up, design, and geographical origin. However the results of these studies move in a relatively narrow range (0–5.3%) and do not contrast with those from prospective studies [13]. On the basis of this data, the transformation rate of oral LP appears to be around 1% over 5 years [13]. Such an incidence is much higher than any figure reported in medical literature for the oral cancer incidence in the general population and strongly supports the malignant potential of oral LP [13].

An oral biopsy with histopathological examination is recommended to confirm the clinical diagnosis and particularly to exclude dysplasia and malignancy. Treatment of LP depends on the symptoms, the extent of oral and extra-oral clinical involvement, medical history, and other factors. The principal aims of current OLP therapy are the resolution of painful symptoms and oral mucosal lesions, the reduction of the risk of oral cancer, and the maintenance of good oral hygiene to eliminate

the local exacerbating factors as a preventive measure. Up to now, different therapies are described for OLP including drug therapy, surgery, psoralen with ultraviolet light A (PUVA), and laser. The use of novel drug therapy is the most common method for treatment of OLP. Different drugs have been used in the form of topical and systemic application for the treatment of OLP. The drugs used in topical form are corticosteroids, immunosuppressives, retinoids, and immunomodulators. Drugs which are used systemically are thalidomide, metronidazole, griseofulvin, and hydroxychloroquine, as well as some retinoids and corticosteroids. Small and accessible erosive lesions located on the gingiva and palate can be treated by the use of an adherent paste in the form of a custom tray, which allows for accurate control over the contact time and ensures that the entire lesional surface is exposed to the drugs [14]. In the case of patients with lichenoid lesions, the suspected precipitant should be eliminated. Mechanical injury or irritants such as rough restoration margins or badly fitting dentures should be given attention, and an optimal program of oral hygiene instituted, particularly in patients with gingival LP. Patients with symptomatic lesions may also need treatment, usually with drugs (topical and systemic corticosteroids and other immunosuppressive agents), but occasionally surgery has a role. [15]. Surgical excision, cryotherapy, CO₂ laser, and ND:YAG laser have all been used in the treatment of OLP. In general, surgery is reserved to remove high-risk dysplastic areas. Phototherapy, a new method in which the clinician uses ultraviolet A (UVA) with wavelengths ranging from 320 to 400 nm, after the injection of psoralen, is also used. Relaxation, meditation and hypnosis have a positive impact on many cutaneous diseases and help to calm and rebalance the inflammatory response which can ameliorate inflammatory skin disorders [14].

The understanding of malignant transformation of lichen planus lesions has significantly improved over the last 20 years, but a number of key issues still need further research, e.g. the examination of factors relevant to the progression and regression of the disease. Accumulation of inducible nitric oxide synthase (iNOS) with 8-nitroguanine and 8-oxo-7, 8-dihydro-2-deoxyguanosine (8-oxodG) in the oral epithelium in OLP may reflect nitrative and oxidative damage to DNA that could be the basis of the malignancy [15]. The prevalence of oral mucosal lesions is age-dependent and in the 20- to 29-year-old group is only around 5.6% [16]. The labial site involvement and desquamative gingivitis are observed rarely, up to 8.1% [17]. When LP manifests in atypical locations and symptoms are absent, this may lead to delayed diagnosis. In addi-

tion to this, the fact that no other systemic diseases or factors were present in the young patient made the case challenging for medical professionals. In such cases, the post-treatment follow-up is essential to detect any recurrences in a timely fashion.

Oral squamous cell carcinoma is a rare complication of LP that can develop at any age. LP labial site involvement is rare. Lesions that do not heal within two three weeks should be considered for additional histological examination.

References

- [1] INGAFOU M., LEAO J.C., PORTER S.R., SCULLY C.: Oral lichen planus: a retrospective study of 690 British patients. *Oral Dis.* 2006, 12, 463–468.
- [2] SUGERMAN P.B., SAVAGE N.W., WALSH L.J., ZHAO Z.Z., ZHOU X.J., KHAN A., SEYMOUR G.J., BIGBY M.: The pathogenesis of oral lichen planus. *Crit. Rev. Oral Biol. Med.* 2002, 13, 350–365.
- [3] SUGERMAN P.B., SAVAGE N.W.: Oral lichen planus: causes, diagnosis and management. *Aust. Dent. J.* 2002, 47, 290–297.
- [4] SEOANE J.: Oral lichen planus: a clinical and morphometric study of oral lesions in relation to clinical presentation. *Braz. Dent. J.* 2004, 15, 9–12.
- [5] KRASOWSKA D.: Psychological stress, endocrine and immune response in patients with lichen planus. *Int. J. Dermatol.* 2008, 47, 1126–1134.
- [6] TABOLLI S.: Quality of life and psychological problems of patients with oral mucosal disease in dermatological practice. *Dermatol.* 2009, 218, 314–320.
- [7] MANOLACHE L., SECELEANU-PETRESCU D., BENEVA V.: Lichen planus patients and stressful events. *J. Eur. Acad. Dermatol. Venereol.* 2008, 22, 437–441.
- [8] DE SOUSA F.A.: Comparative analysis of cell proliferation ratio in oral lichen planus, epithelial dysplasia and oral squamous cell carcinoma. *Med. Oral Patol. Oral Cir. Bucal.* 2009, 14, 563–567.
- [9] FANG M.: Malignant transformation of oral lichen planus: a retrospective study of 23 cases. *Quintess. Int.* 2009, 40, 235–242.
- [10] ARISAWA E.A.: Clinicopathological analysis of oral mucous autoimmune disease: A 27-year study. *Med. Oral Patol. Oral Cir. Bucal.* 2008, 13, 94–97.
- [11] LOPEZ-JORNET P., CAMACHO-ALONSO F., BERDUGO M.L.: Measuring the impact of oral mucosa disease on quality of life. *Eur. J. Dermatol.* 2009, 19, 603–606.
- [12] PINDBORG J.J., REICHART P.A., SMITH C.J., VAN DER WAAL I.: WHO International histological classification of tumours. *Histological typing of cancer and precancer of the oral mucosa.* Springer, Berlin 1997.
- [13] LODI G., SCULLY C., CARROZZO M., GRIFFITHS M., SUGERMAN P.B., THONGPRASOM K.: Current controversies in oral lichen planus: Report of an international consensus meeting. Part 2. Clinical management and malignant transformation. *Oral Surg. Oral Med. Oral Pathol. Oral Radiol. Endod.* 2005, 100, 164–178.
- [14] GUPTA S., JAWANDA M.K.: Oral lichen planus: an update on etiology, pathogenesis, clinical presentation, diagnosis and management. *Indian J. Dermatol.* 2015, 60, 222–229.
- [15] SCULLY C., CARROZZO M.: Oral mucosal disease: lichen planus. *Brit. J. Oral Maxillofac. Surg.* 2008, 46, 15–21.
- [16] SPLIETH C.H., SUMNIG W., BESSEL F., JOHN U., KOCHER T.: Prevalence of oral mucosal lesions in a representative population. *Quintess. Int.* 2007, 38, 23–29.
- [17] GUMRU B.: A retrospective study of 370 patients with oral lichen planus. *Med. Oral. Patol. Oral. Cir. Bucal.* 2013, 18, 427–432.

Address for correspondence:

Barbara Zawadzka
Institute of Odontology
Faculty of Medicine
Vilnius University
Vilnius
Lithuania
E-mail: bzavadzka@yahoo.com

Conflict of Interest: None declared

Received: 15.07.2015

Revised: 4.08.2015

Accepted: 10.10.2015