

Oral lichen planus: a 4-year clinical follow-up study

Arūnas RIMKEVIČIUS¹, Jolanta ALEKSEJŪNIENĖ², Alina PŪRIENĖ¹, Dmitrij ŠEININ³, Rūta RASTENIENĖ^{1*}

¹Institute of Odontology, Faculty of Medicine, University of Vilnius, Vilnius, Lithuania

²Faculty of Dentistry, University of British Columbia, Vancouver, BC, Canada

³National Center of Pathology, Vilnius University Hospital Santariškiu Klinikos, Vilnius, Lithuania

Received: 16.11.2015 • Accepted/Published Online: 11.09.2016 • Final Version: 00.00.2017

Background/aim: This study aimed to examine oral lichen planus (OLP) cases histopathologically and cytologically, describe different clinical aspects of OLP manifestations, and associate different OLP clinical forms with self-reported oral health and with local and systemic risk factors.

Materials and methods: All patients with a referral diagnosis of OLP received biopsies. The histological evaluation assessed infiltration with lymphocytes, epithelial hyperplasia, and hyperkeratosis. Histology was used to validate the OLP diagnosis and to evaluate the malignant transformation of OLP lesions. Clinical manifestations of OLP and potential local oral environment-related risks were clinically assessed. Systemic risks were evaluated by a structured questionnaire.

Results: A total of 133 patients with a histologically confirmed OLP diagnosis were followed. There were more females (N = 109) than males (N = 24) and the majority of patients were older than 50 years. The reticular form (45.1%) was the most prevalent clinical form followed by the erosive-ulcerative form (33.8%). The histological characteristics were most pronounced in the erosive-ulcerative form. Of the OLP cases, 2.3% had a malignant transformation.

Conclusion: Reticular and erosive-ulcerative were the most prevalent OLP forms. There were more female than male OLP patients. Except for medication use, there were no statistically significant differences among different clinical OLP forms in either local or systemic risk factor distributions.

Key words: Oral lichen planus, local risks, systemic risks, malignant transformation

1. Introduction

The World Health Organization has described oral lichen planus (OLP) as a precancerous disease (1) that may involve the mucous membrane and skin of various areas (2). A predominance of OLP in women, commonly occurring in the 6th and 7th decades of life, has been reported (3,4). The prevalence of OLP in different populations ranges from 0.02% to 1.2% (5). The known clinical forms of OLP are reticular, erosive-ulcerative, erythematous, and atrophic (6), with the reticular and erosive-ulcerative forms being the most common (7,8). OLP lesions are usually bilateral and common oral sites are the buccal cheek mucosa, tongue, gums, lips, and palate (9,10). Multiple sites of OLP involvement are common (4,11).

A higher *Candida* presence in subjects with OLP than in those with healthy mucosal tissues has been reported (12). The prominent histological feature in OLP is the hydropic degeneration of basal epithelial cells and a band-like infiltration of T lymphocytes (13). A 27-year

retrospective study reported that the majority of OLP cases ($\geq 90\%$) presented infiltration of inflammatory cells with a predominance of T lymphocytes and hyperkeratosis or hyperorthokeratosis, while acanthosis and hyperplasia were observed in one-third of the cases (11). The extent of inflammation and clinical erythema has been associated with the intensity of symptoms (8), i.e. minimally inflamed OLP lesions were painless, whereas the most severe and painful lesions were observed in patients with an erosive-ulcerative OLP form (8,14,15).

The malignancy of OLP has been controversial with malignant transformation rates ranging from 0.2% up to 12.5%, these rates being up to 60 times higher as compared to the general population (13,16,17). The malignant transformation of OLP lesions has been attributed to both intrinsic (inflammation mediators) and extrinsic factors (18). Risks of OLP, an exacerbation of this disease, or its malignant potential have been associated with numerous potential risk factors such as genetics, medication use,

* Correspondence: rasteniene.ruta@gmail.com

stress, dental treatments, systemic diseases, and lifestyle factors such as smoking or alcohol abuse (19–23).

Patients with OLP or its risk factors have not been studied in Lithuania; thus, it is unclear how OLP manifests in Lithuanians compared to patients from other countries. The aims of the present study were as follows:

- Examine OLP referral cases histopathologically and cytologically.
- Evaluate clinical manifestations of OLP.
- Associate different OLP clinical forms with self-reported oral health, local, and systemic risk factors.

2. Materials and methods

The present study was approved by the Research Ethics Committee of the Faculty of Medicine of Vilnius University and by the Ministry of Health of Lithuania. During the 4-year follow-up period, the clinical manifestations of different OLP forms, potential local and systemic risk factors for OLP, and the rate of malignant transformation were studied.

2.1. Sample

The present study included all patients referred to the Vilnius University Dental Clinic from different locations around the country during the time period of 2009–2013 with a histologically confirmed lichen planus diagnosis. Based on clinical manifestations, lichen planus cases were grouped into papular, reticular, erosive-ulcerative, bullous, or atrophic forms. The operationalization of study variables is presented in Table 1.

2.2. Histological assessment

Incisional biopsy was used for histopathological examinations and to confirm the diagnosis of lichen planus. All patients with the referral diagnosis of OLP received biopsies. The biopsy specimens ranged in size from 3.0 mm × 3.0 mm to 10.0 mm × 2.0 mm. The biopsy samples of the oral mucosa were 10% formalin-fixed, paraffin-embedded, and stained with hematoxylin and eosin and subsequently underwent morphological analysis to evaluate oral mucosa infiltration with lymphocytes, oral mucosa hyperplasia and hyperparakeratosis, and ulceration of the squamous epithelium. The presence of infiltration or hyperplasia was scored as minimal, medium, or high. Histological assessment was also used to validate the OLP diagnosis and to evaluate the malignant transformation of OLP lesions to squamous cell carcinoma.

2.3. Cytological assessment

In recent years, the importance of pathogenic microorganisms such as *Candida albicans* in patients with lichen planus has been recognized (24–27). Exfoliative cytology concerning surface cells is used for identifying

the presence of abnormal cells, bacteria, and fungi. In the present study, cytology samples were taken from the tongue and a direct examination method was employed to determine the presence of *Candida* species.

Two swabs were prepared and oral mucosa scrapings were thinly spread and dried on a slide. One of the swabs was fixed with a May–Grünwald fixer and the Nachtblau method was used for staining. Subsequently, changes of cell morphology (nucleus, cytoplasm, etc.) were examined by a binocular microscope with an immersion lens and eyepiece. Number and size of atypical cells, their characteristics, degree of differentiation, mitosis quantity, and nature were described. When cells with signs of malignancy were found, an excisional biopsy specimen was sent for histological examination and for the specification of diagnosis to the National Center of Pathology.

The second swab was fixed with 96% ethanol and positive Gram staining. This staining method was used for the identification of microorganisms with a binocular microscope. Using this staining, gram-positive microbial cells, micelles and spores of *Candida* fungus, *Actinomyces*, and cells of *Lactarius* turn blue, while gram-negative microorganisms stain red.

2.4. Questionnaire/interview

Information regarding self-reported oral health and systemic risk factors was collected by means of a structured questionnaire. In order to reduce the number of missing answers, personal interviews were added when questionnaires were incomplete.

The self-administered questionnaire collected data about demographics (sex, age), lifestyle (smoking, drinking), number of negative life events, and information about systemic risks such as family history of OLP, systemic diseases, medication use, and extraoral manifestations of OLP (skin and genitals).

2.5. Oral clinical examination

The clinical examination was performed by one examiner (RA) and included an assessment of OLP clinical forms, location of OLP lesions, and the presence of multiple sites of oral involvement (Table 1).

2.6. Statistical analyses

All statistical analyses were performed employing SPSS 21.0. Bivariate analyses (chi-square test or Fisher exact test) were used to compare proportions of cytological and histological characteristics among different OLP forms. Bivariate comparisons among different OLP forms were also made regarding the mean number of local risks (refer to Table 1: local risks) and regarding the mean number of different systemic risk factors (refer to Table 1: systemic risks). The threshold of statistical significance for all tests was $P < 0.05$.

Table 1. Operationalization of the study variables.

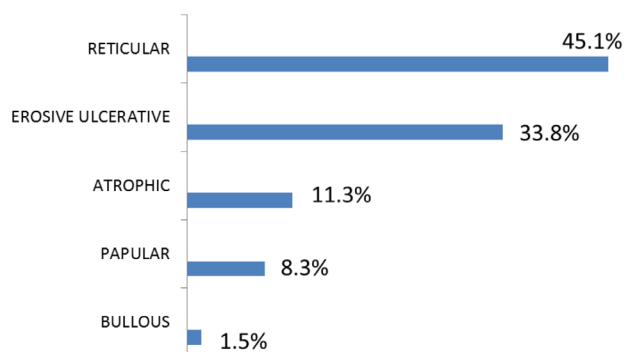
Study variables	Operationalization of variables
Histopathology	Leukocyte infiltration (1+, 2+, 3+), hyperkeratosis (present or absent), hyperplasia (1+, 2+, 3+), epithelial necrosis (present or absent), carcinogenesis (present or absent).
Cytology	Presence of: bacteria (abundant or minimal), <i>Candida</i> (abundant, minimal, or absent), <i>Actinomyces</i> (present or absent), and atypical cells (present or absent). Biopsy-related side effects: (pain, bleeding, infection).
Clinical manifestation	Clinical forms (examination): papular = 1, reticular = 2, erosive-ulcerative = 3, bullous = 4, atrophic = 5.
	Intraoral localization (examination): buccal mucosa, gums, tongue (lateral surfaces, back), lips (mucosa, flushing), oral vestibule, palate (hard, soft), Yes = 1, No = 0. Multiple site involvement: total number of OLP lesions.
	Extraoral localization (self-reports): Skin: Yes = 1, No = 0. Genitals: Yes = 1, No = 0. Exacerbation (self-reports): Yes = 1, No = 0.
	Repeated OLP episodes (self-reports): Yes = 1, No = 0.
Local risks	Bimetallism (self-reports). Local risk factors (examination): sharp tooth edges, poor oral hygiene, defective fillings, root tips, chronic dental infections, dental caries, silver amalgams, fixed prostheses (crowns, bridges), and removable prostheses.
Systemic risks	Total number of systemic diseases (self-reports).
	Total number of medications (self-reports).
	Total number of different allergies (self-reports).
Negative life events	Self-reported life events: partner's death, death of a family member, divorce, financial or legal problems, severe morbidity or trauma.
Family history	Family history (self-reports): Lichen Planus: Yes = 1, No = 0. Family history (self-reports) of systemic diseases. Yes = 1, No = 0.
Lifestyle factors	Smoking (self-reports): Yes = 1, No = 0.
	Alcohol abuse (self-reports): Yes = 1, No = 0.

3. Results

In the 4-year follow-up period, a total of 136 patients with OLP diagnosis were referred to the Vilnius University Žalgirio Clinic, of which 111 were females and 25 were males. The majority of patients (~70.0%) were above 50 years of age. Of all referrals from different locations in the country, only three cases were not histologically validated for the OLP diagnosis. Thus, the study included a total of 133 OLP clinical cases.

3.1. Clinical, histopathological, and cytological examinations

Figure 1 presents the distribution of different OLP clinical forms, where one can see that the largest proportion of patients presented with a reticular form (45.1%), followed by an erosive-ulcerative form (33.8%) with the bullous clinical form being the least prevalent (1.5%).

**Figure 1.** Lichen planus – distribution of clinical forms.

The histological comparisons (Table 2) among different OLP clinical forms revealed statistically significant differences regarding all histological characteristics except for the presence of malignant transformation. The

Table 2. Histological assessment of oral lichen planus cases.

Clinical forms	Leukocyte infiltration			Hyperkeratosis		Hyperplasia			Epithelial necrosis		Carcinoma	
	1+	2+	3+	Present	Absent	1+	2+	3+	Present	Absent	Present	Absent
N (%)	N (%)	N (%)	N (%)	N (%)	N (%)	N (%)	N (%)	N (%)	N (%)	N (%)	N (%)	N (%)
Papular, N = 11	2 (18.2)	9 (81.8)	0 (0.0)	4 (36.4)	7 (63.6)	7 (63.6)	4 (36.4)	0 (0.0)	0 (0.0)	11 (100.0)	0 (0.0)	11 (100.0)
Reticular, N = 58	6 (10.3)	34 (58.6)	18 (31.1)	38 (65.5)	20 (34.5)	25 (43.1)	26 (44.8)	7 (12.1)	10 (17.2)	48 (82.8)	0 (0.0)	58 (100.0)
Erosive-ulcerative, N = 47	2 (4.3)	19 (40.4)	26 (55.3)	35 (74.5)	12 (25.5)	11 (23.4)	31 (66.0)	5 (10.6)	36 (76.6)	11 (23.4)	3 (6.4)	44 (93.6)
Bullous, N = 2	0 (0.0)	1 (50.0)	1 (50.0)	1 (50.0)	1 (50.0)	0 (0.0)	1 (50.0)	1 (50.0)	2 (100.0)	0 (0.0)	0 (0.0)	2 (100.0)
Atrophic, N = 15	4 (26.7)	8 (53.3)	3 (20.0)	6 (40.0)	9 (60.0)	13 (86.7)	0 (0.0)	0 (0.0)	7 (46.7)	8 (53.3)	0 (0.0)	15 (100.0)
*Plaque-like	--	--	--	--	--	--	--	--	--	--	--	--
Significance#	P = 0.010			P = 0.045		P < 0.001			P < 0.001		P = 0.230	

* Plaque-like OLP (absent cases) was not included in statistical comparisons; # Chi-square test or Fisher exact test.

highest level of leukocyte infiltration and the presence of hyperkeratosis, hyperplasia, and epithelial necrosis were most frequently observed in erosive-ulcerative clinical forms of OLP.

Table 3 presents results of cytological and clinical examinations and compares four clinical OLP forms. The bullous form had to be excluded from statistical analyses because there were too few cases with a bullous clinical OLP form (N = 2).

Histology of biopsy samples showed that different clinical OLP forms presented a similar presence of bacteria with about one-fourth of all clinical OLP forms presenting extensive amounts of bacteria. The highest levels of *Candida* species were found in the ulcerative-erosive OLP cases. Only a few cases in all clinical OLP forms presented with *Actinomyces*. The most exacerbation occurred in cases with the ulcerative-erosive OLP clinical form and the least number of repeated episodes were reported for patients

with the papular OLP form. The malignant transformation rate for all clinical forms was 2.3%.

All clinical forms occurred in at least two sites and there were no statistically significant differences in mean numbers of site involvement among different clinical forms. The largest proportion of extraoral lesion involvement was reported for ulcerative-erosive OLP. Statistically significant differences between the papular and erosive-ulcerative forms ($P < 0.001$) and between the papular and atrophic forms ($P = 0.003$) were found, with better self-reported oral health observed in patients with the papular OLP form than in patients with either erosive-ulcerative or atrophic OLP forms. More details about the interindividual variation in the four clinical OLP groups are illustrated in box-whisker plots (Figures 2–4).

Figure 2 compares the clinical OLP forms in terms of their acute manifestations. The bullous form is not represented in this figure due to the limited number of

Table 3. Clinical and histological comparisons among OLP clinical forms.

	Papular N (%)	Reticular N (%)	Erosive-ulcerative N (%)	Atrophic N (%)	P-values
Cytology*					
Multiple bacteria	3 (27.3)	14 (23.3)	10 (22.2)	4 (26.7)	0.848
Extensive <i>Candida</i>	0 (0.0)	5 (8.3)	8 (17.8)	2 (13.3)	0.281
<i>Actinomyces</i>	0 (0.0)	2 (3.3)	1 (2.2)	0 (0.0)	0.825
Atypical cells	0 (0.0)	0 (0.0)	1 (2.2)	0 (0.0)	0.588
Clinical manifestation*					
Exacerbation	0 (0.0)	0 (0.0)	33 (73.3)	2 (13.3)	<0.001
Repeated episodes	3 (27.3)	40 (66.7)	33 (73.3)	10 (66.7)	0.038
Lesion localization*					
Buccal mucosa	8 (72.7)	56 (93.3)	37 (82.2)	13 (86.7)	0.170
Gums	6 (54.5)	27 (45.0)	26 (57.8)	2 (13.3)	0.026
Tongue	1 (9.1)	21 (35.0)	16 (35.6)	4 (26.7)	0.340
Lips	0 (0.0)	5 (8.3)	7 (15.6)	0 (0.0)	0.181
Oral vestibule	0 (0.0)	5 (8.3)	5 (11.1)	1 (6.7)	0.683
Palate	0 (0.0)	1 (1.7)	4 (8.9)	0 (0.0)	0.176
Extraoral	3 (27.3)	6 (10.0)	13 (28.9)	5 (33.3)	0.050
	Mean ± SD	Mean ± SD	Mean ± SD	Mean ± SD	P-values
Multiple site involvement#	1.9 ± 0.7	2.5 ± 1.2	2.8 ± 1.6	2.3 ± 1.5	0.260
Self-reported oral health#	3.4 ± 0.8	2.8 ± 0.8	2.2 ± 0.7	2.3 ± 0.9	<0.001

* Chi-square test/Fischer exact test; # independent sample t-test.

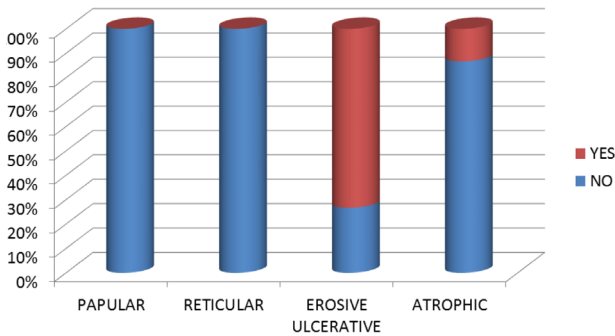


Figure 2. Exacerbation of different lichen planus forms.

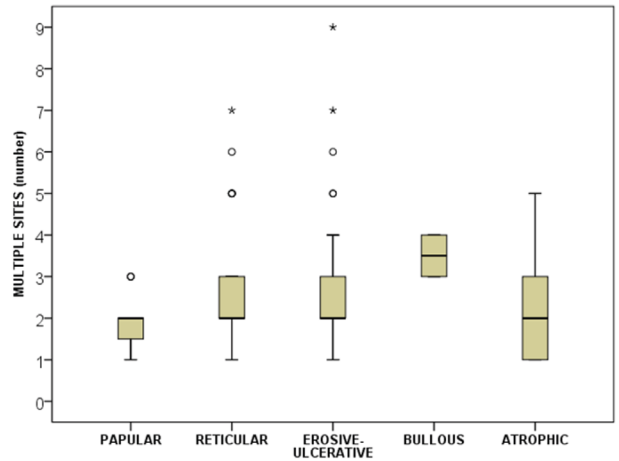


Figure 3. Numbers of lichen planus lesions – comparison among different clinical forms.

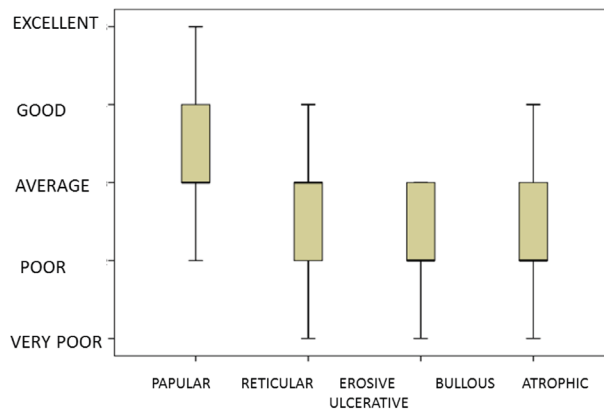


Figure 4. Self-rated oral health in patients with different OLP clinical forms.

cases (N = 2). More of the erosive-ulcerative cases were acute compared to the other three clinical forms (papular, reticular, or atrophic).

Figure 3 presents the distribution of different clinical forms of OLP in terms of the total number of clinical sites of OLP lesions. One can see that all clinical forms presented in at least two locations and the highest number of sites with OLP lesions were observed for reticular and ulcerative forms, with some patients having up to seven intraoral lesions. Extraoral involvement (skin and genitals) was self-reported in 22.0% of OLP cases.

As it relates to clinical symptoms, the majority of patients with OLP noted at least some discomfort due to their disease (95.0%), with 77.0% of them reporting moderate and 54.0% reporting high levels of pain.

Figure 4 illustrates how patients with different OLP forms perceived their oral health. The patients with erosive-ulcerative or atrophic forms perceived their oral health as

being poorer (median: poor) than patients with other OLP forms. There was substantial variation in self-rated oral health among patients with all OLP clinical forms. Large variation in self-rated oral health was observed among the patients with papular OLP (from poor to excellent), among the patients with the reticular form (from very poor to good), and among the patients with the atrophic form (from very poor to good).

3.2. Relationships between OLP clinical forms and local/systemic risk factors

Table 4 presents a comparison of OLP clinical forms regarding their potential risk factors. Both local and systemic risks were related to different OLP clinical forms, but only one significant association was found: patients with atrophic OLP used more medications than patients with other OLP clinical forms. The majority of OLP patients had a family history of systemic diseases, while a family history of lichen planus was rare.

Table 4. Local and systemic risk comparisons among OLP clinical forms.

Number of	Papular Mean±SD	Reticular Mean±SD	Erosive-ulcerative Mean±SD	Atrophic Mean±SD	P-values
Local risks	2.5 ± 1.2	3.3 ± 1.5	3.5 ± 1.7	3.5 ± 2.8	0.301
Systemic diseases	2.0 ± 2.3	2.6 ± 2.1	3.2 ± 2.9	3.1 ± 1.4	0.348
Medications	0.9 ± 0.8	1.0 ± 1.0	1.0 ± 1.1	1.9 ± 1.1	0.025
Allergies	0.6 ± 0.7	0.6 ± 1.1	0.5 ± 0.7	0.3 ± 0.5	0.572
Negative events	1.8 ± 1.9	1.7 ± 1.2	1.5 ± 1.2	1.1 ± 1.1	0.291
	No (%)	No (%)	No (%)	No (%)	
Smoking	1 (9.1)	9 (15.0)	4 (8.9)	0 (0.0)	0.370
Alcohol abuse	0 (0.0)	2 (3.3)	0 (0.0)	1 (6.7)	0.409
Family history					
Lichen planus	0 (0.0)	5 (8.3)	4 (8.9)	2 (13.3)	0.683
Systemic diseases	10 (91.9)	39 (75.0)	28 (63.2)	11 (73.3)	0.160

* Chi-square test/Fischer exact test; # independent sample t-test.

4. Discussion

The present study examined all patients referred to the University Dental Clinic with a histologically confirmed OLP diagnosis. There were significantly more females than males and the majority of patients (~70.0%) were above 50 years of age. Similar findings have been reported elsewhere (4).

Similar to other studies, the most commonly affected site was the buccal mucosa, followed by the gums, and multiple OLP lesions were observed in about half of OLP patients (4). About half of our patients reported substantial pain or discomfort related to their disease. This finding is in accordance with other studies in which a high proportion of OLP patients were symptomatic (2,28). We observed patients with two or more sites affected by lichen planus and extraoral involvement of lichen planus was seen in approximately one out of five patients. Our rate of extraoral involvement is similar to that of another study (4), but lower than in other studies where rates of up to 45% of extraoral involvement were reported (7,29,30). These substantial differences between countries are difficult to explain but we have no reason to assume that our patients underreported their disease status. Given that exposure to OLP risk factors might differ among countries, there may also be differences regarding the rates of extraoral clinical manifestations of this disease.

We examined associations between OLP and a number of potential local as well as systemic risk factors. Except for the relationship between the atrophic OLP form and medication use, there were no statistically significant differences in potential risk factor distributions among

different OLP clinical forms. Possibly, potential risks similarly contribute to the pathogenesis of different OLP forms. Another explanation for our findings may be that, due to a relatively low variation in some systemic risks, we were not able to discern the associations between different clinical forms of OLP and potential risk factors. For example, only a small proportion of our OLP patients reported smoking or alcohol abuse. Therefore, it is possible that due to lack of variation in these risk factors, we were unable to determine the effects of smoking or alcohol abuse. It is important to note that evidence about the role smoking or alcohol abuse plays in the etiopathogenesis of lichen planus is inconsistent, with some studies not associating these risks with OLP (4,31), while other studies related smoking and alcohol abuse to a higher potential to develop dysplastic changes (23).

In the present study, the malignant transformation rate of 2.3% was slightly higher than in some studies where this rate was under 2.0% (19,28,32). The rate of malignant potential has been controversial, possibly due to a wide range of reported incidences of 0%–12.5% (16,17). Further studies are needed to better predict OLP patients who are at risk of developing oral squamous cell carcinoma (OSCC).

It has been suggested that in patients with severe OLP, determining the protooncogene C-MYC helps to predict patients with a high risk of progression to oral squamous cell carcinoma (33). Most importantly, OLP patients are at increased risk for the development of OSCC, and consequently regular follow-ups, e.g., once a year, are necessary to detect any malignant transformation (19,32).

Larger sample studies are needed to acquire evidence about local as well as systemic risks and their relationship to different OLP clinical forms. A case-control study with well-matched matched controls, preferably recruited from a general population, is recommended to study this rare disease and its associated risks.

In conclusion, the reticular and ulcerative OLP forms were more prevalent than the papular, atrophic, or bullous clinical forms. More females than males were among our OLP patients, and the majority of OLP patients were above 50 years of age. The most frequently affected sites were

the buccal mucosa and gums. There were no statistically significant differences among OLP clinical forms in distribution of local or systemic risk factors. About half of the patients reported substantial discomfort or pain. The rate of malignant transformation to squamous cell carcinoma was 2.3%.

Acknowledgment

This manuscript was edited by English language scientific language consultant Clare Davies (University of British Columbia, Canada).

References

- Liu Y, Messadi DV, Wu H, Hu. Oral lichen planus is a unique disease model for studying chronic inflammation and oral cancer. *Med Hypotheses* 2010; 75: 492-494.
- Jaafari-Ashkavandi Z, Mardani M, Pardis S, Amanpour S. Oral mucocutaneous diseases: clinicopathologic analysis and malignant transformation. *J Craniofac Surg* 2011; 22: 949-951.
- Kesic L, Obradovic R, Mihailovic D, Radicevic G, Stankovic S, Todorovic K. Incidence and treatment outcome of oral lichen planus in southeast Serbia in a 10-year period (1997-2007). *Vojnosanit Pregl* 2009; 66: 435-439.
- Gumru B. A retrospective study of 370 patients with oral lichen planus in Turkey. *Med Oral Patol Oral Cir Bucal* 2013; 18: e427-e432.
- Lanfranchi-Tizeira HE, Aguas SC, Sano SM. Malignant transformation of atypical oral lichen planus: a review of 32 cases. *Med Oral* 2003; 8: 2-9.
- Au J, Patel D, Campbell JH. Oral lichen planus. *Oral Maxillofac Surg Clin North Am* 2013; 25: 93-100.
- Oliveira Alves MG, Almeida JD, Balducci I, Guimaraes Cabral LA. Oral lichen planus: a retrospective study of 110 Brazilian patients. *BMC Res Notes* 2010; 3: 157.
- Dissemond J. Oral lichen planus: an overview. *J Dermatolog Treat* 2004; 15: 136-140.
- Arcuri F, Stellin L, Gatti A, Benech A. Surgical approach to oral lichen planus by submucosal autologous fat grafting. *J Craniofac Surg* 2013; 24: e258-e260.
- Fernandez-Gonzalez F, Vazquez-Alvarez R, Reboiras-Lopez D, Gandara-Vila P, Garcia-Garcia A, Gandara-Rey JM. Histopathological findings in oral lichen planus and their correlation with the clinical manifestations. *Med Oral Patol Oral Cir Bucal* 2011; 16: e641-e646.
- Arisawa EA, Almeida JD, Carvalho YR, Cabral LA. Clinicopathological analysis of oral mucous autoimmune disease: a 27-year study. *Med Oral Patol Oral Cir Bucal* 2008; 13: E94-E97.
- Masaki M, Sato T, Sugawara Y, Sasano T, Takahashi N. Detection and identification of non-*Candida albicans* species in human oral lichen planus. *Microbiol Immunol* 2011; 55: 66-70.
- Valente G, Pagano M, Carrozzo M, Carbone M, Bobba V, Palestro G, Gandolfo S. Sequential immunohistochemical p53 expression in biopsies of oral lichen planus undergoing malignant evolution. *J Oral Patol Med* 2001; 30: 135-140.
- Kumar P, Bahirwani S, Raja JV, Pujari M, Tuteja M, Garg S. Oral mini pulse therapy: report of a case and review of the literature. *Oral Health Dent Manag* 2013; 12: 112-118.
- Nico MM, Fernandes JD, Lourenco SV. Oral lichen planus. *An Bras Dermatol* 2011; 86: 633-641.
- Gonzalez-Moles MA, Scully C, Gil-Montoya JA. Oral lichen planus: controversies surrounding malignant transformation. *Oral Dis* 2008; 14: 229-243.
- Mattsson U, Jontell M, Holmstrup P. Oral lichen planus and malignant transformation: is a recall of patients justified? *Crit Rev Oral Biol Med* 2002; 13: 390-396.
- Payeras MR, Cherubini K, Figueiredo MA, Salum FG. Oral lichen planus: focus on etiopathogenesis. *Arch Oral Biol* 2013; 58: 1057-1069.
- Eisen D. The clinical features, malignant potential, and systemic associations of oral lichen planus: a study of 723 patients. *J Am Acad Dermatol* 2002; 46: 207-214.
- Pourshahidi S, Fakhri F, Ebrahimi H, Fakhraei B, Alipour A, Ghapanchi J. Lack of association between *Helicobacter pylori* infection and oral lichen planus. *Asian Pac J Cancer Prev* 2012; 13: 1745-1747.
- Bajaj DR, Khoso NA, Devrajani BR, Matlani BL, Lohana P. Oral lichen planus: a clinical study. *J Coll Physicians Surg Pak* 2010; 20: 154-157.
- Klosek SK, Sporny S, Stasikowska-Kanicka O, Kurnatowska AJ. Cigarette smoking induces overexpression of c-Met receptor in microvessels of oral lichen planus. *Arch Med Sci* 2011; 7: 706-712.
- Torrente-Castells E, Figueiredo R, Berini-Ayres L, Gay-Escoda C. Clinical features of oral lichen planus. A retrospective study of 65 cases. *Med Oral Patol Oral Cir Bucal* 2010; 15: e685-e690.
- Artico G, Freitas R, Santos FA, Benard G, Romiti R, Migliari D. Prevalence of *Candida* spp., xerostomia, and hyposalivation in oral lichen planus - a controlled study. *Oral Dis* 2014; 20: e36-34.

25. Bokor-Bratic M, Cankovic M, Dragnic N. Unstimulated whole salivary flow rate and anxiolytics intake are independently associated with oral *Candida* infection in patients with oral lichen planus. Eur J Oral Sci 2013; 121: 427-433.
26. Kragelund C, Kieffer-Kristensen L, Reibel J, Bennett EP. Oral candidosis in lichen planus: the diagnostic approach is of major therapeutic importance. Clin Oral Investig 2013; 17: 957-965.
27. Mehdipour M, Taghavi ZA, Hekmatfar S, Adibpour M, Bahramian A, Khorshidi R. Prevalence of *Candida* species in erosive oral lichen planus. J Dent Res Dent Clin Dent Prospects 2010; 4: 14-16.
28. Xue JL, Fan MW, Wang SZ, Chen XM, Li Y, Wang L. A clinical study of 674 patients with oral lichen planus in China. J Oral Pathol Med 2005; 34: 467-472.
29. Silverman SJ, Gorsky M, Lozada-Nur F, Giannotti K. A prospective study of findings and management in 214 patients with oral lichen planus. Oral Surg Oral Med Oral Patol 1991; 72: 665-670.
30. Thorn JJ, Holmstrup P, Rindum J, Pindborg JJ. Course of various clinical forms of oral lichen planus. A prospective follow-up study of 611 patients. J Oral Patol 1988; 17: 213-218.
31. Seoane J, Romero MA, Varela-Centelles P, Diz-Dios P, Garcia-Pola MJ. Oral lichen planus: a clinical and morphometric study of oral lesions in relation to clinical presentation. Brazilian Dental Journal 2004; 15: 9-12.
32. Lozada-Nur F, Miranda C. Oral lichen planus: epidemiology, clinical characteristics, and associated diseases. Semin Cutan Med Surg 1997; 16: 273-277.
33. Segura S, Rozas-Munoz E, Toll A, Martin-Ezquerria G, Masferrer E, Espinet B, Rodriguez M, Baro T, Barranco C, Pujol RM. Evaluation of MYC status in oral lichen planus in patients with progression to oral squamous cell carcinoma. Br J Dermatol 2013; 169: 106-114.