

# Multiple magnet ingestion in children: presentation, diagnostics and management

## Magnetiniai svetimkūniai vaikų virškinamajame trakte: klinikinė išraiška, diagnostika, gydymas

Aurelija Daškevičiūtė<sup>1</sup>, Smiltė Kolevinskaitė<sup>1</sup>, Kęstutis Trainavičius<sup>2</sup>

<sup>1</sup> Faculty of Medicine, Vilnius University, M. K. Čiurlionio Str. 21, LT-03101 Vilnius, Lithuania

<sup>2</sup> Vilnius University, Department of Gastroenterology, Nefrourology and Surgery, Center of Pediatric Surgery, Santariskiu Str. 7, LT-08406 Vilnius, Lithuania  
E-mail: aurelijadaskeviciute@gmail.com

<sup>1</sup> Vilniaus universiteto Medicinos fakultetas, M. K. Čiurlionio g. 21, LT-03101 Vilnius, Lietuva

<sup>2</sup> Vilniaus universitetas, Gastroenterologijos, nefrourologijos ir chirurgijos klinika, Vaikų chirurgijos centras, Santariškių g. 7, LT-08406 Vilnius, Lietuva  
El. paštas: aurelijadaskeviciute@gmail.com

---

### Introduction

Although most ingested foreign bodies pass innocuously through the gastrointestinal tract, multiple magnets can lead to serious injury resulting from the attraction of the magnets across tissues.

### Objectives

To identify the clinical presentation, diagnostics and management of magnet ingestions.

### Methods

A retrospective review of magnet ingestions treated between January 2011 and January 2016 was developed. Patients' demographics, clinical information, radiologic images and surgical records were obtained.

### Results

7 cases of multiple magnet ingestions were identified. Three patients presented with magnets located in the stomach. All of those patients were asymptomatic; two of them underwent endoscopic removal. Three patients presented with magnets located in the small intestine; two of them had abdominal pain and underwent laparoscopic retrieval. Spontaneous evacuation of magnets occurred in two cases. One asymptomatic patient had magnets located in the colon; enema was performed and evacuation of magnets occurred.

### Conclusion

Cases of multiple magnets ingestion require aggressive management as migration of the objects might result in complications and greater morbidity.

**Key words:** children, magnet ingestion, clinical presentation, diagnostics, management

**Ivadas**

Dauguma į virškinamąjį traktą patekusių svetimkūnių pasišalina savaime, tačiau nuryti magnetiniai svetimkūniai dėl tarpusavio traukos per žarnyno sienas gali sukelti gyvybei grėsmingų komplikacijų.

**Tikslas**

Nustatyti magnetinių svetimkūnių virškinamajame trakte klinikinę išraišką, diagnostikos ir gydymo metodus.

**Metodai**

Atlikta retrospektyvioji VUL SK Vaikų ligoninėje 2011 m. sausio–2016 m. sausio mėn. laikotarpiu gydytų magnetinių svetimkūnių virškinamajame trakte atvejų analizė. Rinkti ir analizuoti pacientų demografiniai, klinikiniai, radiologiniai duomenys ir operacijų protokolai.

**Rezultatai**

Tiriamuoju laikotarpiu nustatyti septyni magnetinių svetimkūnių virškinamajame trakte atvejai. Trims pacientams magnetai rasti skrandyje, šiems pacientams simptomų nebuvo, dviem iš jų buvo atliktas endoskopinis magnetų šalinimas. Trims pacientams magnetai rasti plonojoje žarnoje, du pacientai skundėsi pilvo skausmais, abiem atliktas laparoskopinis magnetų šalinimas. Vienam besimptomiam pacientui magnetai rasti storojoje žarnoje, jie pasišalino savaime paskyrus vidurių laisvinauosius vaistus.

**Išvados**

Diagnozavus magnetinius svetimkūnius virškinamajame trakte, pacientą būtina aktyviai stebėti arba magnetinius svetimkūnius šalinti dėl didelės komplikacijų rizikos.

**Reikšminiai žodžiai:** vaikai, magnetiniai svetimkūniai virškinamajame trakte, klinika, diagnostika, gydymas

**Introduction**

Swallowing multiple magnets is not uncommon worldwide and it frequently leads to serious consequences [1]. The small size and shiny surface of magnets make them an attractive target for ingestion by infants and toddlers. Ingestions by older children and adolescents, however, are also common, because they use the magnets to simulate a variety of face and body piercings [2].

In cases of magnet ingestion, the number of magnets ingested is critical. Two or more magnets separated along their course in the gastrointestinal tract may attract across bowel walls, causing pressure necrosis with subsequent small bowel obstruction, volvulus, fistula formation or perforation [3]. An increase in case reports describing complications from magnet ingestion have resulted in revisions of the current pediatric algorithm for ingestions with increased inpatient observation and earlier surgical consultation [4]. Unfortunately, many pediatric cases of magnet ingestion are not suspected until a child develops symptoms and the complications has occurred.

The purpose of this report is to draw attention to the dangers of the magnetic toys, and heighten physicians' awareness of the potential consequences. Furthermore, an updated algorithm is proposed to guide the man-

agement of patients who present with the ingestion of magnetic foreign bodies.

**Methods**

A retrospective review of magnet ingestion cases treated at Children's Hospital, Affiliate of Vilnius University Hospital Santariskiu Klinikos between January 2011 and January 2016 was developed. Identification of patients was performed using ICD-10 codes (T18.1, T18.2, T18.3, T18.4, T18.5, T18.8 and T18.9) from the hospital's administrative electronic database. Data gathered for each patient with magnetic foreign bodies ingestion included age, gender, past medical history, number of magnets ingested, timing of ingestion relative to the emergency department presentation, clinical presentation, physical and instrumental examination results, surgical records, medication therapy management and outcomes. Statistical analysis was performed using MS Excel.

**Results**

From 2011 to 2016, 7 cases of multiple (range 2–29) magnet ingestion were identified (Table 1). There were 5 males and 2 females aged from 1.5 to 16 years

(8.07±5.11). Time from magnet ingestion to the arrival to the emergency department varied from 1.5 to 72 hours (28.5±34.16). There were 3 cases with magnets located in the stomach. All of those patients were asymptomatic; two of them underwent endoscopic removal. Three patients presented with magnets located in the small intestine; two of them had complaints of abdominal pain and loss of appetite and underwent laparoscopic retrieval. One patient presented with magnets located in the colon. The patient was asymptomatic and magnets passed under clinical observation. Total days in the hospital varied from 1 to 8 days (3.29±2.98). Further we present all 7 cases of multiple magnet ingestion in more detail.

### **Cases of Magnets Located in the Stomach**

#### ***Case 1***

A 3-year-old boy was brought to the emergency room within 1,5 hour after having ingested a chainlet of 29 ball-shaped magnetic beads. On admission, the boy appeared in a relatively good condition; his abdomen was soft and non-tender. The only complaint was a discomfort in the chest area. An abdominal radiograph showed a chainlet of 29 round magnetic balls located in the stomach. The child was taken to the operating room for endoscopic retrieval of the magnetic chainlet. On entering the antrum, only part of the chainlet was indentified; another part was located in the first part of the duodenum. The chainlet was removed in a single pass using endoscopic forceps. The patient was discharged the next day after admission without further complications.

#### ***Case 2***

A 10-year-old girl presented to the emergency department within 1,5 hour after having ingested 2 ball-shaped magnetic beads. On physical examination, her abdomen was slightly tender in the epigastric region and in the right iliac region without distention or peritoneal signs. An abdominal radiograph showed the presence of 2 magnets attached end to end in the stomach. The child was taken to the operating room and the endoscopic retrieval of the magnets was performed. Attached magnets were removed using endoscopic forceps. The patient was discharged the next day after admission without further complications.

#### ***Case 3***

A 16-years-old boy was presented to the emergency department within 1,5 hour after having ingested 2 magnetic beads. According to his medical history, the patient drank plenty of water and made himself to vomit in order to regorge the ingested magnetic beads. On admission, the patient was asymptomatic and the physical examination showed no abnormal signs. There were no magnets on abdominal radiograph. On the next day, the magnets passed successfully and the patient was discharged home.

### **Cases of Magnets Located in the Small Intestine**

#### ***Case 4***

A 5-year-old boy presented to the pediatric emergency department with the complaints of abdominal pain, constipation for 4 days and multiple episodes of bilious vomiting for 3 days. There was no history of fever or preceding diarrhea. Vital signs were normal. Enema was performed in the emergency department that caused more intense pain with diffuse tenderness. Afterwards, abdomen ultrasound was performed. Gas in the digestive tract, mild inflammation in the intestines wall, and bowel obstruction were found. Abdominal radiographs showed distended bowel loops with multiple air-fluid levels and 15 bead-shaped magnets connected in a circular fashion in the umbilicus region. The patient was hospitalized and emergency laparotomy was performed. 9 connected magnetic beads were removed from the mesentery of the ascending colon. Loops of jejunum were entrapped in-between magnetic beads resulting in pressure necrosis and perforation of jejunum at 3 sites. 6 pieces of magnets were retrieved through enterotomy site. The margins of perforations were renewed and sutured with a double-row suture. The patient had been admitted to Intensive Care Unit for 2 days. Intravenous fluids and antibiotics were administered to him. The child was discharged home on the 6<sup>th</sup> day without any further complications for a 2-week follow-up.

#### ***Case 5***

A 10-year-old girl was admitted to emergency department with a short history of severe abdominal pain in the right iliac region and loss of appetite. She admitted

**Table 1.** Characteristics of multiple magnet ingestion cases

Case	Gender	Age (years)	Localization	Amount of magnets	Symptoms	Management
1	Male	3	Stomach	29	Discomfort in the chest area	Endoscopic retrieval
2	Female	10	Stomach	2	Tenderness in the epigastric region	Endoscopic retrieval
3	Male	16	Stomach	2	None	Spontaneous evacuation
4	Male	5	Small intestine	15	Abdominal pain, constipation, vomiting	Laparotomy
5	Female	10	Small intestine	3	Tenderness in the epigastric region, loss of appetite	Laparoscopic retrieval
6	Male	11	Small intestine	5	None	Spontaneous evacuation
7	Male	1,5	Colon	2	None	Spontaneous evacuation

to swallowing two magnets 2 days before the examination. Her abdominal examination revealed mild tenderness to palpation in the right iliac region and no peritoneal signs. While sonography of right iliac fossa was unremarkable, abdominal X-ray showed 3 ball-shaped magnetic beads in the right iliac region. The patient was kept under close observation and serial abdominal X-rays were taken daily which showed that all magnets were still present in the right iliac region. On the 4<sup>th</sup> day after admission the patient was taken to operating room for laparoscopic retrieval of the magnets. On careful examination 2 pressure necrosis sites proximal to ileo-caecal junction and 1 necrosis site near appendix were found. All three metallic beads could be palpated and were removed through enterotomy sites made in necrosis areas. Post-operation period was uneventful and the patient was discharged on the 8<sup>th</sup> day.

### Case 6

A 11-year-old boy presented to the pediatric emergency department within 3 hours after swallowing 5 magnets. The patient was asymptomatic and the physical examination findings were normal. An abdominal radiographs showed 5 connected magnetic beads in the right iliac region. The patient remained asymptomatic and repeat radiographs demonstrated passage of the magnets distally. The boy was discharged home for 2 days with

instructions to contact the surgery clinic if symptoms occur or if the magnets were not noted in his stool. The patient failed to pass the magnets after 48 hours. Plain abdominal radiograph showed magnets projecting at the level of the fifth lumbar vertebra on the left. Another abdominal X-ray showed foreign bodies in the minor pelvis. Because foreign bodies showed movement, the patient was left for observation. Magnetic beads eventually passed under the close clinical observation.

### Case of Magnets Located in the Colon

#### Case 7

A 18-months-old boy was presented to the emergency department within 3 days after swallowing 2 magnetic beads. The patient was asymptomatic and the physical examination was normal. An abdominal radiograph showed 2 connected magnetic beads located in the colon. Enema was performed and magnets passed spontaneously. The patient was discharged the next day after his admission.

#### Discussion

Most foreign bodies usually cause no harm and spontaneously pass the gastrointestinal tract without any treatment [5]. Although the ingestion of a single magnet may cause no problems, the multiple magnet ingestion can lead to significant gastrointestinal morbidity. The

magnets can attract each other across the bowel wall and this may lead to pressure necrosis, resulting in perforation, fistula formation, and/or intestinal obstruction [6]. In many cases, the clinician cannot rely on the accuracy of the history obtained from a young patient and the report of ingestion of one magnetic FB may represent the ingestion of multiple FBs [7]. Thus, the report of ingestion of a single magnetic FB requires a high degree of suspicion by the examining clinician.

Signs and symptoms of magnets ingestion are non-specific during the early stages [8]. Small magnets are not likely to have any initial symptoms unless a large number of magnets have been ingested [9]. Some patients may have complaints that mimic viral gastroenteritis, while cases of abdominal pain, discomfort or cramps, vomiting, or abdominal distension are of concern as these symptoms may suggest an impending intestinal obstruction [9]. In our experience, patients were asymptomatic until the complications have occurred. Most common symptoms were tenderness in the epigastric area, abdominal pain and loss of appetite. Most frequently the reason for admission to hospital was the fact of magnet ingestion itself but not the symptoms, as they tend to be mild and non-specific.

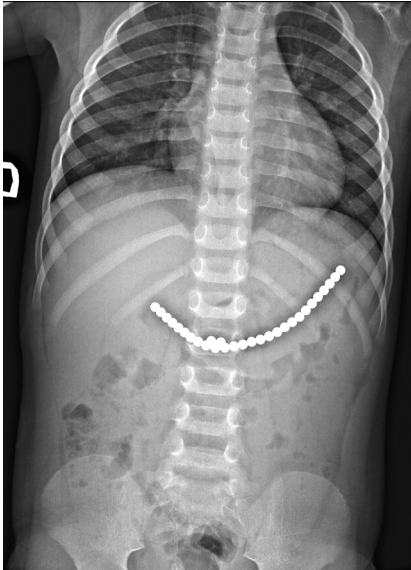
When a case of magnet ingestion is suspected, a careful differentiation between ingestion of a single magnet or multiple magnets should be done [10]. Numerous reports document instances of multiple magnets adhered tightly together, thus appearing as a single object on x-ray. Therefore, at least 2 views of the chest or abdomen should be obtained to determine the number of magnets present [2]. Although some authors suggest that if the object is below the diaphragm, further radiographs are generally unnecessary [11]. Nevertheless, plain radiography lack the sensitivity to determine the number of magnetic objects and any ingestion should be treated as though multiple magnets were ingested [12]. In our experience, all magnet ingestion cases were easily differentiated as magnet ingestion was known from the past medical history. Single plain abdominal radiographs were obtained and multiple magnet ingestion was clearly determined therefore there was no need to obtain further radiographs to differentiate single versus multiple magnet ingestion.

Although radiographs are generally recommended for the localization of metallic objects, the use of handheld metal detectors may be an option in some cases. According to the literature, the use of handheld metal detectors to identify the location of ingested aluminum (eg, flip top of a soda can) may be more sensitive since aluminum is often radiolucent [24]. Thus, metal detection may be superior to radiography in the case of aluminum location [13]. However, even radiopaque foreign bodies may be difficult to localize, thus in cases when metal object is ingested based on medical history the referral of endoscopy should be considered [14].

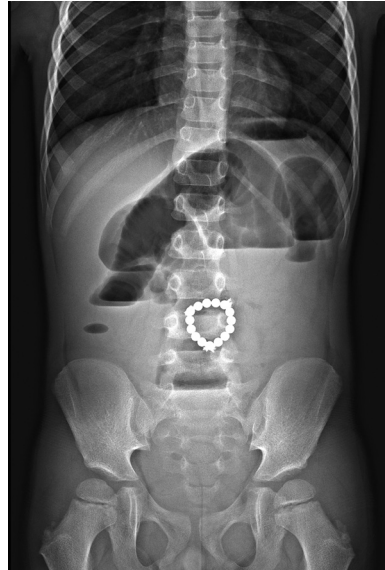
The American Society of Gastrointestinal Endoscopy recommends urgent removal of all magnets within endoscopic reach and surgical consultation for those out of reach with non-progression through the GI tract [15]. Less consistent practice are policies for objects that have reached the stomach. Some foreign bodies pass on their own and many clinicians have adopted a “waiting policy” in such cases [7]. The concern is that these patients may not become overtly symptomatic until a significant degree of bowel injury or even perforation has occurred.

According to NASPGHAN (North American Society for Pediatric Gastroenterology, Hepatology and Nutrition), a conservative approach may be chosen in cases of a single magnet ingestion and in asymptomatic patients with multiple magnets beyond the stomach when the progression of magnets on serial x-rays is observed. The general consensus among the NASPGHAN experts has been that if conservative management is chosen, direct patient observation in a controlled setting should be maintained. In addition, serial abdominal films and clear “ownership” of the patient until a passage of the magnets can be confirmed are vital [2]. Patients should be instructed to return if they experience abdominal pain or have symptoms suggestive of perforation or obstruction. The follow-up abdominal radiographs should be considered until the complete expulsion of the FB.

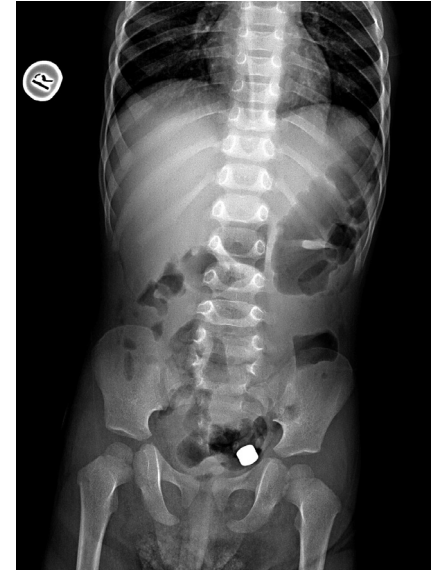In our tertiary care center there were no cases with esophageal metallic objects, though gastric metallic objects were removed via upper endoscopy using endoscopic forceps. Upper endoscopy was obtained in case when a metal object was reliably ingested and a “waiting policy” was adopted as metallic object was not found via endoscopy nor seen in abdominal radiographs.



**Figure 1.** Abdominal radiograph of a three-year-old boy with a chainlet of 29 round magnetic balls located in the stomach



**Figure 2.** Abdominal radiograph of a five-year-old boy shows distended bowel loops with multiple air-fluid levels and 15 bead-shaped magnets connected in a circular fashion in the umbilicus region



**Figure 3.** Abdominal radiograph of a one and a half year old boy shows 2 connected magnetic beads located in the colon

Although some authors claim that an emergency explorative laparotomy to remove the magnetic foreign bodies and necessary repairs should be performed as soon as multiple magnets have passed beyond the pylorus in cases they cannot be retracted [8, 16–18], the NAPSGHAN algorithm suggests a different approach. According to this algorithm, surgical intervention is suggested in cases of symptomatic patients with multiple magnets beyond the stomach and in cases of asymptomatic patients when no progression on serial X-rays is seen. However, there is no place in this algorithm for multiple magnets which are separated along their course in the gastrointestinal tract or when separation occurs on follow-up serial x-rays. In such cases, the potential of contraction of opposing magnets occurs and laparoscopy should be recommended as the first option for exploration [19].

One area of debate is whether the use of laxative agents to expedite the progression of a magnetic object through the intestine is indicated. According to NAPSGHAN, the laxatives may be used to aid the passage in cases of a single magnet ingestion if magnet is beyond the stomach and in cases of multiple magnet ingestion

when magnets are beyond the stomach if the patient is asymptomatic and no progression of magnets on serial X-rays is seen. In such cases, laxatives may be used to aid in passage and help prepare for colonoscopy. In our experience, laxatives were used in asymptomatic patient with magnets located in the colon and resulted in complete expulsion of ingested magnets.

## Conclusions

Small magnetic toys are getting more and more popular and are easily ingested by children. The ingestion of multiple magnetic foreign bodies is associated with a significant risk of morbidity and even mortality. Radiology is one of the key components to evaluate ingested magnets. The cases of multiple magnets ingestion require aggressive management as migration of the objects might result in complications and greater morbidity. It is essential that pediatric providers are well informed regarding the severe and potentially fatal sequel that may ensue magnet ingestion and consider foreign body ingestion of any kind as part of the differential diagnosis.

## REFERENCES

1. Oestreich AE. Worldwide survey of damage from swallowing multiple magnets. 2009; p. 142–7.
2. Kramer RE, Lerner DG, Lin T, Manfredi M, Shah M, Stephen TC et al. Management of ingested foreign bodies in children: a clinical report of the NASPGHAN Endoscopy Committee. *J Pediatr Gastroenterol Nutr* [Internet]. 2015; 60(4): 562–74. Available from: <http://www.ncbi.nlm.nih.gov/pubmed/25611037>
3. Tavarez MM, Saladino RA, Gaines BA, Manole MD. Brief Reports. *J Emerg Med* [Internet]. Elsevier Ltd. 2013; 44(1): 261–8. Available from: <http://dx.doi.org/10.1016/j.jemermed.2012.03.025>
4. Butterworth J, Feltis B. Toy magnet ingestion in children: revising the algorithm. 2007; p. 5–7.
5. Nui A, Hiramata T, Katsuramaki T, Maeda T. An intestinal volvulus caused by multiple magnet ingestion: an unexpected risk in children. 2005; p. 40–2.
6. Alzahem AM, Soundappan SS V, Jefferies H, Cass DT. Ingested magnets and gastrointestinal complications. *J Paediatr Child Health*. 2007; 43(6): 497–8.
7. Pavlidis TE, Marakis GN, Triantafyllou A, Psarras K, Kontoulis TM, Sakantamis AK. Management of ingested foreign bodies. How justifiable is a waiting policy? *Surg Laparosc Endosc Percutan Tech*. 2008; 18(3): 286–7.
8. Liu S, Li J, Lv Y. Gastrointestinal damage caused by swallowing multiple magnets. 2012; 6(3): 280–7.
9. Hussain SZ, Bousvaros A, Gilger M, Mamula P, Gupta S, Kramer R et al. Management of ingested magnets in children. *J Pediatr Gastroenterol Nutr* [Internet]. 2012; 55(3): 239–42. Available from: <http://www.ncbi.nlm.nih.gov/pubmed/22785419>
10. Sahin C, Alver D, Gulcin N, Kurt G, Celayir AC. A rare cause of intestinal perforation: Ingestion of magnet. *World J Pediatr* 2010; 6(4): 369–71.
11. Silverberg M, Tillotson R. Case report: esophageal foreign body mistaken for impacted button battery. *Pediatr Emerg Care* [Internet]. 2006; 22(4): 262–5. Available from: <http://www.ncbi.nlm.nih.gov/pubmed/16651919>
12. Kay M, Wylie R. Techniques in Gastrointestinal Endoscopy Foreign body ingestions in the pediatric population and techniques of endoscopic removal. *YTGIE* [Internet]. Elsevier Inc. 2013; 15(1): 9–17. Available from: <http://dx.doi.org/10.1016/j.tgie.2012.09.005>
13. Conners GP. Diagnostic uses of metal detectors: A review. *Int J Clin Pract*. 2005; 59(8): 946–9.
14. Ginsberg GG. Management of ingested foreign objects and food bolus impactions. *Gastrointestinal Endoscopy*, 1995; p. 33–8.
15. Ikenberry SO, Jue TL, Anderson MA, Appalaneni V, Banerjee S, Ben-Menachem T, et al. Management of ingested foreign bodies and food impactions. *Gastrointest Endosc*. 2011; 73(6): 1085–91.
16. Tavarez MM, Saladino R, Gaines B, Manole MD. Prevalence, Clinical Features and Management of Pediatric Magnetic Foreign Body Ingestions. *J Emerg Med* [Internet]. Elsevier Ltd. 2012; 44(1): 261–8. Available from: <http://dx.doi.org/10.1016/j.jemermed.2012.03.025>
17. İlçe Z, Samsun H, Mammadov E, Celayir S. Intestinal volvulus and perforation caused by multiple magnet ingestion: Report of a case. *Surg Today*. 2007; 37(1): 50–2.
18. Adikibi BT, Arnold M. Magnetic bead toy ingestion: uses and disuses in children. 2013; 10–3.
19. Naji H, Isacson D, Svensson JF, Wester T. Bowel injuries caused by ingestion of multiple magnets in children: A growing hazard. *Pediatr Surg Int*. 2012; 28(4): 367–74.