

# Opposite chromosome constitutions due to a familial translocation t(1;21)(q43;q22) in 2 cousins with development delay and congenital anomalies

## A case report

Beata Aleksišūnienė, MSc<sup>a,\*</sup>, Rugilė Matulevičiūtė<sup>b</sup>, Aušra Matulevičienė, MD, PhD<sup>a</sup>, Birutė Burnytė, MD<sup>a</sup>, Natalija Krasovskaja, MD<sup>c</sup>, Laima Ambrozaitytė, PhD<sup>a</sup>, Violeta Mikštienė, MD<sup>a</sup>, Vaidas Dirsė, MSc<sup>d</sup>, Algirdas Utkus, MD, PhD<sup>a</sup>, Vaidutis Kučinskas, PhD<sup>a</sup>

### Abstract

**Rationale:** Chromosomal rearrangements are the major cause of multiple congenital abnormalities and intellectual disability.

**Patient concerns and diagnosis:** We report 2 first cousins with unbalanced chromosomal aberrations of chromosomes 1 and 21, resulting from balanced familial translocation. Chromosome microarray analysis revealed 8.5Mb1q43q44 duplication/21q22.2q22.3 deletion and 6.8Mb 1q43q44 deletion/21q22.2q22.3 duplication. Among other features, cognitive and motor development delay and craniofacial anomalies are present in both patients, whereas congenital heart defect and hearing impairment is only present in patient carrying 1q43q44 duplication/21q22.2q22.3 deletion.

**Lessons:** In this report, we provide detailed analysis of the phenotypic features of both patients as well as compare our data with previously published reports of similar aberrations and discuss possible functional effects of *AKT3*, *CEP170*, *ZBTB18*, *DSCAM*, and *TMPRSS3* genes included in the deleted and/or duplicated regions. Partial trisomy 1q/monosomy 21q has only been reported once before, and this is the first report of partial monosomy 1q/trisomy 21q. The expressed phenotype of mirroring chromosomal aberrations in our patients supports the previous suggestion that the dosage effect of some of the genes included in deleted/duplicated regions may result in opposite phenotypes of the patients.

**Abbreviations:** CCA = corpus callosum abnormality, CHD = congenital heart defect, DS = Down syndrome, DSCAM = Down syndrome cell adhesion molecule, DSCR = Down syndrome critical region, MLPA = multiplex ligation-dependent probe amplification, OFC = occipitofrontal circumference, SNP-array = single nucleotide polymorphism array.

**Keywords:** 1q43q44 deletion/duplication, 21q22.2q22.3 deletion/duplication, congenital heart defects, corpus callosum abnormalities, development delay

## 1. Introduction

Duplications/deletions of chromosome 21 have been subjected to extensive studies due to their link to Down syndrome (DS). While there is great variability in their phenotypic expression, development delay, intellectual disability, and dysmorphic features are most commonly associated with these aberrations.<sup>[1]</sup> Similarly, phenotypic presentation of 1q43q44 deletions has been

previously defined as 1q43q44 deletion syndrome (612337, OMIM), with microcephaly, development delay, and corpus callosum abnormalities (CCA) being most prominent features.<sup>[2]</sup> Phenotype of 1q43q44 duplication varies from moderate to severe, and this aberration has been commonly linked to congenital heart defects (CHDs).<sup>[3]</sup> Advanced molecular genetic techniques, such as chromosome microarray analysis, offer an opportunity to delineation of even small aberrations, thus

Editor: Xiaolin Zhu.

Funding/support: The preparation of the manuscript was funded by Medical Faculty of Vilnius University. The authors declare no potential conflicts of interest with respect to the research, authorship, and/or publication of this manuscript.

The authors have no conflicts of interest to disclose.

Supplemental Digital Content is available for this article.

<sup>a</sup> Department of Human and Medical Genetics, Faculty of Medicine, Vilnius University, <sup>b</sup> Faculty of Medicine, Vilnius University, <sup>c</sup> Centre for Medical Genetics, Vilnius University Hospital Santariskiu Klinikos, <sup>d</sup> Hematology, Oncology and Transfusion Medicine Centre; Vilnius University Hospital Santariskiu Klinikos, Vilnius, Lithuania.

\* Correspondence: Beata Aleksišūnienė, Department of Human and Medical Genetics, Faculty of Medicine, Vilnius University, Santariskiu st. 2, LT-08661, Vilnius, Lithuania (e-mail: beata.aleksiuniene@mf.vu.lt).

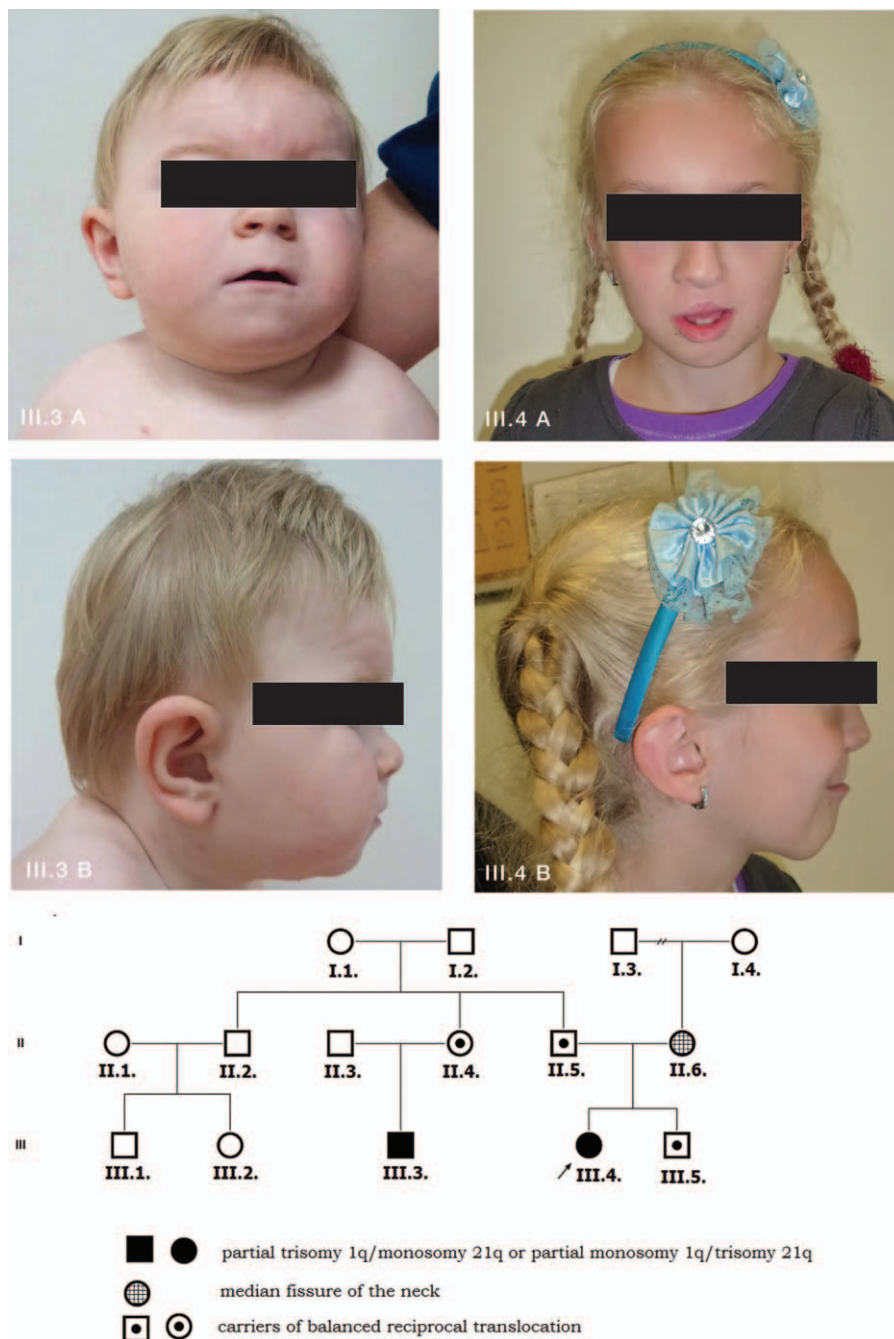
Copyright © 2017 the Author(s). Published by Wolters Kluwer Health, Inc.

This is an open access article distributed under the terms of the Creative Commons Attribution-Non Commercial License 4.0 (CCBY-NC), where it is permissible to download, share, remix, transform, and build upon the work provided it is properly cited. The work cannot be used commercially without permission from the journal.

Medicine (2017) 96:16(e6521)

Received: 8 December 2016 / Received in final form: 10 February 2017 / Accepted: 9 March 2017

<http://dx.doi.org/10.1097/MD.00000000000006521>



**Figure 1.** Overview of patients' phenotypic data and family pedigree. Facial characteristics of the patients. Frontal (III. 3. A) and lateral (III. 3. B) view of patient III.3: note microcephaly, brachycephaly, arched eyebrows, short palpebral fissures, congenital left ptosis, wide nasal bridge with bulbous nasal tip and long smooth philtrum, thin lips, macrotia with overfolded helices, and short neck. Frontal (III.4. A) and lateral (III.4. B) view of patient III.4: note macrocephaly, triangular asymmetric face, hypertelorism, downslanted palpebral fissures, bilateral cleft lip palate after surgical correction. Pedigree of the family. Affected patients indicated with black symbols: III.4—partial trisomy 1q/monosomy 21q; III.3—partial monosomy 1q/trisomy 21q. Carriers of balanced reciprocal translocation are indicated with dots in the symbols: II.4; II.5; III.5. Mother of III.4 and III.5 (II.5) with surgically corrected median fissure of the neck (indicated with check circle).

allowing a more precise comparison among previously published reports.

Here, we report 2 first cousins—patient III.4 and patient III.3 (Fig. 1)—with unbalanced chromosomal aberrations, 1q43q44 duplication/21q22.2q22.3 deletion, and 1q43q44 deletion/21q22.2q22.3 duplication, respectively, resulting from balanced familial translocation. Dysmorphic features, cognitive and motor development delay, as well as other anomalies are present in both

patients. To the best of our knowledge, partial trisomy 1q/monosomy 21q has only been reported once before,<sup>[4]</sup> and this is the first report of partial monosomy 1q/trisomy 21q. Furthermore, we have not observed previous reports comparing the possible effects of the opposite chromosomal aberrations as reported here. Thus, this report may offer unique insight into their phenotypic presentation, suggesting possible gene dosage effect of some of the genes included in the deleted/duplicated regions.

## 2. Clinical reports

We present 2 affected first cousins (III.4 and III.3) with craniofacial dysmorphism, multiple congenital anomalies, and intellectual disability. Carriers (II.4, II.5, and III.5) of balanced reciprocal translocation were phenotypically normal.

**Patient III.4:** Patient (Fig. 1III.4. A and III.4. B), currently a 10-year-old, is a first female child of young, nonconsanguineous parents with complicated family history (Fig. 1). Her birth weight was 3550 g (50th centile), birth length 53 cm (50th centile), occipitofrontal circumference (OFC) 37 cm (97th centile), and Apgar score of 8 at 1 and 5 minutes. Due to multiple congenital anomalies, patient was consulted by clinical geneticist, and distinct dysmorphic features, including macrocephaly, hypertelorism, bilateral cleft lip and palate, natal tooth, arachnodactyly, rocker bottom feet, club feet, and joint hypermobility, were noted. Echocardiography revealed atrial septal defect and bicuspid aortic valve. Multiple cysts were detected by neurosonoscopy. Pathologies of other organs were not observed. Patient underwent surgical correction of cleft lip at the age of 6 months and cleft palate at the age of 2 years. Patient's development was delayed. She started to crawl at the age of 16 months, stand at 20 months, and walk without assistance at 24 months. Her gross and fine motor skills were poor, she lacked coordination, and emotional instability was present. At the age of 6 years, dilatation of aortic root and ascending aorta was diagnosed. Otorhinolaryngological examination revealed narrowing external auditory canal and bilateral hearing failure. Hypernasal speech was present. In ophthalmological examination, convergent strabismus, posterior embryotoxon, and anisocoria were detected, later bilateral cataract developed. Fundus examination showed small optic nerve discs surrounded by pigment accumulation from nasal side. Brain magnetic resonance imaging revealed expressed internal and external hydrocephaly, mega cisterna magna, and signs of cerebellar vermiploplasia. When examined at the age of 8 years, the patient's parameters were weight 24 kg (<50th centile), height 132 cm (75th centile), and OFC 56 cm (>97th centile). Some changes were observed in the facial features: triangular asymmetric face, downslanted palpebral fissures, hemangioma in the medium of the lower lip. She also had asymmetrically positioned nipples, joint hypermobility, and intellectual disability. The speech development of the girl was severely delayed. Her active speech limited to about 20 words, with hypernasal speech present.

**Patient III.3:** Patient (Fig. 1III.3. A and III.3. B) is a 30-month-old nonverbal male born to healthy nonconsanguineous parents with complicated family history (Fig. 1) and complicated pregnancy due to oligohydroamnion in third trimester. At birth (41 weeks' gestation), he weighed 2920 g (<3rd centile) with the length of 48 cm (3rd centile), OFC of 30 cm (<3rd centile), and Apgar scores of 8 at 1 and 9 at 5 minutes. The following dysmorphic features were present: microcephaly, brachycephaly, arched eyebrows, short palpebral fissures, congenital left ptosis, wide nasal bridge with bulbous nasal tip and long smooth philtrum, thin lips, macrotia with overfolded helices, short neck, hockey-stick crease on the left palm, penoscrotal hypospadias, and right inguinal hernia that later resolved without surgical intervention. From the first days of his life, patient experienced feeding difficulties. Hypotonia was also observed. Evaluation of musculoskeletal system revealed craniosynostosis involving bilateral squamous temporal sutures and club feet. Brain ultrasound showed hypoplasia of corpus callosum. Despite febrile seizures present, electroencephalography revealed no changes. In instrumental tests, heart and inner organs were

without any pathology. Hearing was not impaired. When examined at the age of 18 months, significant psychomotor development delay was noted. Patient's head control was insufficient, and generalized muscular hypotonia impaired his ability to sit without support. Severe intellectual disability was evident as patient had poor social contact. Delay of the babbling stage of language acquisition was also noted.

## 3. Materials and methods

The patients' parents provided informed consent to publish all clinical information including photographs of the patients.

### 3.1. Cytogenetic analysis

Karyotyping analysis was carried out using G-banding techniques on stimulated peripheral blood lymphocytes according to standard laboratory protocols. Chromosome spreads were analyzed at the 400 to 550 band resolution level. A total of 30 metaphases were analyzed for each case. The karyotypes were described according to the guidelines of the International System for Human Cytogenetic Nomenclature.

### 3.2. FISH analysis

FISH analyses of subtelomeric regions were performed on blood lymphocytes and cultivated amniocytes using subtelomeric region-specific probes 170-kb sized 1qter (D1S555, red) and 190-kb sized 21qter (D21S1446, blue) (Poseidon RF; Kretech Diagnostics, Amsterdam, The Netherlands) according to the manufacturer's protocol. Twenty metaphases were analyzed for each probe. Images were obtained with a Nikon Eclipse 80i epifluorescence microscope equipped with a cooled CCD camera (JAI, Japan) and the LUCIA v2 software (LUCIA Cytogenetics TM, Prague, Czech Republic).

### 3.3. Molecular analysis (SNP-array)

DNAs were extracted from blood samples using the phenol–chloroform extraction method. Genome-wide analysis was performed using the HumanCytoSNP-12v2.1 BeadChips (Illumina, Inc., San Diego, CA), which contains 299,140 SNPs distributed across the human genome with an average resolution of 31 kb. The analysis was done according to standard protocol provided by Illumina. Beadchips were scanned with an Illumina HiScanSQ scanner using standard settings. Genotypes were called by GenomeStudio Genotyping Module v1.7 (Illumina, Inc.) for patient III.4 and Genotyping Module v1.9 (Illumina, Inc.) for patient III.3; LRR and BAF values were extracted from GenomeStudio software and used in further CNV analysis and breakpoint mapping with Hidden Markov Model-based QuantiSNP software (v1.1 for patient III.4 and v2.1 for patient III.3).<sup>[5]</sup> The data were analyzed using GRCh37/hg19 annotation. Database of Genomic Variants (<http://projects.tcag.ca/variation/>), DECIPHER database (<http://decipher.sanger.ac.uk/>), UCSC (<http://genome.ucsc.edu/>), and Online Mendelian Inheritance in Man (<http://www.omim.org/>) were used for the interpretation of the results.

### 3.4. MLPA analysis

DNAs were extracted from blood samples using the phenol–chloroform extraction method according to standard laboratory protocols. Multiplex ligation-dependent probe amplification

(MLPA) testing of both probands was carried out using SALSA MLPA P036 Subtelomeres Mix1 vE2 kit (MRC-Holland, Amsterdam, The Netherlands) according to the manufacturer's recommendations. Capillary electrophoresis was performed with a 3130×L Genetic Analyzer (Applied Biosystems by Thermo Fisher Scientific Inc., Waltham, MA). Fluorescent signals were analyzed with GeneMapper v3.7 software (Applied Biosystems by Thermo Fisher Scientific Inc.).

#### 4. Results

Cytogenetic analysis of patient III.4 revealed a normal karyotype. The karyotype of the father II.5 showed a balanced translocation between 1 and 21 chromosomes, with a chromosomal complement 46,XY,t(1;21)(q43;q22). Mother's (II.6) karyotype was normal.

To specify and confirm cytogenetic findings, FISH analyses were performed. FISH analysis of patient III.4 (Supplementary online material 1, <http://links.lww.com/MD/B634>) revealed derivative chromosome 21 resulting in a partial duplication of the terminal end of the long arm of chromosome 1 and a partial deletion of the terminal end of the long arm of chromosome 21. A FISH analysis from amniocytes of proband's (III.4) brother (III.5) showed balanced translocation between 1 and 21 chromosomes.

The karyotype of patient III.3 was considered normal. FISH analyses were performed for patient III.3 (Supplementary online material 1, <http://links.lww.com/MD/B634>) and his parents. FISH analyses of patient III.3 demonstrated opposite version of chromosomal aberration detected in his first cousin (III.4)—derivative chromosome 1, resulting in a partial duplication of the terminal end of the long arm of chromosome 21 and a partial deletion of the terminal end of the long arm of chromosome 1. The balanced translocation was presented in patient's mother (II.4).

To further map the chromosomal aberrations, single nucleotide polymorphism array (SNP-array) was carried out. SNP-array analysis of the patient III.4 (Supplementary online material 2, <http://links.lww.com/MD/B634>) revealed a duplication of 8.5 Mb in size at 1q43q44 (arr[hg19] 1q43q44(240,724,339–249,202,755)×3) and a deletion of 6.8 Mb in size at 21q22.2q22.3 (arr[hg19] 21q22.2q22.3(41,274,744–48,098,824)×1). SNP-array analysis of patient III.3 (Supplementary online material 3, <http://links.lww.com/MD/B634>) revealed an opposite chromosomal rearrangement: a deletion of 8.5 Mb in size at 1q43q44 (arr[hg19] 1q43q44(240,724,339–249,202,755)×1) and a duplication of 6.8 Mb in size at 21q22.2q22.3 (arr[hg19] 21q22.2q22.3(41,282,698–48,098,824)×3). The 1q43q44 region encompassing 30 OMIM genes, including 6 disease-causing genes: *FH*, *SDCCAG8*, *AKT3*, *ZBTB18* (*ZNF238*), *COX20* (*FAM36A*), and *NLRP3*. The 21q22.2q22.3 region includes 58 OMIM genes, including 16 disease-causing ones: *RIPK4*, *TMPRSS3*, *RSPH1*, *CBS*, *CRYAA*, *SIK1*, *CSTB*, *AIRE*, *ITGB2*, *COL18A1*, *TSPEAR*, *COLA1*, *COL6A2*, *FTCD*, *LSS*, and *PCNT*. MLPA analysis confirmed the chromosomal aberrations in both patients. More detailed description of disease-causing genes included in the deleted and duplicated regions is provided in Supplementary online material 4, <http://links.lww.com/MD/B634>.

#### 5. Discussion

Here we report 2 first cousins with 1q43q44 duplication/deletion and 21q22.2q22.3 deletion/duplication due to balanced familial translocation between 1q and 21q. Although there have been

reports of patients with deletions/duplications involving one of these regions, to the best of our knowledge, partial trisomy 1q/monosomy 21q (albeit involving slightly larger regions than detected in our case) has only been reported once before,<sup>[4]</sup> and this is the first report of combined 1q43q44 deletion and 21q22.2q22.3 duplication.

Pure terminal 1q43q44 deletion has been associated with specific features and defined as 1q43q44 deletion syndrome (612337, OMIM). This syndrome characterizes the high degree of phenotypic variability. Intellectual disability, development delay, microcephaly, and dysmorphic facial features such as wide nasal bridge with prominent tip and thin lips CCA have been observed in patients with this structural abnormality<sup>[2,6,7]</sup> as also seen in our patient III.3 (Table 1). In this region, *AKT3* has been reported as the most likely candidate gene to be responsible for phenotypic presentation of microcephaly.<sup>[8]</sup> *AKT3*, a serine–threonine kinase, is a member of the protein kinase B family.<sup>[9]</sup> Studies of both humans and rodents showed its expression being the highest in the brain tissue,<sup>[10,11]</sup> and in 1q44 deletion patients encompassing *AKT3* microcephaly is one of the most prominent features.<sup>[8]</sup> However, it has been suggested by Gai et al<sup>[9]</sup> that *AKT3* deletion might be associated with microcephaly with incomplete penetrance. It has also been hypothesized that *AKT3* effect might be dosage sensitive as it has been linked with macrocephaly in cases of 1q44 duplications.<sup>[12]</sup> Such mirroring phenotype is also observed in our case as microcephaly is present in a patient III.3 with 1q43q44 deletion, whereas macrocephaly in 1q43q44 duplication in patient III.4.

The deletions of 1qter region are usually associated with CCA. Caliebe et al<sup>[13]</sup> hypothesized that *HNRPU* is causative of CCA. Nagamani et al<sup>[14]</sup> studies showed that the region encompassing *CEP170* and *ZBTB18* genes is critical for development of CCA. Highly expressed in the brain, *CEP170* codes for a centrosomal protein and has been hypothesized to have a role in the evolution of human brain size and development of microcephaly,<sup>[15]</sup> whereas the studies of *ZBTB18* knockout mice showed that they have severe cerebral anomalies.<sup>[16]</sup> In our patients, *AKT3*, *ZBTB18*, *CEP170*, and *HNRNPU* genes are implicated in 1qter deletion/duplication region leading us to assume that they might be responsible for the phenotypic presentation.

Cases of 1q43q44 duplications most often occur as a result of balanced translocations. Patients with partial trisomy 1q demonstrate a wide range of manifestations of variable severity. Comparison of clinical features shows (Table 1) that macrocephaly, prominent forehead, hypertelorism, intellectual disability, and development delay are the most frequent findings.<sup>[12,17,18]</sup> Cardiac anomalies have also been reported in patients with pure 1q terminal duplications, especially in duplications including bands 1q43 and q44.<sup>[19,20]</sup> Atrial septum defect, bicuspid aortic valve, and dilatation of aorta are present in our patient III.4, while other reported patient with a similar translocation t(1;21)(q42.3;q22.3) did not demonstrate any cardiac anomalies.<sup>[4]</sup> Such variable manifestation of cardiac phenotypes might also be due to a number of genetic and environmental factors playing a role in their etiology.

Duplication of chromosome 21 has been a subject of extensive studies to identify DS critical region (DSCR), resulting in phenotypic expression of DS, and 21q22 has been previously identified as such region.<sup>[21]</sup> However, recent studies of partial trisomy 21 suggested that rather than a single DSCR, the phenotypic features could be attributed to several dosage sensitive genes on chromosome 21.<sup>[22,23]</sup> Our patient III.3 does not exhibit typical DS phenotype; however, microcephaly,

**Table 1**

**Comparison of clinical features found in our patients and the data from previous reports.**

Clinical features	van Bon et al <sup>[2]</sup>				Wang et al <sup>[12]</sup>	Tuschl et al <sup>[4]</sup>				Patient IV.3 del1q43q44 & dup21q22.2q22.3	Patient IV.4 dup1q43q44 & del21q22.2q22.3				Ehling et al <sup>[27]</sup>
	del1q43q44					dup1q43q44					Patient 19				
	No. 2	No. 3	No. 4	No. 10		No. 2	No. 3	No. 4	No. 10		No. 2	No. 3	No. 4	No. 10	
Macrocephaly	-	-	-	-	+	-	-	-	-	-	-	-	-	-	
Microcephaly	+	+	+	+	-	+	+	+	+	+	+	+	+	+	
Brachycephaly	-	-	-	-	-	-	-	-	-	-	-	-	-	-	
Prominent forehead	+	+	+	+	+	+	+	+	+	+	+	+	+	+	
Hypertelorism	+	+	+	+	+	+	+	+	+	+	+	+	+	+	
Palpebral fissures	DS	Short	Short	Short	Short	Short	Short	Short	Short	Short	Short	Short	Short	DS	
Epicanthus	-	+	+	+	-	+	+	+	-	+	+	+	+	+	
Nasal bridge	-	Broad	Broad	Broad	-	Broad	Broad	Broad	-	Broad	Broad	Broad	Broad	Depressed	
Philtrum	-	Long, smooth	Long	Long	-	Long	Long	Long	-	Long	Long	Long	Long	Depressed	
CLP	+	-	-	-	+	-	-	-	+	-	-	-	-	-	
Ear anomalies	Narrowing external auditory canal	Oversized ears, overfolded helices	Low set, hypoplastic external ear, external auditory canal atresia	Low set, protruding	Low set, hypoplastic external ear, external auditory canal atresia	Low set, protruding	Low set, protruding	Low set, protruding	Low set, hypoplastic external ear, external auditory canal atresia	Low set, protruding	Low set, protruding	Low set, protruding	Low set, protruding	Low set, large dysplastic	
Hearing impairment	+	-	-	-	+	-	-	-	+	-	-	-	-	+	
Skeletal anomalies	Rocker bottom feet	Craniosynostosis	Congenital hip dysplasia	Congenital hip dysplasia	Rocker bottom feet	Craniosynostosis	Congenital hip dysplasia	Congenital hip dysplasia	Rocker bottom feet	Craniosynostosis	Congenital hip dysplasia	Congenital hip dysplasia	Congenital hip dysplasia	Broad, short hands	
Club feet	+	+	+	+	+	+	+	+	+	+	+	+	+	+	
Joint hypermobility	+	+	+	+	+	+	+	+	+	+	+	+	+	+	
Thin build	+	+	+	+	+	+	+	+	+	+	+	+	+	+	
Finger anomalies	Arachnodactyly	-	5th finger clinodactyly	5th finger clinodactyly	Arachnodactyly	-	5th finger clinodactyly	5th finger clinodactyly	Arachnodactyly	-	5th finger clinodactyly	5th finger clinodactyly	5th finger clinodactyly	Slender fingers	
Toe anomalies	-	-	Syndactyly	Syndactyly	-	-	Syndactyly	Syndactyly	-	-	-	-	-	-	
Cardiac anomalies	ASD; BAV	CCH	Megalenchaly	Megalenchaly	ASD; BAV	CCH	Megalenchaly	Megalenchaly	ASD; BAV	CCH	Megalenchaly	Megalenchaly	Megalenchaly	AIS	
Neurological anomalies	Hydrocephaly, MCM, CVH	+	Epileptogenic susceptibility on EEG	Epileptogenic susceptibility on EEG	Hydrocephaly, MCM, CVH	+	Epileptogenic susceptibility on EEG	Epileptogenic susceptibility on EEG	Hydrocephaly, MCM, CVH	+	Epileptogenic susceptibility on EEG	Epileptogenic susceptibility on EEG	Epileptogenic susceptibility on EEG	+	
Seizures	+	+	+	+	+	+	+	+	+	+	+	+	+	+	
Development delay	+	+	+	+	+	+	+	+	+	+	+	+	+	+	
Intellectual disability	+	+	+	+	+	+	+	+	+	+	+	+	+	+	
Hypotonia	-	-	-	-	-	-	-	-	-	-	-	-	-	-	

- = feature not present, + = feature present, AIS = aortic isthmus stenosis, ASD = atrial septum defect, BAV = bicuspid aortic valve, blank = insufficient data, CCH = corpus callosum hypoplasia, CLP = cleft lip and/or palate, CVH = cerebellar vermis hypoplasia, DS = downsisting, MCM = mega cisterna magna, SC = scoliosis, US = upslanting.

brachycephaly, upslanting palpebral fissures, hypotonia, development delay, and intellectual disability are present (Table 1). These features are among the most common clinical manifestations associated with various partial trisomies 21.<sup>[1]</sup> Such aberrations have also been commonly linked to congenital cardiac anomalies. Recently, it has been suggested that a more distal region of 21q22.2, harboring *DSCAM*, is associated with cardiac abnormalities.<sup>[23,24]</sup> *DSCAM* (DS cell adhesion molecule) has been reported as the most likely candidate gene to be responsible for CHDs in patients with DS due to its high expression in the embryonic heart.<sup>[24,25]</sup> Our patient III.3 carried a duplication on chromosome 21q22.2q22.3, which encompasses *DSCAM*. The lack of congenital heart disease in our patient III.3 supports an important but not essential role of *DSCAM* in DS-associated CHD. However, it is important to note that our patient not only has a partial trisomy 21 but also a partial monosomy 1; therefore, the patient's phenotype is likely to be the result of the combination and interaction between both aberrations.

Pure terminal deletions of chromosome 21 are quite rare and variable in phenotypic expression and severity, depending on the deletion size, breakpoint locations, and associated aberrations.<sup>[26]</sup> Cases previously described in the literature indicate similar findings in patients with 21q terminal deletions, including prominent forehead, hypertelorism, downslanting palpebral fissures, ear anomalies, including a closed ear canal, thin marfanoid build, cardiac defects, intellectual disability, and development delay<sup>[1,27,28]</sup> as present in our patient III.4 (Table 1). *TMPRSS3*, encoding a type II serine protease, is present in the deleted region 21q22.3. Studies of rodents showed that this gene is expressed in cochlear hair cells and plays a significant role for their proper function and development.<sup>[29,30]</sup> In humans, pathogenic variants of the gene have been identified to cause autosomal recessive nonsyndromic sensorineural hearing loss,<sup>[31]</sup> leading to loss of function of the encoded protein. Therefore, the deletion of this gene in our patient III.4 could be responsible for the phenotypic presentation of hearing impairment if a pathogenic variant is also present in the other allele of the gene.

In summary, the expressed phenotype of mirroring chromosomal aberrations in our patients supports the previous suggestion that the dosage effect of some of the genes included in deleted/duplicated regions may result in opposite phenotypes, such as macrocephaly in case of *AKT3* duplication and microcephaly in case of *AKT3* deletion. Although the lack of heart defect in our patient III.3 contradicts some of the previous studies suggesting the duplicated region is essential for heart defect development, it is important to note that it is likely to be affected by the combination of both rearrangements.

## Acknowledgments

We extend our sincere appreciation to patients family members for their enthusiastic support of this study.

## References

- Lyle R, Béna F, Gagos S, et al. Genotype–phenotype correlations in Down syndrome identified by array CGH in 30 cases of partial trisomy and partial monosomy chromosome 21. *Eur J Hum Genet* 2008;17:454–66.
- van Bon BWM, Koolen DA, Borgatti R, et al. Clinical and molecular characteristics of 1qter microdeletion syndrome: delineating a critical region for corpus callosum agenesis/hypogenesis. *J Med Genet* 2008;45:346–54.
- Balasubramanian M, Barber JCK, Collinson MN, et al. Inverted duplication of 1q32.1 to 1q44 characterized by array CGH and review of distal 1q partial trisomy. *Am J Med Genet* 2009;149A:793–7.
- Tuschl K, Fritz B, Herle M, et al. Trisomy 1q42.3-qter and monosomy 21q22.3-qter associated with ear anomaly, facial dysmorphism, psychomotor retardation, and epilepsy: delineation of a new syndrome. *Am J Med Genet* 2007;143A:2065–9.
- Colella S, Yau C, Taylor JM, et al. QuantiSNP: an objective Bayes Hidden–Markov model to detect and accurately map copy number variation using SNP genotyping data. *Nucl Acids Res* 2007;35:2013–25.
- Hiraki Y, Okamoto N, Ida T, et al. Two new cases of pure 1q terminal deletion presenting with brain malformations. *Am J Med Genet* 2008;146A:1241–7.
- Thierry G, Bénétou C, Pichon O, et al. Molecular characterization of 1q44 microdeletion in 11 patients reveals three candidate genes for intellectual disability and seizures. *Am J Med Genet* 2012;158A:1633–40.
- Boland E, Clayton-Smith J, Woo VG, et al. Mapping of deletion and translocation breakpoints in 1q44 implicates the serine/threonine kinase *AKT3* in postnatal microcephaly and agenesis of the corpus callosum. *Am J Hum Genet* 2007;81:292–303.
- Gai D, Haan E, Scholar M, et al. Phenotypes of *AKT3* deletion: a case report and literature review. *Am J Med Genet* 2014;167:174–9.
- Nakatani KEA, Sakaue H, Thompson DA, et al. Identification of a human *Akt3* (protein kinase B gamma) which contains the regulatory serine phosphorylation site. *Biochem Biophys Res Commun* 1999;257:906–10.
- Yang ZZ, Tschopp O, Di-Poi N, et al. Dosage-dependent effects of *Akt1*/protein kinase B (PKB) and *Akt3*/PKB on thymus, skin, and cardiovascular and nervous system development in mice. *Mol Cell Biol* 2005;25:10407–18.
- Wang D, Zeesman S, Tarnopolsky MA, et al. Duplication of *AKT3* as a cause of macrocephaly in duplication 1q43q44. *Am J Med Genet* 2013;161:2016–9.
- Caliebe A, Kroes HY, van der Smagt JJ, et al. Four patients with speech delay, seizures and variable corpus callosum thickness sharing a 0.440 Mb deletion in region 1q44 containing the *HNRPU* gene. *Eur J Med Genet* 2010;53:179–85.
- Nagamani SCS, Erez A, Bay C, et al. Delineation of a deletion region critical for corpus callosal abnormalities in chromosome 1q43-q44. *Eur J Hum Genet* 2011;20:176–9.
- Guernsey DL, Jiang H, Hussain J, et al. Mutations in centrosomal protein *CEP152* in primary microcephaly families linked to *MCPH4*. *Am J Hum Genet* 2010;87:40–51.
- Okado H, Ohtaka-Maruyama C, Sugitani Y, et al. The transcriptional repressor *RP58* is crucial for cell-division patterning and neuronal survival in the developing cortex. *Dev Biol* 2009;331:140–51.
- Concolino D, Cinti R, Ferraro L, et al. Partial trisomy 1(q42->qter): a new case with a mild phenotype. *J Med Genet* 1998;35:75–7.
- Cocché MC, Villa O, Obregon MG, et al. Duplication dup(1)(q41q44) defined by fluorescence in situ hybridization: delineation of the 'trisomy 1q42->qter syndrome'. *Cytogenet Genome Res* 2007;118:84–6.
- De Brasi D, Rossi E, Giglio S, et al. Inv dup del (1)(pter->q44::q44->q42:) with the classical phenotype of trisomy 1q42-qter. *Am J Med Genet* 2001;104:127–30.
- Polityko A, Starke H, Rumyantseva N, et al. Three cases with rare interstitial rearrangements of chromosome 1 characterized by multicolor banding. *Cytogenet Genome Res* 2005;111:171–4.
- Arron JR, Winslow MM, Polleri A, et al. NFAT dysregulation by increased dosage of *DSCR1* and *DYRK1A* on chromosome 21. *Nature* 2006;441:595–600.
- Deutsch S, Lyle R, Dermitzakis ET, et al. Gene expression variation and expression quantitative trait mapping of human chromosome 21 genes. *Hum Mol Genet* 2005;14:3741–9.
- Capkova P, Misovicova N, Vrbicka D. Partial trisomy and tetrasomy of chromosome 21 without Down syndrome phenotype and short overview of genotype-phenotype correlation. A case report. *Biomed Pap Med Fac Univ Palacky Olomouc Czech Repub* 2014;158:321–5.
- Weisfeld-Adams JD, Tkachuk AK, Maclean KN, et al. A de novo 2.78-Mb duplication on chromosome 21q22.11 implicates candidate genes in the partial trisomy 21 phenotype. *Genom Med* 2016;1:16003–5.
- Korbel JO, Tirosh-Wagner T, Urban AE, et al. The genetic architecture of Down syndrome phenotypes revealed by high-resolution analysis of human segmental trisomies. *Proc Natl Acad Sci U S A* 2009;106:12031–6.

- [26] Roberson EDO, Wohler ES, Hoover-Fong JE, et al. Genomic analysis of partial 21q monosomies with variable phenotypes. *Eur J Hum Genet* 2010;19:235–8.
- [27] Ehling D, Kennerknecht I, Junge A, et al. Mild phenotype in two unrelated patients with a partial deletion of 21q22.2-q22.3 defined by FISH and molecular studies. *Am J Med Genet* 2004;131A:265–372.
- [28] Miller AC, Rashid RM, Muraskas JK. A novel presentation of a rare chromosome 21q22.2 deletion. *Clin Dysmorphol* 2009;18:57–8.
- [29] Guipponi M, Toh M-Y, Tan J, et al. An integrated genetic and functional analysis of the role of type II transmembrane serine proteases (TMPRSSs) in hearing loss. *Hum Mutat* 2007;29:130–41.
- [30] Molina L, Fasquelle L, Nouvian R, et al. Tmprss3 loss of function impairs cochlear inner hair cell Kcna1 channel membrane expression. *Hum Mol Genet* 2013;22:1289–99.
- [31] Vozzi D, Morgan A, Vuckovic D, et al. Hereditary hearing loss: a 96 gene targeted sequencing protocol reveals novel alleles in a series of Italian and Qatari patients. *Gene* 2014;542:209–16.