Microinvasive, off-pump, transventricular neochordae implantation in recurrent mitral valve regurgitation after open heart surgical repair

Check for updates

Stefano Salizzoni, MD, PhD,[a] Rashmi Yadav, MD, PhD, FRCS,[b] Peyman Sardari Nia, MD, PhD,[c] Corey Adams, MD,[d] Florinda Mastro, MD,[e] Cristina Barbero, MD, PhD,[f] Alessandro D'Alfonso, MD,[g] Javier Cobiella, MD,[h] Agne Drasutiene, MD,[i] Minoru Tabata, MD, PhD, MPH,[j] Carlo Savini, MD,[k] Alberto Albertini, MD,[l] Simone Mureddu, MD,[m] Laura Besola, MD,[n] Paolo Centofanti, MD,[o] Igor Vendramin, MD,[p] Ishtiaq Ahmed, MD,[q] Fritz Mellert, MD,[r] Jeno Szolnoky, MD,[s] Peter Benedikt, MD,[t] Meindert Palmen, MD, PhD,[u] Dina De Bock, MD,[v] Vasilis Lozos, MD, MSc, PhD,[w] Ryuta Seguchi, MD,[x] Krzysztof Wrobel, MD,[y] Ignasi Julià Amill, MD,[z] Massimo Serra, MD,[aa] Paolo Magagna, MD,[bb] Antonella Meraglia, MD,[cc] Max Baghai, MD, PhD, FRCS,[dd] Claudia Filippini, BS,[ee] Alessandro Vairo, MD,[ff] Chiao Po Hsu, MD,[gg] Ferdinand Vogt, MD,[hh] Yeong-Hoon Choi, MD,[ii] Giovanni Speziali, MD,[jj] Luca Aerts, MD,[c] Sumant Luhana, MD,[b] Anastasia Vamvakidou, MD,[b] William Kent, MD,[d] Amy N. Brown, MD, MSc, MPH,[d] Marco Di Eusanio, MD,[g] Gino Gerosa, MD,[e] and Mauro Rinaldi, MD, PhD[a]

ABSTRACT

Objective: Mitral valve repair (MVr) is the standard treatment for degenerative mitral regurgitation (MR). However, MR may recur, and reoperation is associated with increased mortality and technical complexity. Microinvasive MVr using the NeoChord technique in redo setting is performed off-pump, offering clear advantages, particularly in high-risk patients.

Methods: This retrospective, multicenter, international registry included 92 patients treated with the NeoChord technique between 2014 and 2025 for recurrent MR after previous MVr across 32 centers. The primary composite end point was freedom from recurrence of severe MR, need for reintervention due to technical failure, and 30-day or cardiovascular mortality.

Results: Neochord repair was successful in 91 patients (98.9%); one was converted to open surgery. Mean age was 64.6 ± 11.6; 22 patients (23.9%) were female. Mean left ventricle ejection fraction was 57.4 ± 8.1%; European System for Cardiac Operative Risk Evaluation was 4.3 ± 3.2%. A median of 3 chords was implanted. Mean procedural time was 139 ± 65 minutes. At discharge, MR was mild or less in 93.5%. One patient (1.1%) died on day 8. One life-threatening bleeding and one acute myocardial infarction were reported. Median hospital length-of-stay was 5 days; 47.8% of patients were extubated in the operating room. The primary end point was achieved in 81.3 ± 6.6% of patients at 5 years (Kaplan-Meier analysis). Seven patients (8.6%) underwent re-reintervention; 3 remained with severe MR. In the multivariate analysis, older age was associated with an increased risk (hazard ratio, 1.160; 95% CI, 1.021-1.317), whereas greater hemoglobin levels were protective (hazard ratio, 0.423; 95% CI, 0.233-0.768).

Conclusions: Microinvasive NeoChord repair provides excellent procedural and 5-year outcomes with very low mortality, supporting its role as a valuable option for reoperative mitral valve surgery. (J Thorac Cardiovasc Surg 2026;172:308-16)

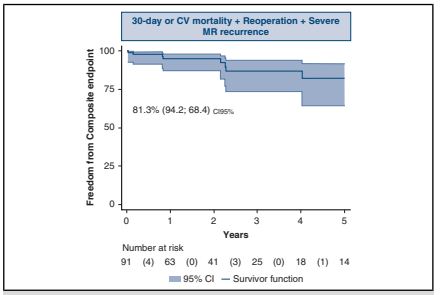

Five-year KM curve for composite end point: severe MR, reintervention, 30-day mortality.

CENTRAL MESSAGE

NeoChord repair offers a safe, physiological, and microinvasive option for re-repair of recurrent MR after prior MV surgery, avoiding cardiopulmonary bypass and preserving future treatment pathways.

PERSPECTIVE

This international multicenter registry demonstrates that transventricular microinvasive NeoChord repair is a safe and effective option for selected patients with recurrent MR after surgical repair. The off-pump, physiology-preserving approach avoids cardiopulmonary bypass, sternotomy and maintains future treatment options, offering distinct advantages over conventional or transcatheter alternatives.

See Commentary on page 317.

Downloaded for Anonymous User (n/a) at Vilnius University from ClinicalKey.com by Elsevier on October 20, 2026.
For personal use only. No other uses without permission. Copyright ©2026. Elsevier Inc. All rights reserved.

Abbreviations and Acronyms

HR = hazard ratio
ICU = intensive care unit
MR = mitral regurgitation
MV = mitral valve
MVr = mitral valve repair
TEE = transesophageal echocardiography
TEER = transcatheter edge-to-edge repair

To view the AATS Annual Meeting Webcast, see the URL next to the webcast thumbnail.

Surgical mitral valve repair (MVr) is the gold standard treatment for degenerative mitral regurgitation (MR) caused by leaflet prolapse, offering superior outcomes compared with valve replacement in terms of survival, preservation of ventricular function, and freedom from anticoagulation, even in elderly patients.[1-3] Nevertheless, MVr is not immune to failure, with recurrence of MR reported in up to 20% of patients over time, depending on anatomical complexity, surgical technique, and disease progression.[4-6]

Reoperation for failed MVr carries the risk of significant operative mortality, up to 12.5%, and major morbidity, as reported in a large European multicenter registry.[7] Re-sternotomy carries inherent risks, including cardiac or great vessel injury, bleeding, and longer operative times.[8] Moreover, re-repair is often technically complex because of scarring, altered anatomy, and the presence of prosthetic material. Consequently, many patients undergo mitral valve (MV) replacement at reoperation, even in the absence of contraindications to repair.[9]

In recent years, microinvasive MVr using the NeoChord system (NeoChord, Inc) has emerged as an alternative to open surgery in selected patients with leaflet prolapse and preserved annular geometry.[10-14] This technique, performed via a transventricular off-pump approach under transesophageal echocardiographic (TEE) guidance, has shown favorable outcomes in both primary and selected redo settings.[15-17] In patients with recurrent MR after previous MVr, neochord implantation may offer several advantages: avoidance of cardiopulmonary bypass, sternotomy, or resternotomy; reduced procedural invasiveness; and preservation of mitral apparatus.

To date, limited data exist on the application of neochords in the redo setting after failed surgical MVr.[15] Here, we present the largest international, multicenter experience to date, evaluating the safety, feasibility, and midterm outcomes of microinvasive neochord re-repair in this challenging patient population.

METHODS

Study Design and Population

This retrospective registry included patients from 32 centers across Europe, North America, and Asia (Table 1).

From the [a]Department of Cardiovascular and Thoracic Surgery, University of Turin, Turin, Italy; [b]Royal Brompton Hospital, Guy's and St Thomas' NHS Foundation Trust, London, United Kingdom; [c]Department of Cardiothoracic Surgery, Maastricht University Medical Centre, Maastricht, The Netherlands; [d]Section of Cardiac Surgery, Department of Cardiac Sciences, Libin Cardiovascular Institute, University of Calgary, Calgary, Alberta, Canada; [e]Cardiac Surgery Division, Cardio-Thoraco-Vascular and Public Health Department, University of Padova, Padova, Italy; [f]Division of Cardiac Surgery - Città della Salute e della Scienza, Turin, Italy; [g]Cardiac Surgery Unit, Lancisi Cardiovascular Center, Polytechnic University of Marche, Ancona, Italy; [h]Cardiac Surgery, Hospital Ruber Internacional, Madrid, Spain; [i]Vilnius University Faculty of Medicine, Clinic of Cardiac and Vascular Diseases, Vilnius, Lithuania; [j]Department of Cardiovascular Surgery, Juntendo University School of Medicine, Tokyo, Japan; [k]Division of Cardiac Surgery, Cardio-Vascular Surgery Department, Maria Cecilia Hospital, GVM Care & Research, Cotignola, Italy; [l]Division of Cardiac Surgery, Salus Hospital, GVM Care & Research, Reggio Emilia, Italy; [m]Departement of Cardiothoracic and Vascular Surgery, Cardiac Surgery Unit, A.O.U. Sassari, Sassari, Italy; [n]Department of Surgical, Medical and Molecular Pathology and Critical Care Medicine, University of Pisa, Pisa, Italy; [o]Structural Surgical Departement, Azienda Ospedaliera Ordine Mauriziano di Torino, Turin, Italy; [p]Cardiothoracic Department, Department of Medicine, Azienda Sanitaria Universitaria Friuli Centrale, Udine, Italy; [q]Cardiac Surgery Divion, Royal Sussex County Hospital, Brighton, East Sussex, United Kingdom; [r]Department of Cardiac Surgery, University Hospital Erlangen, University of Erlangen-Nuremberg, Erlangen, Germany; [s]Department of Cardiac Surgery, Gottsegen National Cardiovascular Center, Budapest, Hungary; [t]Department of Cardio-Vascular and Thoracic Surgery, Kepler University Hospital-Faculty of Medicine, Johannes Kepler University, Linz, Austria; [u]Cardiothoracic Surgery, Leiden University Medical Centre, Leiden, The Netherlands; [v]Department of Cardiac Surgery, Antwerp University Hospital, Edegem, Belgium; [w]Department of Cardiothoracic Surgery, Ippokrateion General Hospital, Athens, Greece; [x]Department of Cardiovascular Surgery, NewHeart Watanabe Institute, Tokyo, Japan; [y]Department of Cardiac Surgery, Medicover Hospital, Lazarski University, Warszawa, Poland; [z]Cardiac Surgery Department Heart Institut Institution Hospital Universitari Germans Trias i Pujol, Badalona, Barcelona, Spain; [aa]Structural Cardio-Thoraco-Vascular Department, University Hospital SS. Antonio e Biagio e C. Arrigo, Alessandria, Italy; [bb]Cardiovascular Department, ULSS 3, Serenissima Venice, Italy; [cc]Cardiothoracic Services, New Cross Hospital, Royal Wolverhampton Trust, Wolverhampton, United Kingdom; [dd]Cardiothoracic Surgery, King's College Hospital NHS Foundation Trust, London, United Kingdom; [ee]Division of Cardiac Intensive Care, Anesthesia, Intensive Care and Emergency Department - Città della Salute e della Scienza, Turin, Italy; [ff]Division of Cardiology - Città della Salute e della Scienza, Turin, Italy; [gg]Division of Cardiovascular Surgery, Department of Surgery, Taipei Veterans General Hospital, Taipei, Taiwan; [hh]Department of Cardiac Surgery, Paracelsus Medical University, Nuremberg, Germany; [ii]Department of Cardiac Surgery, Kerckhoff Heart Center, Bad Nauheim, Germany; and [jj]Mercy Hospital, St Louis, Mo.

Read at the 105th Annual Meeting of The American Association for Thoracic Surgery, Seattle, Washington, May 2-5, 2025.

Received for publication Aug 4, 2025; revisions received Jan 12, 2026; accepted for publication Jan 30, 2026; available ahead of print Feb 26, 2026.

Address for reprints: Stefano Salizzoni, MD, PhD, Department of Surgical Sciences, University of Turin, Corso Dogliotti 14, Torino 10126, Italy (E-mail: stefano.salizzoni@unito.it).

0022-5223

Copyright © 2026 The Authors. Published by Elsevier Inc. on behalf of The American Association for Thoracic Surgery. This is an open access article under the CC BY license (http://creativecommons.org/licenses/by/4.0/).

https://doi.org/10.1016/j.jtcvs.2026.01.036

Downloaded for Anonymous User (n/a) at Vilnius University from ClinicalKey.com by Elsevier on October 20, 2026.
For personal use only. No other uses without permission. Copyright ©2026. Elsevier Inc. All rights reserved.

From 2014 to 2025, 93 patients with severe recurrent MR after previous surgical MVr with ring underwent microinvasive MV re-repair using the NeoChord system. One patient was excluded from the analysis as the result of intraoperative abortion of the procedure because of left ventricle frailty.

All patients had previously undergone MVr with a prosthetic ring for degenerative disease. Recurrence was defined as symptomatic or echocardiographic evidence of severe MR as the result of leaflet prolapse or flail, confirmed by TEE.

Patient selection for the NeoChord procedure was made through a multidisciplinary team evaluation, considering anatomical suitability (Carpentier type II), clinical risk profile, and institutional experience.[10,16,18,19]

Anatomical Classification

Patients were classified anatomically on the basis of the following prolapsing segments[20]:

- type A: isolated P2 prolapse or flail;
- type B: isolated non-P2 or multisegment posterior prolapse (eg, P1-P2, P3 alone); and
- type C: anterior or bileaflet prolapse.

Procedure

The NeoChord procedure was performed via a left minithoracotomy in the fifth or sixth intercostal space. Under continuous 2-dimensional and 3-dimensional

TABLE 1. Number of patients treated per participating center

No.	Center name	City	Country	No. patients
1	University of Turin	Torino	Italy	15
2	Royal Brompton Hospital	London	United Kingdom	12
3	Maastricht University Medical Centre	Maastricht	Netherlands	7
4	Libin Cardiovascular Institute	Calgary	Canada	7
5	University of Padova	Padova	Italy	5
6	Kerckhoff Heart Center	Bad Nauheim	Germany	5
7	Hospital Ruber Internacional	Madrid	Spain	4
8	Lancisi Cardiovascular Center	Ancona	Italy	3
9	Vilnius University	Vilnius	Lithuania	2
10	Juntendo University	Tokyo	Japan	2
11	Maria Cecilia Hospital	Cotignola	Italy	2
12	Hesperia Hospital	Modena	Italy	2
13	University of Pisa	Pisa	Italy	2
14	A.O.U. Sassari	Sassari	Italy	2
15	Royal Sussex County Hospital	Brighton	United Kingdom	2
16	University of Erlangen-Nuremberg	Erlangen	Germany	2
17	A.S.U. Friuli Centrale	Udine	Italy	2
18	A.O. Ordine Mauriziano	Torino	Italy	2
19	Taipei Veterans General Hospital	Taipei	Taiwan	2
20	Gottsegen National Center	Budapest	Hungary	1
21	Kepler University Hospital	Linz	Austria	1
22	Antwerp University Hospital	Antwerpen	Belgium	1
23	Ippokrateion General Hospital	Athens	Greece	1
24	NewHeart Watanabe Institute	Tokyo	Japan	1
25	University Medical Center	Leiden	Netherlands	1
26	Medicover Hospital, Lazarski University	Warsaw	Poland	1
27	Hospital Universitari Germans Trias i Pujol	Barcelona	Spain	1
28	New Cross Hospital	Wolverhampton	United Kingdom	1
29	King's College	London	United Kingdom	1
30	University Hospital S Antonio e Biagio	Alessandria	Italy	1
31	San Bortolo Hospital	Vicenza	Italy	1
32	Artemed Clinic Munich South	München	Germany	1

Downloaded for Anonymous User (n/a) at Vilnius University from ClinicalKey.com by Elsevier on October 20, 2026.
For personal use only. No other uses without permission. Copyright ©2026. Elsevier Inc. All rights reserved.

TEE guidance, transventricular access to the left ventricle was obtained. The NeoChord DS1000 device was used to deploy at least 2 artificial 4/0 polytetrafluoroethylene chords on the prolapsing segment(s). Chords were individually tensioned under TEE control to restore leaflet coaptation and anchored epicardially with a pledget.[19,21-23] A schematic representation of the transventricular NeoChord implantation technique is shown in Figure 1.

Procedural success was defined as successful implantation of neochords with less than moderate residual MR at the conclusion of the procedure. In cases of technical failure or unsatisfactory result, conversion to open surgery was permitted at the surgeon's discretion.

All patients provided written informed consent before the procedure. The study was approved by the Biomedical Research Ethics Committee of Città della Salute e della Scienza di Torino – A.O. Ordine Mauriziano – A.S.L. Città di Torino (approval date: October 19, 2022; protocol number: 0001455) and conducted in accordance with the ethical principles outlined in the Declaration of Helsinki.

End Points and Definitions

The primary composite end point included the following components:

- freedom from recurrence of severe MR due to technical failure (excluding cases of endocarditis occurring more than 1 year postprocedure);
- freedom from MV reintervention related to the index technique; and
- freedom from all-cause 30-day or cardiovascular mortality, regardless of valve competence.

Secondary outcomes included mechanical ventilation time, intensive care unit (ICU) and hospital length-of-stay, postoperative complication per Mitral Valve Academic Research Consortium definitions,[24] and recurrence of moderate MR at follow-up.

Patients were followed through clinic visits and/or telephone interviews. MR severity was graded as none/trace, mild, moderate, or severe using integrative criteria in accordance with American Society of Echocardiography guidelines.[25]

Statistical Analysis

Continuous variables are expressed as mean ± standard deviation or median and range, as appropriate. Categorical variables are reported as absolute counts and percentages. The Kaplan-Meier analysis was used to estimate time-to-event outcomes, including survival and composite failure-free status.

To investigate the potential factors associated with the composite end point, Cox proportional risks model and estimating the hazard ratio (HR) and its 95% CI was performed. The level of statistical significance was set at .05; all tests were 2-tailed. Statistical analyses were performed using SAS 9.4 for Windows (SAS Institute Inc).

RESULTS

Preoperative Characteristics

A total of 92 patients who underwent NeoChord repair for recurrent MR after previous MVr were included in the final analysis. The mean age was 64.6 ± 11.6 years, and 22 patients (23.9%) were female. The mean left ventricular ejection fraction was 57.4 ± 8.1%, and the mean European System for Cardiac Operative Risk Evaluation II was 4.3 ± 3.2%. Preoperative New York Heart Association class was I in 17.4%, II in 43.5%, III in 35.9%, and IV in 3.3% of patients. Pre-existing atrial fibrillation was present in 20.7% of cases.

Previous MVr techniques included artificial chordae implantation in 72 patients (78.3%), leaflet resection in 13 (14.1%), a combination of both in 4 (4.4%), and isolated annuloplasty in 3 patients (3.3%). The predominant anatomical mechanism underlying recurrent MR was isolated P2 prolapse (type A, 69.6%), followed by more complex posterior leaflet involvement beyond P2 (type B, 27.2%), and anterior or bileaflet prolapse (type C, 3.3%). A complete summary of preoperative characteristics is provided in Table 2.

Operative and Early Postoperative Outcomes

NeoChord implantation was technically successful in 91 patients (98.9%); 1 patient was converted intraoperatively to open surgery because of unsatisfactory valve competence. At valve inspection a P1-P2 cleft was highlighted, underestimated at pre- and intraoperative TEE. The mean operative time was 139.3 ± 65.0 minutes, with a median of 3 [interquartile range, 3-3] artificial chordae implanted (minimum of 2 and maximum of 6). At the end of the procedure, MR was absent or trace in 65.2%, mild in 28.3%, moderate in 5.4%, and severe in the converted patient.

Perioperative complications according to Mitral Valve Academic Research Consortium criteria were rare: 30-day mortality occurred in 1 patient, labeled compassionate use (1.1%), on day 8 from cardiorespiratory arrest; intraoperative conversion, life-threatening bleeding, and myocardial infarction occurred in 1 case each (1.1%). There were no strokes or cases of acute kidney injury. Postoperative atrial fibrillation occurred in 4 patients (4.4%), and permanent pacemaker implantation was required in 1 case (1.1%). Forty-four (47.8%) patients were extubated immediately

Downloaded for Anonymous User (n/a) at Vilnius University from ClinicalKey.com by Elsevier on October 20, 2026.
For personal use only. No other uses without permission. Copyright ©2026. Elsevier Inc. All rights reserved.

TABLE 2. Patients' preoperative characteristics and echocardiographic data

Characteristics	Total, n = 92	CE yes, n = 81	CE no, n = 11	*P* value
Age, y, mean ± SD	64.6 ± 11.6	64.1 ± 11.7	67.8 ± 10.5	.287
Female, n (%)	22 (23.9)	21 (25.9)	1 (9.1)	.287
BMI, kg/m^2, mean ± SD	24.8 ± 3.3	24.7 ± 3.4	25.9 ± 2.1	.163
Atrial fibrillation, n (%)	19 (20.7)	18 (22.2)	1 (9.1)	.090
Chronic lung disease*	6 (6.5)	6 (7.4)	0	>.999
Dialysis, n (%)	1 (1.1)	1 (1.2)	0	>.999
Creatinine, mg/dL, mean ± SD	1.0 ± 0.6	1.0 ± 0.6	1.0 ± 0.4	.727
eGFR, mL/min/1.73 m^2, mean ± SD	80.9 ± 27.0	80.2 ± 26.6	85.8 ± 31.1	.578
Hemoglobin, g/dL, n (%)	12.9 ± 2.2	13.1 ± 2.1	11.3 ± 2.4	**.017**
Extracardiac arteriopathy,* n (%)	5 (5.4)	5 (6.2)	0	>.999
Poor mobility,* n (%)	3 (3.3)	2 (2.5)	1 (9.1)	.321
EuroSCORE II, %, n (%)	4.3 ± 3.2	4.3 ± 3.3	4.2 ± 2.4	.463
Months from prior MVr to NeoChord reintervention, median (IRQ)	48 (22-63)	45 (20-63)	26 (22-55)	.791
Associated surgery to MVr, n (%)	19 (20.7)	17 (20.1)	2 (18.2)	>.999
Previous surgical access, n (%)				**.018**
Median sternotomy	44 (47.8)	36 (44.4)	8 (72.7)	
Right minithoracotmy†	41 (44.6)	40 (49.4)	1 (9.1)	
Robotic†	7 (7.6)	5 (6.2)	2 (18.2)	
Previous MVr technique, n (%)				.531
Chords	72 (78.3)	63 (77.9)	9 (81.8)	
Resection	13 (14.1)	12 (14.8)	1 (9.1)	
Chords and resection	4 (4.4)	4 (4.9)	0	
Annuloplasty alone	3 (3.3)	2 (2.5)	1 (9.1)	
Complete ring, n (%)	78 (84.8)	70 (87.5)	8 (72.3)	.879
Ring size, mm, mean ± SD	35.6 ± 2.9	35.6 ± 3.0	35.8 ± 3.0	.879
Colli classification, n (%)				.357
Type A	64 (69.6)	58 (71.6)	6 (54.6)	
Type B	25 (27.2)	20 (24.7)	5 (45.5)	
Type C	3 (3.3)	3 (3.7)	0	
NYHA, n (%)				.128
I	16 (17.4)	16 (19.8)	0	
II	40 (43.5)	36 (44.4)	4 (36.4)	
III	33 (35.9)	27 (33.3)	6 (54.6)	
IV	3 (3.3)	2 (2.5)	1 (9.1)	
LVEF, %, mean ± SD	57.4 ± 8.1	57.5 ± 7.9	56.5 ± 10.0	.734
sPAP, mm Hg, mean ± SD	34.3 ± 12.0	34.1 ± 11.7	35.1 ± 14.2	.861
Moderate or greater TV regurgitation, n (%)	20 (21.7)	16 (19.8)	4 (36.4)	.195

Bolded *P* values indicate statistical significance. *CE*, Composite end point; *SD*, standard deviation; *BMI*, body mass index; *eGFR*, estimated glomerular filtration rate; *EuroSCORE*, European System for Cardiac Operative Risk Evaluation; *MVr*, mitral valve repair; *NYHA*, New York Heart Association; *LVEDV*, left ventricle end-diastolic volume; *LVEF*, left ventricle ejection fraction; *sPAP*, systolic pulmonary artery pressure; *TV*, tricuspid valve. *EuroSCORE definition. †For the Cox model, the 2 techniques were merged.

at the end of the procedure, and 11.9% avoided admission to the ICU entirely. Median ICU stay was 20 hours, and median hospital length-of-stay was 5 days [interquartile range, 4-6]. Most patients (92.4%) were discharged directly home; the remainder were transferred to rehabilitation facilities. The complete summary of operative data and perioperative outcomes is provided in Table 3. Center volume (≥5 vs ≤4 cases) was analyzed as a potential predictor of failure, with no significant differences observed in clinical or composite outcomes between groups.

Follow-up Outcomes

At a median follow-up of 681 days (range, 31 days to 11 years), 7 patients (7.7%) required reoperation: 6 for

Downloaded for Anonymous User (n/a) at Vilnius University from ClinicalKey.com by Elsevier on October 20, 2026.
For personal use only. No other uses without permission. Copyright ©2026. Elsevier Inc. All rights reserved.

TABLE 3. Operative data and perioperative outcomes

Characteristics	Total, n = 92	CE yes, n = 81	CE no, n = 11	*P* value
Overall surgical time, min, mean ± SD	139.3 ± 65.0	137.6 ± 58.1	151.4 ± 106.2	.904
No. released chords, median [IQR]	3 [3-3]	3 [3-3]	3 [3-4]	.478
End-procedure MV regurgitation, n (%)				.091
No/trace	60 (65.2)	55 (67.9)	5 (45.5)	
Mild	26 (28.3)	22 (27.2)	4 (36.4)	
Moderate	5 (5.4)	4 (4.9)	1 (9.1)	
Severe	1 (1.1)	0	1 (9.1)	
MVARC overall (no. of patients), n (%)	4 (4.3)	2 (2.5)	2 (18.2)	.107
30-d mortality	1 (1.1)	0	1 (9.1)	
Intraoperative conversion	1 (1.1)	0	1 (9.1)	
Life-threatening bleeding	1 (1.1)	1 (1.2)	0	
Acute myocardial infarction	1 (1.1)	1 (1.2)	0	
Mechanical ventilation time, h	0 [0-4]	0 [0-4]	0 [0-2]	.664
No need of ICU, n (%)	11 (11.9)	10 (12.3)	1 (9.1)	
ICU stay, h, median [IQR]	20 [13-24]	20 [12-24]	23 [15-24]	.510
Permanent pace-maker, n (%)	1 (1.1)	1 (1.2)	0	>.999
Postoperative atrial fibrillation, n (%)	4 (4.4)	3 (3.7)	1 (9.1)	.405
Hospital length of stay, d	5 [4-6]	4 [4-6]	5 [4-7]	.492
Discharge to home, n (%)	85 (92.4)	75 (92.6)	10 (90.9)	.139

CE, Composite end point; *SD*, standard deviation; *IQR*, interquartile range; *MV*, mitral valve; *MVARC*, Mitral Valve Academic Research Consortium; *ICU*, intensive care unit.

recurrent severe MR and 1 for infective endocarditis. All underwent successful MV replacement.

On the remaining 84 patients MR severity was mild or less in 81% (no/trace in 41.7%, mild in 39.3%), moderate in 16.7%, and severe in 3.6%. The latter were not reoperated due to age or comorbidities. At follow-up left ventricular ejection fraction was 56.1 ± 8.0% and the mean systolic pulmonary artery pressure was 27.7 ± 10.1 mm Hg. Moderate tricuspid regurgitation was present in 7.7% of patients. Table 4 provides the echocardiographic data at follow-up.

Kaplan-Meier analysis demonstrated that freedom from the primary composite end point—defined as recurrence of severe MR and need for reintervention due to technical failure, or 30-day or cardiovascular mortality—was 81.3 ± 6.6% at 5 years (Figure 1).

In the multivariable Cox regression analysis, which included age, gender, preoperative hemoglobin, moderate or greater tricuspid regurgitation, time from first MVr, previous surgical access (sternotomy vs right minithoracotomy), body mass index, ring type (complete vs incomplete), anatomical classification, and concomitant procedures at the index MVr, only age and hemoglobin were statistically significant predictors of failure. Older age was associated with an increased risk (HR, 1.160; 95% CI, 1.021-1.317), whereas greater hemoglobin levels were protective (HR, 0.423; 95% CI, 0.233-0.768).

TABLE 4. Echocardiographic data at follow-up

Characteristics	n = 84
MV regurgitation, n (%)	
No/trace	35 (41.7)
Mild	33 (39.3)
Moderate	14 (16.7)
Severe	3 (3.6)
LVEF, %, mean ± SD	56.1 ± 8.0
sPAP, mm Hg, mean ± SD	27.7 ± 10.1
Moderate or greater TV regurgitation, n (%)	7 (8.3)
Mitral mean transvalvular gradient, mm Hg, mean ± SD	2.5 ± 0.9

MV, Mitral valve; *LVEF*, left ventricular ejection fraction; *SD*, standard deviation; *sPAP*, systolic pulmonary artery pressure; *TV*, tricuspid valve.

DISCUSSION

Reoperation for recurrent MR after previous repair remains a significant surgical challenge.[2,3] Conventional reintervention is associated with increased perioperative risk and a relatively low likelihood of successful re-repair. In many cases, particularly among older patients or those with significant comorbidities, surgeons may prefer MV replacement rather than risk a second failure or the need for intraoperative reclamping. As a result, despite the physiological benefits of MV preservation, re-repair rates remain low in the reoperative setting.[26]

The microinvasive,[27] off-pump, NeoChord procedure offers a unique solution to this clinical dilemma. Performed through a left minithoracotomy without the need for cardiopulmonary bypass and sternotomy (or resternotomy),

Downloaded for Anonymous User (n/a) at Vilnius University from ClinicalKey.com by Elsevier on October 20, 2026.
For personal use only. No other uses without permission. Copyright ©2026. Elsevier Inc. All rights reserved.

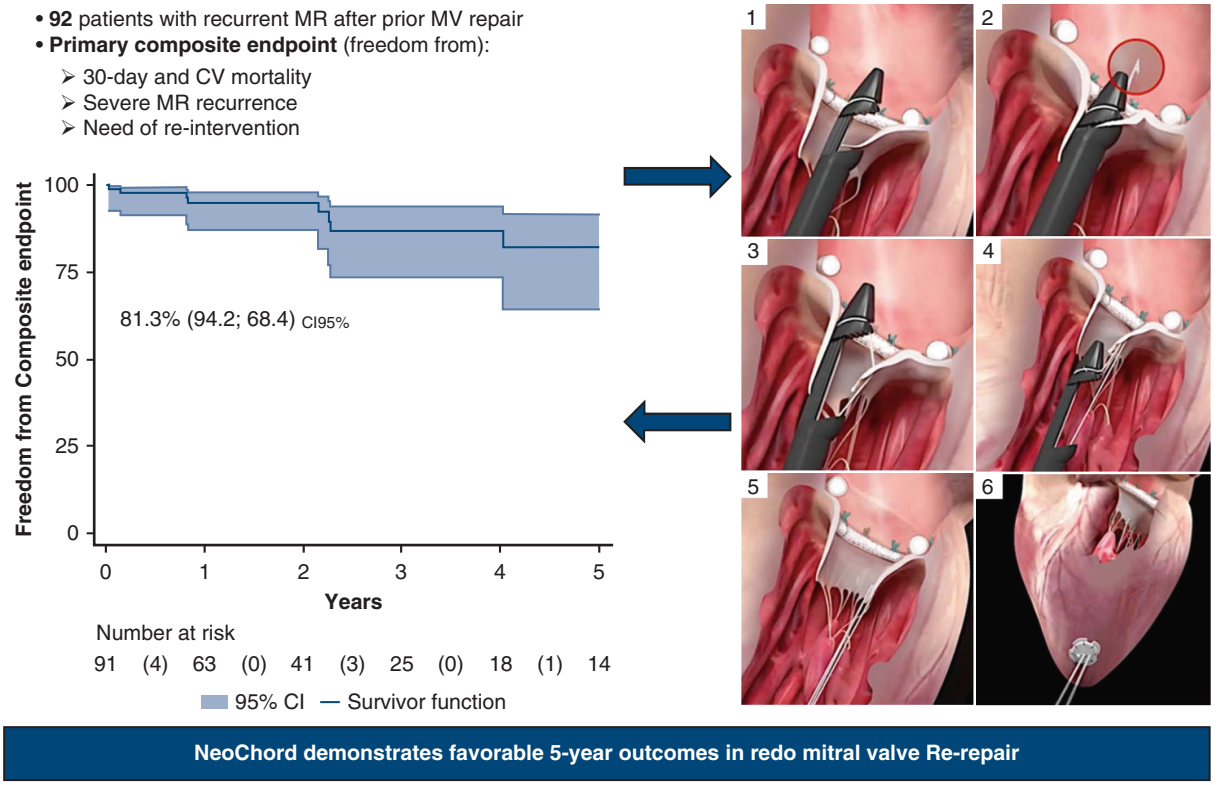

FIGURE 1. Five-year Kaplan-Meier curve for composite end point: severe mitral regurgitation, reintervention, 30-day or cardiovascular (*CV*) mortality.

it significantly reduces the complexity and risk of reintervention. This microinvasive approach facilitates both surgeon indication and patient acceptance—particularly when MR recurrence occurs early after index surgery— by offering a less-invasive, physiological option within a shared decision-making framework. Importantly, neochord implantation preserves future surgical access: patients with a previous right minithoracotomy remain eligible for first-time sternotomy, whereas those with a previous sternotomy can still undergo right minithoracotomy using an endoclamp.[28] Therefore, the NeoChord approach does not limit other future therapeutic options.

In this anatomical setting, alternative transcatheter strategies are currently less favorable. Transcatheter edge-to-edge repair (TEER), although well-established, carries a substantial risk of MV stenosis when a previous annuloplasty ring is present, often rendering patients ineligible.[29,30] In a dedicated series by Rahhab and colleagues,[29] MitraClip implantation was feasible in 92% of patients after previous surgical repair; however, in the remaining 8%, the procedure was abandoned because of the development of unacceptably high MV gradients in 5 cases. Moreover, even in successfully treated patients, the mean postprocedural transmitral gradient increased to 4.7 mm Hg compared with a preprocedural value of 3.0 mm Hg. Moreover, similar findings were reported in the GISE Registry of Transcatheter Treatment of Mitral Valve Regurgitation-FAILureS (GIOTTO-FAILS) trial, where 40 patients undergoing TEER after failed surgical MV repair showed a mean postprocedural transmitral gradient of 4.8 mm Hg, with an average increase of 2.1 mm Hg compared with baseline.[30] This contrasts with the present cohort, in which mean MV gradients at follow-up remained low (mean of 2.5 mm Hg), reflecting the fact that transventricular neochord implantation does not impair diastolic valve opening but rather corrects leaflet prolapse while preserving MV physiology. Even when TEER is feasible, outcomes are frequently suboptimal and may preclude future transcatheter therapies—unless technically demanding procedures such as LAMPOON are used.[31,32] Transcatheter mitral valve implantation is also limited by a high exclusion rate due to the risk of left ventricular outflow tract obstruction.[33] Even in anatomically favorable cases, transcatheter mitral valve implantation introduces the limitations of bioprosthetic valves, particularly in younger patients and clinically relevant, increased risk of transcatheter heart valve thrombosis and need for anticoagulation.[34] In contrast, the NeoChord technique restores native leaflet function while preserving MV physiology, representing the most anatomical and conservative solution in appropriately selected patients.[35] Although potentially less invasive, transseptal neochord repair is anatomically limited, not commercially available, and supported only by early feasibility data without midterm outcomes.[36] In

Downloaded for Anonymous User (n/a) at Vilnius University from ClinicalKey.com by Elsevier on October 20, 2026.
For personal use only. No other uses without permission. Copyright ©2026. Elsevier Inc. All rights reserved.

contrast, the transventricular approach provides more consistent and predictable chordal anchoring and therefore remains the most reliable option at present.

This study demonstrates the feasibility and safety of this strategy in the largest international cohort to date. The procedure was associated with extremely low in hospital mortality (1.1%), limited to a single compassionate-use case, and an excellent discharge profile: nearly all patients were extubated early, most avoided prolonged ICU stay, and the vast majority were discharged home. At a median follow-up of nearly 2 years, 90% of the 90 patients discharged alive after a successful procedure remained free from technical failure—defined as severe MR, reintervention (excluding endocarditis), or death related to the procedure—supporting the midterm durability of this approach in experienced centers.

The results of this study are consistent with those reported by Gerosa and colleagues,[15] who demonstrated the feasibility of neochord re-repair in 15 patients with recurrent MR after failed surgical repair. In that multicenter series, no in-hospital mortality occurred, mild or less MR was achieved in 86.7% at discharge, and patient success was 92.3% and 83.9% at 1 and 2 years, respectively. Recently, Barbero and colleagues[37] reported a comparative analysis of redo MV interventions, including 15 patients treated with neochord re-repair, demonstrating 100% technical success, no 30-day mortality, and favorable 1-year outcomes comparable with on-pump surgery, with significantly faster recovery. These data confirm the favorable safety profile and demonstrate the mid- to long-term durability of transventricular off-pump MV re-repair with the NeoChord system.

Importantly, the transventricular access used in the NeoChord repair avoids additional adhesions and leaves both the sternum and right hemithorax untouched. This strategic advantage is particularly relevant for younger patients or those likely to require future other cardiac interventions.

To explore risk factors for procedural failure, we performed a multivariable Cox regression analysis and only increasing age and lower preoperative hemoglobin emerged as significant predictors of the composite end point. These findings likely reflect underlying patient frailty, because both variables are known markers of reduced physiological reserve. Notably, no anatomical or technical factors were associated with failure in this model.

Although these outcomes are encouraging, recurrence of MR after transventricular neochord implantation remains a relevant issue. In this multicentric experience, most failures are probably related to the surgical and echocardiographic learning curves. Specifically, misinterpretation of TEE imaging or suboptimal final chordal tensioning—particularly the lack of slight overtensioning—may contribute to residual or recurrent MR. With increased operator experience and better procedural standardization, these failures are expected to decrease over time.

Study Limitations

This study has several limitations. First, despite being the largest series to date, the overall sample size remains modest, which limits the statistical power to detect predictors of outcome. Second, the cohort spans an 11-year period, during which surgical and echocardiographic techniques, as well as patient selection criteria, likely evolved. Third, there was center-level variability in patient volume and procedural experience, which could influence outcomes. Nevertheless, the multicenter design reflects real-world practice and highlights the broad applicability of the technique across diverse settings.

CONCLUSIONS

In this international multicenter experience, microinvasive transventricular neochord re-repair was safe and effective for recurrent MR after previous surgical repair, with high procedural success, very low in-hospital mortality, and minimal morbidity reported. At midterm follow-up, most patients remained free from severe MR recurrence or reintervention, supporting durability in selected cases. The Neochord procedure preserves native leaflet anatomy without limiting future treatment options. These findings support its role as a first-line re-repair option in anatomically suitable patients, whereas further studies should refine patient selection and long-term outcomes.

Webcast

You can watch a Webcast of this AATS meeting presentation by going to: https://www.aats.org/resources/micro-invasive-off-pump-trans–9963.



Audio

Audio Recording: You can listen to the audio recording of the presentation and discussion associated with this paper: https://doi.org/10.1016/j.jtcvs.2026.01.036.

Declaration of Generative AI and AI-Assisted Technologies in the Writing Process

During the preparation of this work the authors used ChatGPT and OpenAI in order to improve grammar and clarity. After using this tool/service, the authors reviewed and edited the content as needed and take full responsibility for the content of the publication.

Downloaded for Anonymous User (n/a) at Vilnius University from ClinicalKey.com by Elsevier on October 20, 2026.
For personal use only. No other uses without permission. Copyright ©2026. Elsevier Inc. All rights reserved.

Conflict of Interest Statement

S.S., R.Y., P.S.N., J.C., A.D., A.A., A.V., G.S., F.V., and G.G. are proctors for NeoChord, Inc. All other authors reported no conflicts of interest.

The *Journal* policy requires editors and reviewers to disclose conflicts of interest and to decline handling or reviewing manuscripts for which they may have a conflict of interest. The editors and reviewers of this article have no conflicts of interest.

References

1. Kakuta T, Peng D, Yong MS, Skarsgard P, Cook R, Ye J. Long-term outcome of isolated mitral valve repair versus replacement for degenerative mitral regurgitation in propensity-matched patients. *J Thorac Cardiovasc Surg Open*. 2024;17:84-97.
2. Chikwe J, Goldstone AB, Passage J, et al. A propensity score-adjusted retrospective comparison of early and mid-term results of mitral valve repair versus replacement in octogenarians. *Eur Heart J*. 2011;32(5):618-626.
3. Gillinov AM, Blackstone EH, Nowicki ER, et al. Valve repair versus valve replacement for degenerative mitral valve disease. *J Thorac Cardiovasc Surg*. 2008;135(4):885-893.
4. Suri RM, Clavel MA, Schaff HV, et al. Effect of recurrent mitral regurgitation following degenerative mitral valve repair: long-term analysis of competing outcomes. *J Am Coll Cardiol*. 2016;67(5):488-498.
5. David TE, David CM, Tsang W, Lafreniere-Roula M, Manlhiot C. Long-term results of mitral valve repair for regurgitation due to leaflet prolapse. *J Am Coll Cardiol*. 2019;748:1044-1053.
6. Kilic A, Acker MA, Gleason TG, et al. Clinical outcomes of mitral valve reoperations in the United States: an analysis of the Society of Thoracic Surgeons National Database. *Ann Thorac Surg*. 2019;107(8):754-759.
7. Vohra HA, Whistance RN, Roubelakis A, et al. Outcome after redo-mitral valve replacement in adult patients: a 10-year single-centre experience. *Interact Cardiovasc Thorac Surg*. 2012;14(5):575-579.
8. Roselli EE, Pettersson GB, Blackstone EH, et al. Adverse events during reoperative cardiac surgery: frequency, characterization, and rescue. *J Thorac Cardiovasc Surg*. 2008;135(2):316-323.
9. Mehaffey HJ, Hawkins RB, Schubert S, et al. Contemporary outcomes in reoperative mitral valve surgery. *Heart*. 2018;104(8):652-656.
10. Colli A, Besola L, Montagner M, et al. Prognostic impact of leaflet-to-annulus index in patients treated with transapical off-pump echo-guided mitral valve repair with neochord implantation. *Int J Cardiol*. 2018;257:235-237.
11. Seeburger J, Rinaldi M, Nielsen SL, et al. Off-pump transapical implantation of artificial neo-chordae to correct mitral regurgitation: the TACT Trial (Transapical Artificial Chordae Tendinae) proof of concept. *J Am Coll Cardiol*. 2014;63(9):914-919.
12. D'Onofrio A, Fiocco A, Nadali M, et al. Outcomes of transapical mitral valve repair with neochordae implantation. *J Thorac Cardiovasc Surg*. 2023;165(3):1036-1046.
13. Salizzoni S, Marro M, Rovera C, Speziali G, Rinaldi M. Off-pump neochord mitral valve repair to simultaneously treat posterior leaflet prolapse and systolic anterior motion. *Ann Thorac Surg*. 2017;103(1):e29-e30.
14. Gerosa G, Nadali M, Longinotti L, et al. Transapical off-pump echo-guided mitral valve repair with neochordae implantation mid-term outcomes. *Ann Cardiothorac Surg*. 2021;10(1):131-140.
15. Gerosa G, Besola L, Beiras-Fernandez A, et al. The neochord procedure after failed surgical mitral valve repair. *Semin Thorac Cardiovasc Surg*. 2021;33(1):35-44.
16. Vairo A, Gaiero L, Marro M, et al. New echocardiographic parameters predicting successful trans-ventricular beating-heart mitral valve repair with neochordae at 3 years: monocentric retrospective study. *J Clin Med*. 2023;12(5):1748.
17. Gerosa G, D'Onofrio A, Evangelista G, Vida VL, Pradegan N. Sternal-sparing transapical, beating heart mitral valve repair in an adult with repaired tetralogy of Fallot. *JACC Case Rep*. 2023;14:101818.
18. Carpentier A. Cardiac valve surgery—the "French correction.". *J Thorac Cardiovasc Surg*. 1983;86(3):323-337.
19. Vairo A, Marro M, De Ferrari GM, Rinaldi M, Salizzoni S. Use of a photorealism 3D rendering technique to enhance echocardiographic visualization of the anatomical details during beating-heart mitral valve repair. *Echocardiography*. 2019;36(11):2090-2093.
20. Colli A, Manzan E, Aidietis A, et al. An early European experience with transapical off-pump mitral valve repair with neochord implantation. *Eur J Cardiothorac Surg*. 2018;54(3):460-466.
21. Vairo A, Manai R, Gaiero L, et al. Three-dimensional finger test: a new echocardiographic method to locate the best access site during neochord procedure. *Innovations (Phila)*. 2023;18(4):331-337.
22. Vairo A, Marro M, Speziali G, Rinaldi M, Salizzoni S. "The Starry Sky." A new intraprocedural three-dimensional echocardiographic technique. *Echocardiography*. 2019;36(9):1765-1768.
23. Colli A, Zucchetta F, Torregrossa G, et al. Transapical off-pump mitral valve repair with Neochord implantation (TOP-MINI): step-by-step guide. *Ann Cardiothorac Surg*. 2015;4(3):295-297.
24. Stone GW, Adams DH, Abraham WT, et al. Clinical trial design principles and endpoint definitions for transcatheter mitral valve repair and replacement: part 2: endpoint definitions: a consensus document from The Mitral Valve Academic Research Consortium. *J Am Coll Cardiol*. 2015;66(3):308-321.
25. Zoghbi WA, Adams D, Bonow RO, et al. Recommendations for noninvasive evaluation of native valvular regurgitation: a report from the American Society of Echocardiography developed in Collaboration with the Society for Cardiovascular Magnetic Resonance. *J Am Soc Echocardiogr*. 2017;30(4):303-371.
26. Moore RA, Wierup P, Tappuni S, et al. Reoperation after early and late failure of mitral valve repair for degenerative disease. *J Thorac Cardiovasc Surg*. 2024;167(4):1251-1262.
27. Gerosa G, Thourani VH, Borger M, D'Onofrio A. Microinvasive cardiac surgery: when less is more—"render to Caesar the things that are Caesar's; and to the surgeon the things that are the surgeons". *Eur J Cardiothorac Surg*. 2022;62(1):ezac084.
28. Barbero C, Pocar M, Costamagna A, et al. Endo-aortic clamp for minimally invasive redo mitral valve surgery: early outcome. *J Cardiovasc Dev Dis*. 2024;11(11):358.
29. Rahhab Z, Lim DS, Little SH, et al. MitraClip after failed surgical mitral valve repair—an international multicenter study. *J Am Heart Assoc*. 2021;10(7):e019236.
30. Giordano A, Ferraro P, Finizio F, et al. Transcatheter mitral valve repair with the MitraClip device for prior mitral valve repair failure: insights from the GIOTTO-FAILS study. *J Am Heart Assoc*. 2024;13(10):e033605.
31. Case BC, Lisko JC, Babaliaros VC, et al. LAMPOON techniques to prevent or manage left ventricular outflow tract obstruction in transcatheter mitral valve replacement. *Ann Cardiothorac Surg*. 2021;10(1):172-179.
32. Khan JM, Babaliaros VC, Greenbaum AB, et al. 5-year outcomes of anterior mitral leaflet laceration to prevent outflow obstruction. *JACC Cardiovasc Interv*. 2024;17(18):2157-2167.
33. Babaliaros VC, Greenbaum AB, Khan JM, et al. Intentional percutaneous laceration of the anterior mitral leaflet to prevent outflow obstruction during transcatheter mitral valve replacement: first-in-human experience. *JACC Cardiovasc Interv*. 2017;10:798-809.
34. Pagnesi M, Moroni F, Beneduce A, et al. Thrombotic risk and antithrombotic strategies after transcatheter mitral valve replacement. *JACC Cardiovasc Interv*. 2019;12(23):2388-2401.
35. Mastro F, Angelini A, D'Onofrio A, Gerosa G. A journey from resect to respect to restore: aiming at optimal physiological surgical mitral valve repair. *J Cardiovasc Med (Hagerstown)*. 2023;24(1):1-11.
36. Latib A, Ho EC, Scotti A, et al. First-in-human transseptal transcatheter mitral chordal repair. *JACC Cardiovasc Interv*. 2022;15(17):1768-1769.
37. Barbero C, Vairo A, Marro M, et al. Reintervention for recurrence of mitral valve regurgitation: transventricular beating heart neochordae implantation versus on-pump surgery. *J Thorac Cardiovasc Surg Tech*. 2025;35:102106. https://doi.org/10.1016/j.xjtc.2025.09.020

Key Words: mitral valve repair, recurrent mitral regurgitation, redo surgery, NeoChord, microinvasive mitral repair, transventricular off-pump repair, mitral valve reintervention, chordae implantation, minimally invasive cardiac surgery, mitral regurgitation recurrence

Downloaded for Anonymous User (n/a) at Vilnius University from ClinicalKey.com by Elsevier on October 20, 2026.
For personal use only. No other uses without permission. Copyright ©2026. Elsevier Inc. All rights reserved.