

Letter to the Editor

## Histological insights into sudden, unexpected death due to tuberculosis: two autopsy case reports and review of the literature

Rosanna Zamparese<sup>1</sup>, Margherita Neri<sup>2</sup>, Giovanni Tossetta<sup>3</sup>, Massimo Senati<sup>1</sup>, Francesco Brandimarti<sup>1</sup>, Francesca Licitra<sup>4</sup>, Dario Piombino-Mascalì<sup>5,6</sup>, Ginevra Malta<sup>7</sup>, Angelo Montana<sup>4</sup>

<sup>1</sup> Legal Medicine Unit, "C. & G. Mazzoni" Provincial General Hospital, Ascoli Piceno, Italy; <sup>2</sup> Section of Public Health Medicine, Department of Medical Sciences, University of Ferrara, Ferrara, Italy; <sup>3</sup> Department of Human Sciences and Promotion of Quality of Life, San Raffaele Rome University, Rome, Italy; <sup>4</sup> Department of Biomedical Sciences and Public Health, Marche Polytechnic University, Ancona, Italy; <sup>5</sup> Department of Anatomy, Histology and Anthropology, Institute of Biomedical Sciences, Faculty of Medicine, Vilnius University, Vilnius, Lithuania; <sup>6</sup> Department of Cultural Heritage, University of Salento, Lecce, Italy; <sup>7</sup> Department of Health Promotion, Mother and Childcare, Internal Medicine and Medical Specialties (PROMISE), University of Palermo, Palermo, Italy

### Summary

We report two singular cases of sudden death in which the cause was advanced tuberculosis infection. In the first case, a 24-year-old man died suddenly following massive hemoptysis due to erosion of the pulmonary vessels. The second case involved a 29-year-old man who died unexpectedly from asphyxia secondary to hemoptysis caused by fibrocavitary tuberculosis. Toxicological screening and HIV testing were negative in both cases. Medico-legal autopsy, combined with detailed histological examination, was essential to determine the exact cause of death.

**Keywords:** sudden death, autopsy, tuberculosis, haemoptysis, histopathology

Received: November 8, 2025

Accepted: April 1, 2026

### Correspondence

Angelo Montana

E-mail: a.montana@univpm.it

**How to cite this article:** Zamparese R, Neri M, Tossetta G, et al. Histological insights into sudden, unexpected death due to tuberculosis: two autopsy case reports and review of the literature. *Pathologica* 2026;118:134-137 <https://doi.org/10.32074/1591-951X-1804>

© Copyright by Società Italiana di Anatomia Patologica e Citopatologia Diagnostica, Divisione Italiana della International Academy of Pathology



OPEN ACCESS

This is an open access journal distributed in accordance with the CC-BY-NC-ND (Creative Commons Attribution-NonCommercial-NoDerivatives 4.0 International) license: the work can be used by mentioning the author and the license, but only for non-commercial purposes and only in the original version. For further information: <https://creativecommons.org/licenses/by-nc-nd/4.0/deed.en>

Dear Editor,

Although tuberculosis is a disease with millennia of evidence in both palaeopathology and art, it remains a cause of sudden and unexpected death in modern populations<sup>1</sup>. Sudden deaths due to tuberculosis-related complications are more common in developing countries such as South Asia, Sub-Saharan Africa, and India, where high tuberculosis prevalence correlates with limited access to healthcare<sup>2,3</sup>. Massive hemoptysis, the most significant pulmonary complication of tuberculosis, accounts for more than 50% of related deaths<sup>4</sup> and is frequently associated with fibro-cavitation, bronchopulmonary tuberculosis with vessel erosion, aspiration of blood into the airways, or vascular anomalies such as Rasmussen's aneurysms<sup>5</sup>.

Here, we report the pulmonary alterations in the unexpected sudden deaths of two young male immigrants whose deaths were associated with tuberculosis, to aid in identifying causes of death in cases of hemorrhage without a definitive pre-mortem diagnosis.

## Case Reports

**Case 1:** A 24-year-old Romanian man died suddenly. Autopsy revealed increased lung weight (left lung 945 g, right lung 1050 g), tenacious pleural adhesions, and extensive perihilar lymphadenopathy. Lung parenchyma was extensively replaced by whitish nodules of varying sizes (Fig. 1A), which on section showed central caseous necrosis (white arrows, Fig. 1B) and cavitations with trabeculations and large necrotic hemorrhagic foci (yellow arrows, Fig. 1B). The bronchial lumen contained blood (Fig. 1C).

Histology (H&E staining) revealed numerous tuberculomas with central caseous necrosis (Fig. 1G), surrounded by a fibrotic wall containing Langhans giant cells, epithelioid histiocytes, and lymphocytes. Ziehl–Neelsen staining confirmed *Mycobacterium tuberculosis* bacilli (Fig. 1I). Tuberculomas were also observed in perihilar lymph nodes (Fig. 1L). The cause of death was attributed to massive hemoptysis, likely due to bronchial vessel erosion by the infection.

**Case 2:** A 29-year-old Indian man residing in Italy underwent autopsy revealing lung hepatization, bilateral pleural adhesions, and parenchyma replaced by nodular whitish solid formations, some with central cavitations. The tracheobronchial tree contained blood, and multiple tubercles were visible on the lung surfaces. Lung sections demonstrated caseating necrosis with cavitation (Fig. 1B,D,F). Histology showed markedly dilated alveoli, congested alveolar septal vessels, pulmonary edema, and parenchyma replaced by nodular formations with central caseous necrosis surrounded by fibrotic walls, Langhans giant cells, epithelioid histiocytes, and lymphocytes. Ziehl–Neelsen staining confirmed *Mycobacterium tuberculosis* bacilli (Fig. 5C). Cause of death was asphyxia due to hemoptysis secondary to fibrocavitary tuberculosis. Microbiological testing confirmed tuberculosis infection.

In both cases, epidemiological investigation identified tuberculosis infection among cohabitants, who received appropriate antibiotic treatment.

## Discussion

Sudden unexpected death (SUD) is defined as the unexpected death of an individual with no prior medical history, where a cause cannot be certified without autopsy. Pulmonary tuberculosis can present as bronchopneumonia and hemoptysis and may involve other vital organs. Tuberculosis rarely causes sudden death, except in rare cases of tuberculous myocarditis<sup>6</sup>.

The literature reports several cases of SUD due to hemoptysis in tuberculosis infection<sup>7</sup>. Tuberculo-

sis-associated hemoptysis has been linked to healed tuberculosis with bronchiectasis in 17.3% of cases and active pulmonary disease in 15.4% of cases<sup>8</sup>. Pulmonary artery thrombosis near a tuberculous lesion, compensatory bronchial artery dilation, and vessel erosion by tuberculous lesions are primary causes of haemoptysis<sup>9</sup>.

In Case 1, external injury as a cause of hemorrhage was excluded; death was due to acute upper airway hemorrhage. Massive hemoptysis, likely from bronchial vessel erosion, caused hemorrhagic shock and cardiocirculatory arrest. Hemoptysis may be the first manifestation of significant respiratory disease and can lead to death via blood loss or asphyxiation<sup>10</sup>.

Case 2 involved asphyxia due to hemoptysis secondary to fibrocavitary tuberculosis. Histological examination of the heart showed diffuse edema, wavy-shaped cardiomyocytes, myofibril reduction, sarco-plasmic depletion, and intercalated disc disruption, suggesting coexisting dilated cardiomyopathy.

Sudden death represents a challenge for forensic pathologists. In both cases, tuberculosis-associated hemoptysis was the cause of death, and autopsy was critical in reaching the diagnosis. Post-diagnosis, epidemiological investigation enabled treatment of cohabitants, preventing further spread. Tuberculosis screening strategies for migrants may help identify and treat undiagnosed cases, reducing public health risk.

## CONFLICTS OF INTEREST STATEMENT

The authors declare no conflicts of interest.

## FUNDING

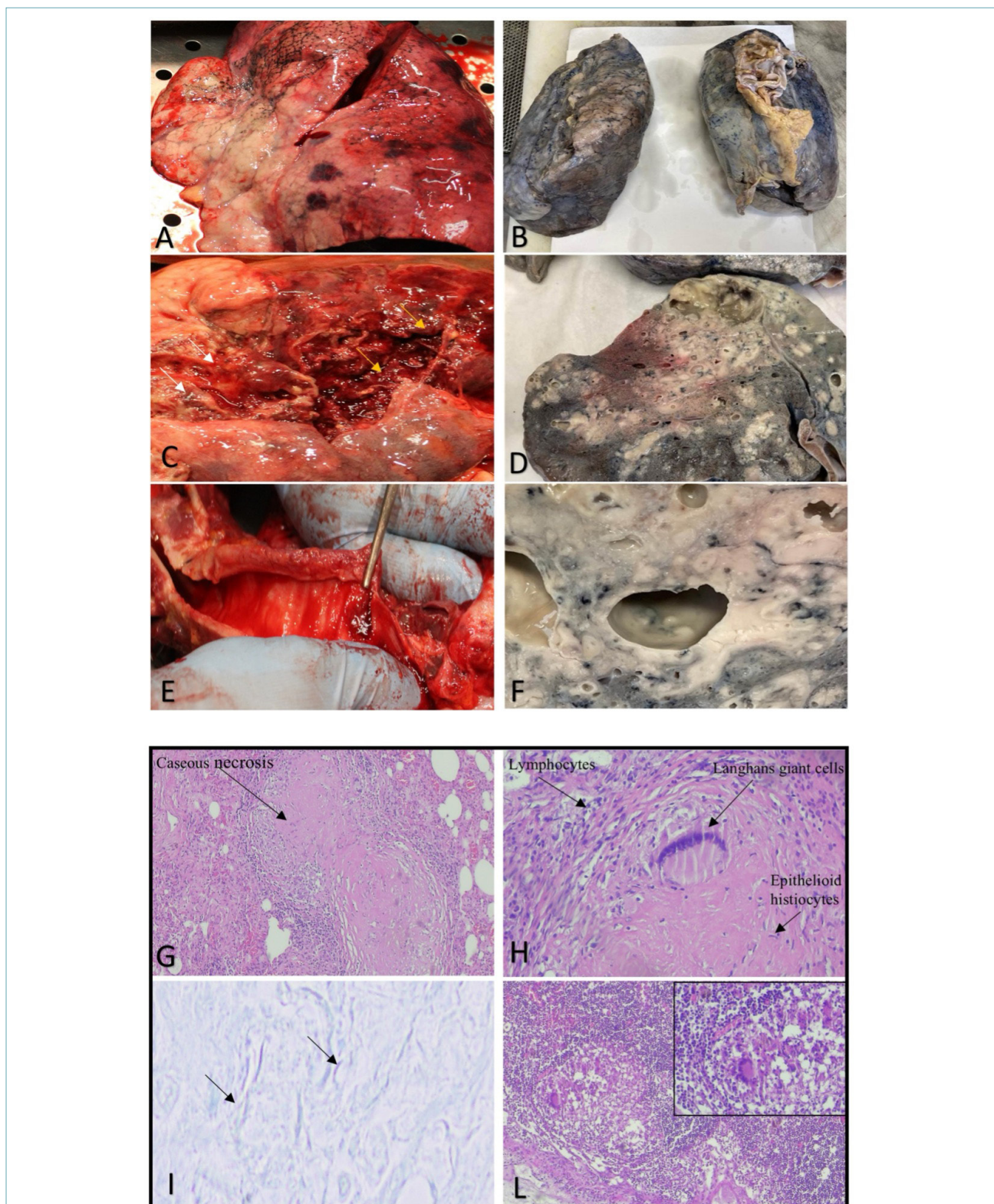
None.

## AUTHOR CONTRIBUTIONS

Conceptualisation: R.Z., M.N., G.M., A.M.; Methodology: G.T., M.S.; Software: F.B., F.L.; Validation: A.M., D.P.M., G.M.; Formal analysis: R.Z., M.N., G.M.; Investigation: G.T., F.L.; Data curation: M.S., F.B., D.P.M.; Writing – original draft: M.N., A.M., F.L.; Writing – review & editing: A.M., G.M., R.Z., M.N.; Visualisation: F.L., D.P.M.; Supervision: R.Z., A.M., M.N., G.M. All authors have read and approved the final manuscript.

## ETHICAL CONSIDERATIONS

All procedures were conducted in accordance with institutional ethical standards and the 1964 Helsinki Declaration and its amendments. Case publication in anonymised form was authorised by the local prosecutor, and written informed consent was obtained from relatives. Formal ethical approval was not required.



**Figure 1.** Macroscopic examination of lungs: case 1 (A,C,E): Lung parenchyma replaced by whitish nodules of varying sizes (A); sections show tuberculomas with central cavitation and caseous necrosis (white arrows) and necrotic hemorrhagic foci (yellow arrows) (B); communication of tuberculoma with bronchus (C). Case 2 (B,D,F): Lung parenchyma replaced by necrotic nodular formations with central cavitations. Histology: H&E staining shows nodular formations with central caseous necrosis (G) surrounded by fibrotic walls and Langhans giant cells, epithelioid histiocytes, and lymphocytes (H). Ziehl-Neelsen staining identifies *M. tuberculosis* bacilli (I). Tuberculomas also present in perihilar lymph nodes (L). Magnifications: G,L=10×; H=60×; I=100×.

## References

- <sup>1</sup> Roberts CA, Buikstra JE. The bioarchaeology of tuberculosis: a global perspective on a re-emerging disease. Gainesville: University Press of Florida, 2003.
- <sup>2</sup> World Health Organization. Global Tuberculosis Report 2021. Geneva: WHO, 2021. Available at: <https://www.who.int/teams/global-tuberculosis-programme/tb-reports/global-tuberculosis-report-2021>. (Accessed on: 30/04/2023).
- <sup>3</sup> Hugar BS, Jayanth SH, Chandra YP, et al. Sudden death due to massive haemoptysis secondary to pulmonary tuberculosis: a case report. *J Forensic Leg Med* 2013;20:632-634. <https://doi.org/10.1016/j.jflm.2013.03.034>
- <sup>4</sup> Zafran N, Heldal E, Pavlovic S. Why do our patients die of active tuberculosis in the era of effective therapy? *Tuberc Lung Dis* 1994;75:329-333. [https://doi.org/10.1016/0962-8479\(94\)90077-9](https://doi.org/10.1016/0962-8479(94)90077-9)
- <sup>5</sup> Garzon AA, Cerruti MM, Golding ME. Exsanguinating haemoptysis. *J Thorac Cardiovasc Surg* 1982;84:829-833.
- <sup>6</sup> Michira BN, Alkizim FO, Matheka DM. Patterns and clinical manifestations of tuberculous myocarditis: a systematic review of cases. *Pan Afr Med J* 2015;12:118-122. <https://doi.org/10.11604/pamj.2015.21.118.4282>
- <sup>7</sup> Tőro K, Mészáros A, Keller E. Forensic evaluation of sudden death due to tuberculosis. *J Forensic Sci* 2008;53:962-964. <https://doi.org/10.1111/j.1556-4029.2008.00763.x>
- <sup>8</sup> Abal AT, Nair PC, Cherian J. Haemoptysis: aetiology, evaluation and outcome-a prospective study in a third-world country. *Resp Med* 2001;95:548-552.
- <sup>9</sup> Wedzicha JA, Pearson MC. Management of massive haemoptysis. *Resp Med* 1990;84:9-12.
- <sup>10</sup> Thu M, Winskog C, Byard RW. Tuberculosis and sudden death. *Forensic Sci Med Pathol* 2014;10:266-268. <https://doi.org/10.1007/s12024-013-9501-z>