frontiers in Environmental Archaeology

TYPE Original Research
PUBLISHED 27 August 2026
DOI 10.3389/fearc.2026.1898083

Check for updates

OPEN ACCESS

EDITED BY
Joel D. Irish,
Liverpool John Moores University,
United Kingdom

REVIEWED BY
Roger Seiler,
University of Zurich, Switzerland
Anna Piccirillo,
Centro per la conservazione e per il restauro dei beni culturali 'La Venaria Reale', Italy

*CORRESPONDENCE
Dario Piombino-Mascali
dario.piombino@mf.vu.lt

RECEIVED 02 June 2026
REVISED 21 July 2026
ACCEPTED 22 July 2026
PUBLISHED 27 August 2026
CORRECTED 28 August 2026

CITATION
Minella R, Semenenko I, Davidson A, Girčius R, Tamošiūnas A, Davoli P and Piombino-Mascali D (2026) A forgotten Egyptian mummy head in Vilnius: CT, analytical, and bioarchaeological insights.
Front. Environ. Archaeol. 5:1898083.
doi: 10.3389/fearc.2026.1898083

COPYRIGHT
© 2026 Minella, Semenenko, Davidson, Girčius, Tamošiūnas, Davoli and Piombino-Mascali. This is an open-access article distributed under the terms of the Creative Commons Attribution License (CC BY). The use, distribution or reproduction in other forums is permitted, provided the original author(s) and the copyright owner(s) are credited and that the original publication in this journal is cited, in accordance with accepted academic practice. No use, distribution or reproduction is permitted which does not comply with these terms.

A forgotten Egyptian mummy head in Vilnius: CT, analytical, and bioarchaeological insights

Raffaella Minella[1,2], Illia Semenenko[3], Alison Davidson[4], Rokas Girčius[2,5], Algirdas Tamošiūnas[6], Paola Davoli[7] and Dario Piombino-Mascali[1,2]*

[1]Department of Cultural Heritage, University of Salento, Lecce, Italy, [2]Department of Anatomy, Histology, and Anthropology, Faculty of Medicine, Vilnius University, Vilnius, Lithuania, [3]Czech Institute of Egyptology, Charles University, Prague, Czechia, [4]Analytical Methods Laboratory, University of Staffordshire, Stoke-on-Trent, United Kingdom, [5]Radiology and Nuclear Medicine Center, Santaros Klinikos Vilnius University Hospital, Vilnius, Lithuania, [6]Department of Radiology, Nuclear Medicine, and Medical Physics, Faculty of Medicine, Vilnius University, Vilnius, Lithuania, [7]Department of Humanities, University of Salento, Lecce, Italy

This article presents the first multidisciplinary investigation of a mummified Egyptian head curated at the National Museum of Lithuania in Vilnius, Northern Europe. The specimen, long neglected and stored among other Egyptian antiquities, was examined in 2025 within the framework of the Lithuanian Mummy Project—an initiative aimed at studying mummified remains preserved in the country. Through a combination of macroscopic inspection, computed tomography (CT), 3D reconstruction, radiocarbon dating and chemical analysis, the research provides new insights into the biological profile, embalming practices, and chronology of the individual, while also critically reassessing the limited archival evidence concerning its provenance. The analysis identified a young to middle-aged adult male showing evidence of transnasal excerebration, dental pathologies, and heavy tooth wear indicative of a coarse diet. Radiocarbon dating of linen wrappings suggested a Third Intermediate Period attribution, as also confirmed by the embalming techniques employed. Chemical analysis identified the embalming resin to be of organic nature and was unable to confirm the presence of bitumen. Beyond its bioarchaeological findings, this study exemplifies the valorisation of a long-forgotten mummified individual through non-invasive scientific inquiry, demonstrating how such approaches can recover both scientific and cultural value from mummified human remains, and contribute to the reassessment of Egyptological collections in Northern Europe.

KEYWORDS
bioarchaeology, computed tomography (CT), Egyptian mummies, mummification, museum collection, transnasal excerebration

Highlights

- Multidisciplinary study of an undocumented Egyptian mummy head in Lithuania
- CT imaging reveals transnasal excerebration without intracranial resin
- Radiocarbon dating places the individual in the Third Intermediate Period
- Chemical analyses identify organic embalming resins lacking bitumen
- Study demonstrates research value of long-neglected museum human remains

1 Introduction

This study investigates a mummified human head housed at the National Museum of Lithuania, in Vilnius. The specimen was examined for the first time within the framework of the Lithuanian Mummy Project, a multidisciplinary project dedicated to the systematic study of mummified human remains preserved in the country (Piombino-Mascali et al., 2014, 2015, 2016, 2017).

Archival documentation concerning this specimen is limited. The only source currently available indicates that the head was acquired in 1886 by Professor Ivan Churilov (born 1864 in Kondakovo, Yaroslavl province, Russian Empire), a Russian obstetrician and surgeon who had studied under the renowned experimental neurologist and physiologist Ivan Pavlov, eventually graduating in 1895. In 1889, Churilov was enlisted in the reserve as an official of the Military Medical Department. Records indicate he visited Egypt and Sudan between 1886 and 1890, though the specific purpose of these journeys remains uncertain (Deikun, 2018).

Churilov's connection to Egypt extended beyond his initial visit. Due to his expertise in epidemiology, he was dispatched to Egypt in 1899 by the Imperial Commission on Measures to Prevent and Combat the Plague, serving as a specialist in the field. He spent six months in Alexandria, monitoring the plague epidemic's progression through Upper Egypt (Deikun, 2018). During his time in Egypt, Churilov would have had access to the broad and largely unregulated antiquities market that characterised the country in the late nineteenth century. Antiquities of this kind circulated through a variety of channels, including local intermediaries, antiquities dealers' shops in Cairo and other cities, and, from the early 1890s onward, the sale room established at the Egyptian Museum following its relocation to the Ismail Pasha Palace in Giza under the directorship of Jacques de Morgan (1892–1899) (Hagen and Ryholt, 2016). It remains plausible that Churilov acquired the mummy head through one of these commercial routes during one of his documented visits to Egypt, as was the fate of many artefacts entering European collections during this period; however, no direct archival evidence links the specimen to a specific vendor, dealer, or transaction, and its precise mode of acquisition cannot be established with certainty, and therefore must remain speculative.

In 1936, Churilov sold the head to the State Museum of the History of Religion in St. Petersburg, where it was catalogued as specimen No. 519-1 within Collection No. 519, comprising two embalmed heads reportedly originating from Memphis and dated to the 2nd-1st millennia BCE. Specimen No. 519-1 was subsequently transferred in 1976 as an unnumbered item to the Museum of Atheism of the Lithuanian Soviet Socialist Republic. Following Lithuania's independence in 1991, the head entered the National Museum of Lithuania, where it was published in 2011 in a catalogue of Egyptian antiquities (Snitkuvienė, 2011) and is currently housed under inventory numbers KT 123 and GEK 11581. The whereabouts of the second head (No. 519-2) remain unknown.

The present research pursues two principal aims: reconstructing the biological profile of the individual represented by these remains and critically examining the available archival and museological evidence to propose a plausible, though inherently speculative, geographical, and historical context for the specimen. This investigation employs a multidisciplinary, non-invasive analytical approach combining macroscopic assessment, computed tomography (CT), three-dimensional reconstruction, radiocarbon dating, and resin compositional analysis to establish the specimen's biological identity, chronological placement, and mummification techniques. By integrating palaeopathological findings with archival and museological data, this study contextualises — without definitively resolving — the specimen's likely provenance, and clarifies its chronological placement and museological history, ultimately contributing to broader discussions on the circulation, curation, and interpretation of Egyptian human remains within European museum collections.

2 Materials and methods

The specimen examined in this research is a mummified human head housed at the National Museum of Lithuania in Vilnius, currently stored in a cardboard box cushioned with bubble wrap and Styrofoam to prevent damage. The remains consist of an unbandaged cranium and mandible with portions of cervical tissue and first four cervical vertebrae, retaining fragments of original linen bandages impregnated with resin residues (Figure 1). The presence of linen wrappings and resin indicates authentic Egyptian mummification and embalming treatment (Ikram and Dodson, 1998). All analyses hereby described to comprehensively study the mummy head were conducted under the umbrella of the holding institution and in accordance with non-destructive research protocols for human remains.

2.1 Biological anthropology

Given the extensive presence of mummified soft tissue, the anthropological analysis was conducted through observation of the 3D-reconstructed model derived from the CT scan. The visual examination focused on estimating the individual's age based on indicators of tooth development (AlQahtani et al., 2010), patterns of dental wear (Lovejoy et al., 1985), and the degree of cranial suture obliteration (Meindl and Lovejoy, 1985). Sex estimation was determined through a qualitative scoring approach based on sexually dimorphic cranial features. Each observable trait was evaluated independently following the criteria described by Schwartz (2007) and White et al. (2012).

2.2 Radiology

The non-invasive and non-destructive approach included both visual inspection and palaeoimaging methods such as photography and computed tomography (CT) (Beckett, 2014). CT scans were performed at the Santaros Klinikos Vilnius University Hospital

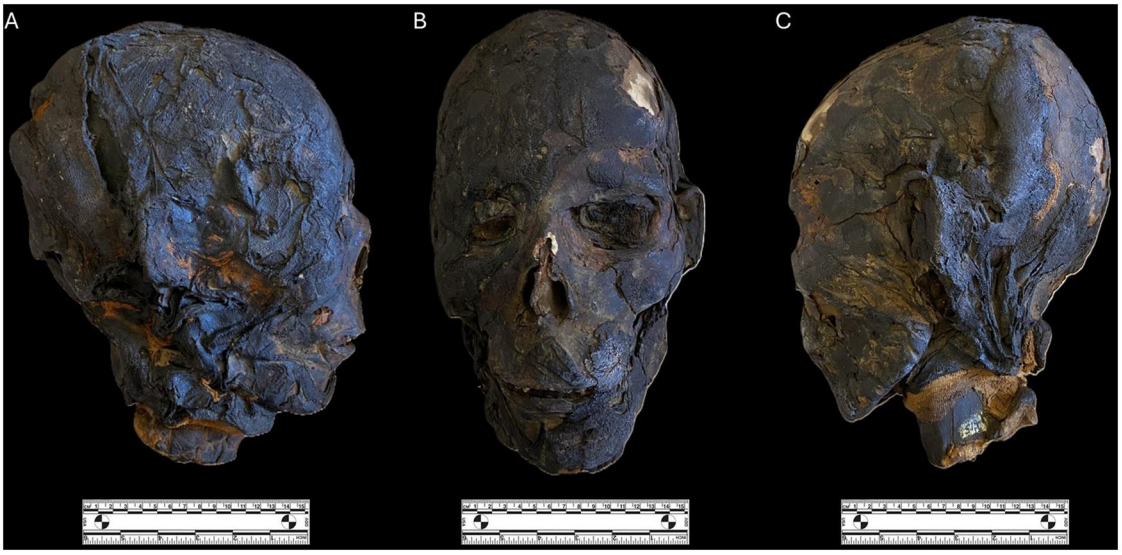

FIGURE 1
Right lateral **(A)**, frontal **(B)** and left lateral view of the head **(C)**; partial linen bandages and underlying mummified tissue can be seen. With scale.

(Vilnius, Lithuania), where axial images were obtained in helical mode. A Philips Incisive CT scanner was employed to scan the mummy head, and the protocol adopted included a slice thickness of 0.5 mm and a tube voltage of 120 kV of variable mA, which resulted in a high level of resolution of all tissue types. Furthermore, the Hounsfield Unit (HU) scale was employed to measure radiodensity (Villa and Lynnerup, 2012). Both external and internal anatomical landmarks were used to position the mummy in the scanner headrest, although the fragility of the artefact had to be taken into consideration when manoeuvring. Post-processing imaging was performed with RadiAnt DICOM viewer. Moreover, multiplanar reconstructions (MPR) in the axial, sagittal, and coronal planes were generated for detailed dental assessment. Curved multiplanar reconstruction (curved MPR/CPR) following the dental arch was not performed, as the software available for this study did not support this reconstruction technique.

2.3 Radiocarbon dating

Two detached bandage fragments were recovered from the storage container, likely separated through deterioration and movement during storage. Approximately 10 mg of textile material, impregnated with resin, was submitted for radiocarbon dating to the Vilnius Radiocarbon Laboratory (Vilnius, Lithuania). Given the resin impregnation, the laboratory provided two separate results: one for the untreated sample and another following chemical extraction of the resin. Samples underwent pretreatment using Soxhlet extraction and an acid-base-acid protocol, then analysed using a single stage accelerator mass spectrometer (SSAMS, NEC, USA). Dates were calibrated using OxCal software (Bronk Ramsey, 2009) with the IntCal20 dataset (Reimer et al., 2020). For this study, only the date obtained from the resin-free sample was considered.

2.4 Chemical analysis

Additional small fragments of the resinous embalming material found in the bottom of the storage box were chemically analysed at the Analytical Methods Laboratory, University of Staffordshire (Stoke-on-Trent, United Kingdom) to determine the components of the material. Initial examination under low-powered microscopy showed the fragments to be around 5 mm in diameter and quite heterogeneous in their surface morphology with the impression of the woven material clearly visible on the underside of some pieces (images are available at https://osf.io/fdvpm/). Also, while most fragments were of a black resinous substance, there were small grains of amber-coloured resin which had become detached from the larger pieces. One small fragment of the black material was mounted on an aluminium stub using a carbon tab (both from Agar Analytical) and analysed using scanning electron microscopy and energy dispersive X-ray analysis (SEM-EDX), employing the instrumentation and conditions described in Squires et al. (2024). The sample was imaged using low vacuum secondary electron imaging (at 40 Pa, 15 kV and 10–11 mm working distance) and therefore no additional sample preparation was needed. An EDX spectrum was collected for 60 s (livetime) under the same conditions and at 60× magnification, so that the sample filled the field of view. EDX quantification was performed using the pre-installed standardisation database provided with the INCA software (Oxford Instruments version 5.04); however, quant optimisation was not performed, so all resulting atomic percentage values should be considered approximate. Further details of the standards used for the EDX database are available in the supplementary data provided at https://osf.io/fdvpm/. Samples of 5–10 mg of black resinous material were separately extracted with hexane and ethanol (both Fisherbrand, HPLC grade). The samples did not dissolve easily in either solvent, even after 5 min in an ultrasonic bath, and had to be filtered using 0.2 µm regenerated cellulose hydrophilic Clarisep® filters (Sartorius, Göttingen, Germany). An additional sample of black resin and a separate small (5.9 mg)

sample of amber resin were extracted in the same manner but using dichloromethane (Fisherbrand, HPLC grade) and then derivatised with BSTFA (N,O-bis(trimethylsilyl)trifluoroacetamide with 1% TCMS trimethylchlorosilane, LiChropur) as described in Squires et al. (2024). One further sample (4.6 mg) of the black resinous material was transferred to a 6 mL vial and the headspace was sampled using a 100 µm polydimethylsiloxane solid phase microextraction (SPME) fibre (Supelco), employing the conditions described in Squires et al. (2024). Subsequently, all samples were analysed using gas-chromatography with mass spectrometry (GC-MS), utilising the instrumentation and operating parameters described in Squires et al. (2024).

3 Results

3.1 Anthropological investigation

The remains consist of a cranium and mandible, as well as part of the neck, partially covered by fragments of a resin-soaked linen wrapping, exposing some part of intact skin, which appears shrunken, desiccated, and black in colour (Figure 1). Through the 3D-reconstructed model from the CT scan, it was possible to observe that the third molar is present and fully erupted on both the upper and lower dentition, and, together with the development of the cranium, indicates an adult individual. It must be noted that all ectocranial sutures observed on the 3D-reconstructed model remain open, with no evidence of ectocranial closure at any site examined. Following Meindl and Lovejoy (1985), the complete absence of ectocranial suture closure is most consistent with an individual in their third to early fourth decade of life, although open sutures persisting into the fourth or fifth decade cannot be entirely excluded and are reported in the literature as an uncommon but recognised pattern (Key et al., 1994). Given this ambiguity, together with the fully erupted third molars and mature cranial and dental development, we estimate an age at death of approximately 25–40 years. This range should be regarded as a broad approximation given the absence of postcranial skeletal indicators, which are typically used alongside cranial sutures for more precise age estimation. This hypothesis is also supported by the fact that the bone looks overall well mineralised and the cortical thickness appears normal, indicating that the individual did not suffer from osteoporosis or other metabolic bone disease. Moreover, heavy dental wear is observed on both the upper and lower dentition. The skull presents a strong mental eminence, flaring of the mandibular angle as well as a strong gonial angle, protruding glabella and nuchal crest, and large mastoid processes. The first four cervical vertebrae (C1–C4) are preserved in articulation with the cranium. CT examination of these elements shows no evidence of degenerative joint disease, osteophytosis, or other pathological change; vertebral body margins are smooth and cortical bone appears intact. Thus, the individual was determined to be of male sex (Figure 2), and the age at death was estimated to be around the third to early fourth decade of life. Given the lack of long bones, no stature estimation was attempted.

3.2 Palaeopathological investigation

The main pathologies affecting this individual appear to be dental diseases. The upper right first and second incisors show semilunar defects at the incisal/labial margin (Figures 3,4). Although these lesions may be consistent with carious destruction, their morphology is not diagnostic, and alternative explanations, including post-mortem crown damage, cannot be excluded based on imaging alone. The upper left first molar shows a well-defined periapical radiolucent lesion approximately 5 mm in diameter, immediately adjacent to a second, ill-defined lesion with non-sclerotic margins; together, the combined lesion measures approximately 13.9 × 11.4 mm (Figure 5). This morphology — a well-corticated focus adjoining a poorly-marginated, non-sclerotic area — is suggestive of an infectious process, discussed further below. The lower dentition seems to be unaffected by dental pathologies, although heavy wear is observed on all teeth, along with a slight misalignment of the right first premolar. Notably, a displaced tooth fragment was identified in the nasopharynx, measuring approximately 1,862 HU — a density consistent with dental tissue (Çelik and Emin Dogan, 2024) and considerably higher than surrounding soft tissue or desiccated mucosal structures — supporting its identification as a displaced tooth fragment rather than an artefact of soft tissue desiccation or foreign material.

As shown in Figure 6, some Pacchionian granulations, also known as arachnoid granulations, are visible on the endocranial surface of the left frontal bone.

3.3 Embalming procedure

Because the brain held no particular value to the Egyptians and was a potential source of putrefaction after death, it was traditionally removed from a corpse before embalming and burial (Andrews, 2004; Brier, 1994; Dunand and Lichtenberg, 1994; Harris and Wente, 1980a). Historical accounts by Herodotus describe the insertion of a curved metal hook into the nostril of a corpse and the removal of the cranial contents via a transnasal, transethmoidal approach (Aufderheide, 2011; Dunand and Lichtenberg, 1994). Brier and Wade (2001) even attempted to replicate the excerebration procedure and concluded that the brain was most likely broken down into a semi-liquid state by two different tools, one hooked and one rolled (Brier and Wade, 2005) and then, assisted by gravity, it was evacuated through the nasal passage when the cadaver was positioned with the head downward.

Figure 7 portrays the axial and frontal views of the cranial vault, depicting an absent cribriform plate on both sides. Additional three-dimensional volume renderings of the anterior cranial base were generated to further document this finding (Figure 8); however, no residual bony margins are discernible around the defect that would allow characterisation of its precise configuration (e.g., single versus separate perforations) beyond confirming the bilateral absence of the plate itself. The lack of this bone establishes a communication between the nasal cavity

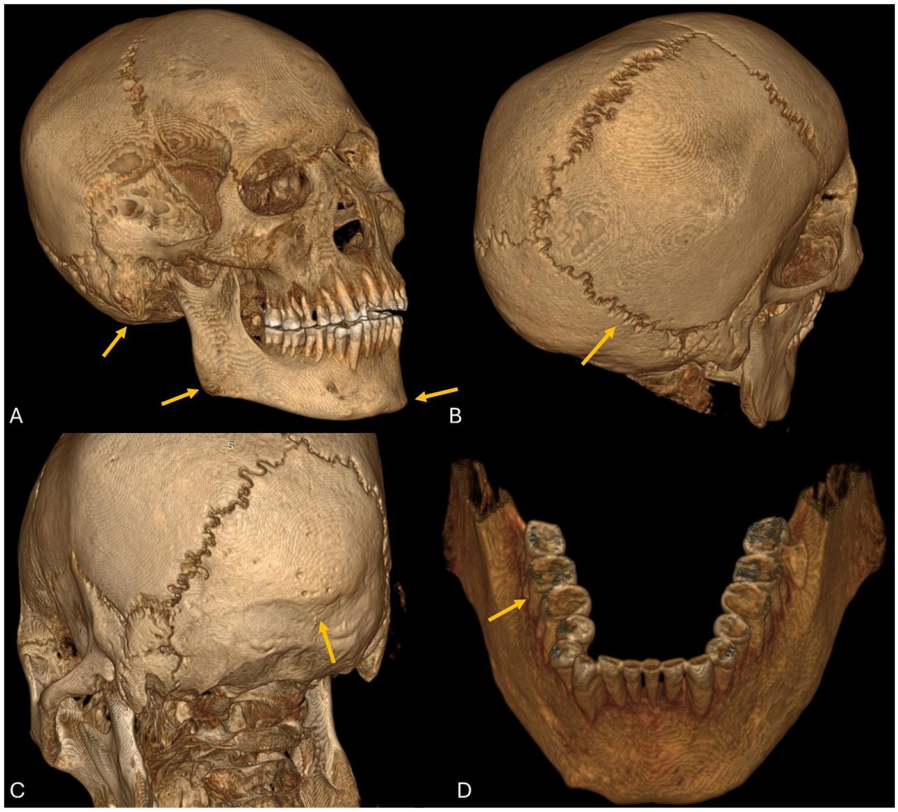

FIGURE 2
CT three-dimensional volume rendering reconstruction of the skull, including antero-lateral view **(A)**, posterior-oblique view **(B)**, postero-lateral view **(C)**, and superior-oblique view of the mandible **(D)**. Sex and age indicators are visible (as indicated by the yellow arrows), such as the mental eminence, the gonial angle, the mastoid process, and the nuchal crest, as well as suture obliteration and dental wear.

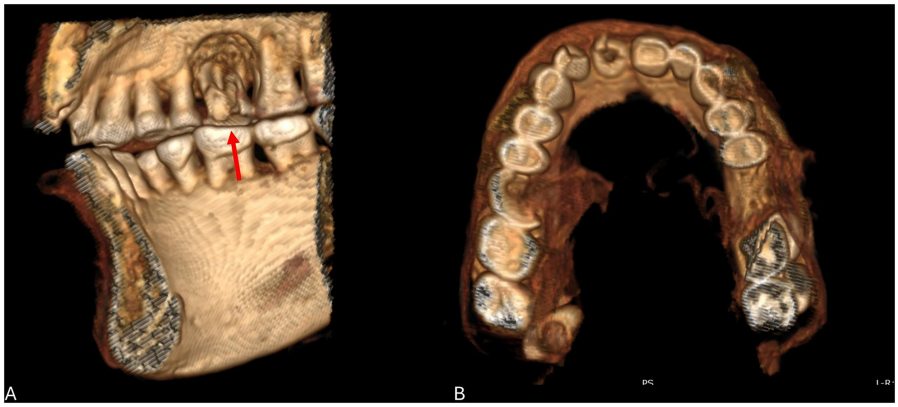

FIGURE 3
Periapical infection of the upper left first molar indicated by the red arrow **(A)**; view of the upper dentition **(B).**

and the intracranial space, thus indicating evidence of transnasal craniotomy. The bilateral nature of this defect is noteworthy: because the crista galli and adjacent intranasal structures remain intact and *in situ*, this pattern more plausibly reflects two discrete perforations, one through each side of the cribriform plate, rather than a single midline transethmoidal opening as is more commonly described in the literature (Aufderheide, 2011; Dunand and Lichtenberg, 1994). As shown in the CT scan, the mummified remains reveal an empty cranial cavity, meaning that the embalmers did not introduce any embalming material intracranially.

The tongue and the epiglottis appear to have been preserved, and the orbits are filled with heterogeneous material, likely linen impregnated with resin. However, the atrophied remains of the lens and optic nerves were identifiable in the right eye socket, while the left eye only showed evidence of the optic nerve present in the socket (Figures 9,10). A foreign substance was found in the mouth, likely free linen fibres (Figure 11). In addition, several

FIGURE 4
Multiplanar reconstructions (MPR) of the upper right incisors showing a semilunar defect at the incisal margin (yellow arrow). Sagittal MIP, 0.3 mm **(A)**; axial MIP, 1.3 mm **(B)**; and frontal/coronal MIP, 4.9 mm **(C)** views demonstrate the incisal defect between the upper right first and second incisors, more consistent with loss or fracture of dental tissue than with a carious lesion.

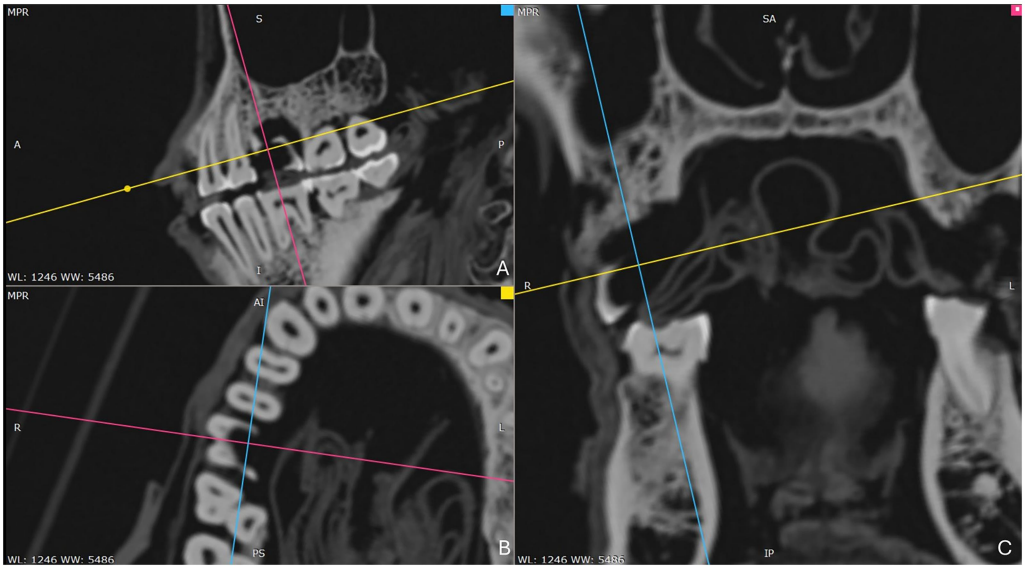

FIGURE 5
Multiplanar reconstructions (MPR) of the upper left first molar demonstrating the periapical lesion. Sagittal **(A)**, axial **(B)**, and coronal **(C)** views show a radiolucent periapical lesion at the root apex, comprising a well-defined component adjacent to a second, less-defined area without sclerotic margins.

low-density structures, ranging from semi-circular to semi-oval in cross-section, are distributed across the internal cranial cavity and posterior cranial base (Figure 12). Two are located along the lateral aspect of the right posterior cranial fossa, measuring approximately 7.8 × 7.4 mm (Figures 12A–C); one lies at the junction of the petrous ridge and squama of the right temporal bone, measuring 20 × 13 mm; one is situated at the right temporo-parietal suture, measuring 19 × 11 mm; and two further structures are located immediately below the foramen magnum, measuring 19 × 13 mm and 15 × 13 mm (Figure 12D). CT attenuation values for all structures measured approximately −900 HU, close to air density, suggesting these represent gas-filled voids rather than solid or mineralised material. Three-dimensional volume rendering (Figure 12E) illustrates their overall distribution across the endocranial surface.

3.4 Radiocarbon dating

As previously mentioned, it was noted that one of the two fragments was impregnated with a resin-like substance, likely used in the mummification process. Such impregnation can

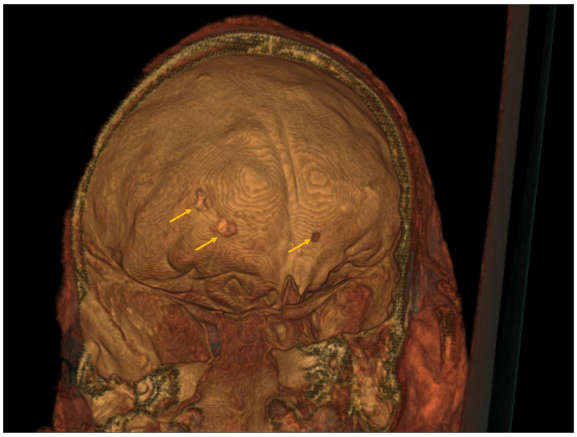

FIGURE 6
Pacchionian granulations on the left frontal bone (yellow arrows), endocranial view.

compromise radiocarbon accuracy through the introduction of exogenous carbon (Aufderheide et al., 2004). Thus, only the chemically cleaned, resin-free sample was considered for this study. The AMS ^{14}C calibrated age of the chemically treated textile sample is presented in Figure 13. The treated linen textile was dated to 816–753 BC ± 62 years, with 90.2% probability, placing the specimen within the Third Intermediate Period (c. 1076–c. 723 BC), specifically under the 23rd Dynasty (Hornung et al., 2006). This result aligns with historical sources suggesting the remains date to the 2nd or 1st millennia BCE. However, it should be noted that direct dating of the mummified tissue was not possible, as bone sampling would have violated our commitment to non-destructive and non-invasive analytical methods. While the date obtained is for the bandage material rather than the remains themselves, it is nevertheless reasonable to assume that the textiles and mummification occurred within a similar timeframe.

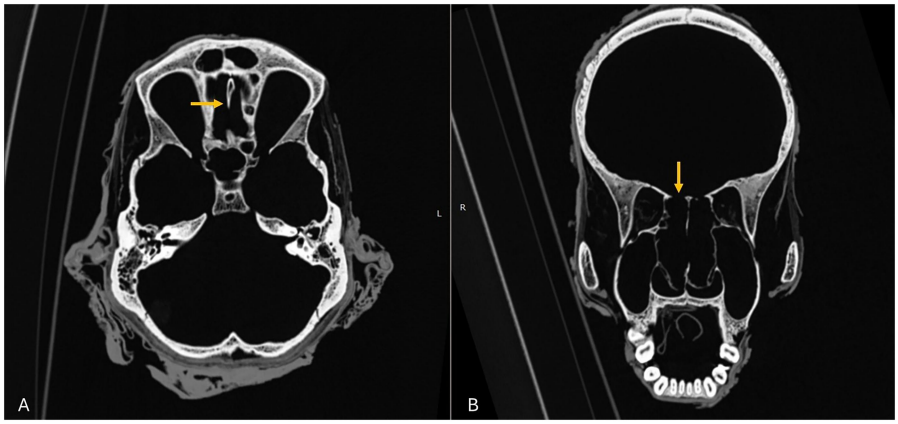

FIGURE 7
Axial **(A)** and frontal-oblique **(B)** CT images. Absence of the cribriform plate indicates a transnasal craniotomy (TNC), as indicated by the yellow arrow. However, the embalmers did not introduce any embalming material intracranially, as the skull was devoid of resin or other packing material.

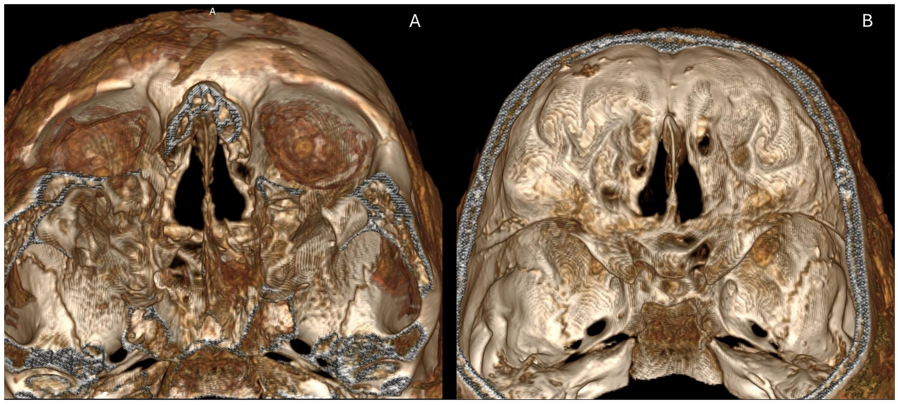

FIGURE 8
CT three-dimensional volume rendering reconstruction of the viscerocranium, showing bilateral absence of the cribriform plate, viewed from an anterior **(A)** and posterior **(B)** perspective. The crista galli remains intact and *in situ* between the two defects. No residual bony margins are discernible around either opening that would allow further characterisation of the perforations.

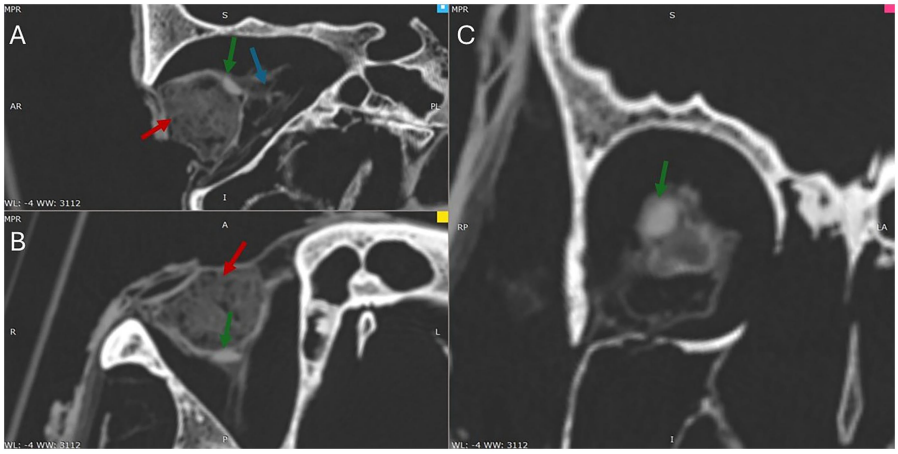

FIGURE 9
Multiplanar CT images of the right **(A–C)** eye socket, showing a linen pack inserted within the orbit (red arrow). The desiccated optic nerve was preserved (blue arrow), and the right eye also shows evidence of the lens still present (green arrow).

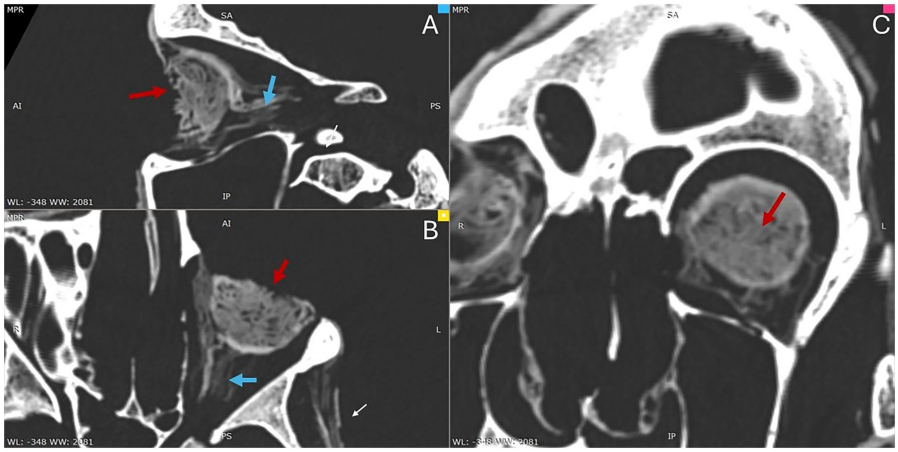

FIGURE 10
Multiplanar CT images of the left **(A–C)** eye socket, showing a linen pack inserted within the orbit (red arrow) with the desiccated optic nerve preserved (blue arrow).

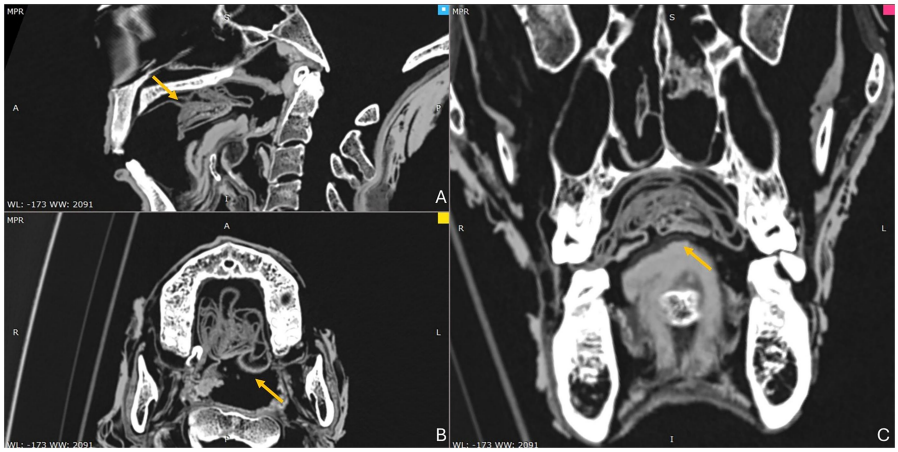

FIGURE 11
Sagittal **(A)**, axial **(B)** and frontal **(C)** CT images showing that the mouth is filled with free linen fibres (yellow arrow).

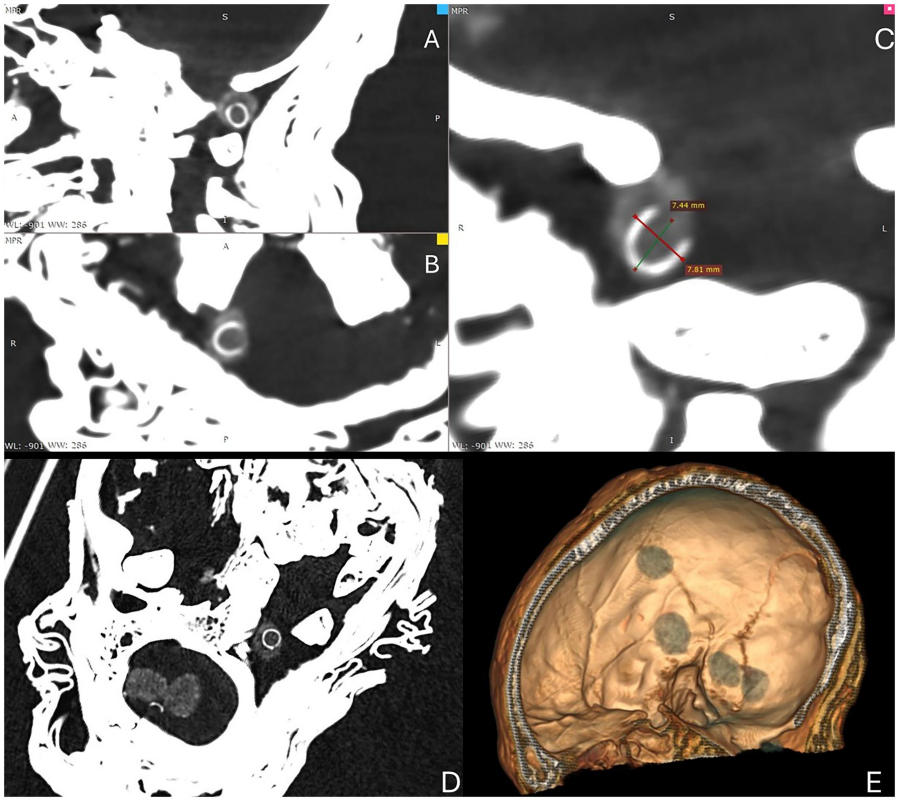

FIGURE 12
Multiplanar CT images of the mummified head showing inclusions within the cranial cavity and posterior region between the skull base and atlas; **(A–C)** detail of a semi-circular inclusion measuring approximately 7.8 × 7.4 mm; **(D)** axial-oblique CT slice revealing multiple semi-oval rounded inclusions of low attenuation (~ −900 HU), consistent with air-equivalent structures; **(E)** three-dimensional volume rendering illustrating the spatial distribution of these inclusions within the cranial cavity.

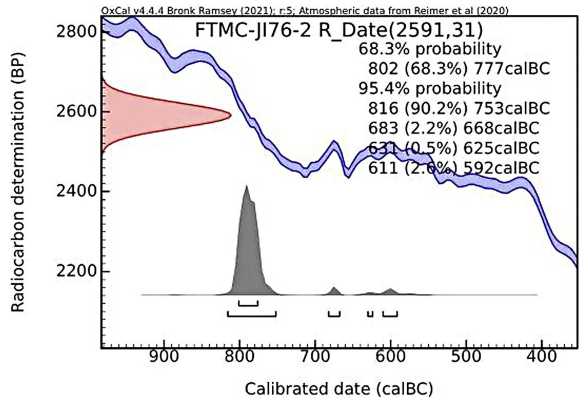

FIGURE 13
Radiocarbon dating of linen sample (not impregnated). Radiocarbon date 2,591 ± 31 BP (red), part of the calibration curve (blue) and the calibrated probability density function (grey) calculated in OxCal.

3.5 Chemical analysis

A chemical analysis was performed in order to contribute to the evaluation and interpretation of the value and significance of the small fragments of the resinous embalming material found in the bottom of the storage box. Firstly, imaging with the scanning electron microscope showed possible brush marks on the upper surface, potentially from the application of the resin to the material (Figure 14). Energy dispersive X-ray analysis showed that the elemental composition was primarily carbon (~ 75%) and oxygen (~ 23%) with small amounts of sodium, aluminium, silicon, sulphur, chlorine, potassium, and calcium (less than 1% each).

None of the metallic markers for bitumen described by Mikhailenko et al. (2016) and Yatsishina et al. (2019) (e.g., vanadium, nickel, and molybdenum) were detectable in the sample and the sulphur level of approximately 0.87% was just below the minimum expected from bitumen, which typically contains between 0.9%–6.6% sulphur (Mikhailenko et al., 2016). Additionally, the presence of bitumen in the embalming mixture cannot be confirmed by the results of the hexane extraction as selected ion chromatograms of m/z 191 and m/z 217 did not identify the presence of hopanes or steranes (Colombini et al., 2000). However, the hexane extraction (total ion chromatogram) did have peaks identified by NIST (with library match and reverse match values above 800) as ethylbenzene, o-xylene, and mesitylene (1,3,5-trimethylbenzene). These compounds were also found by Buckley et al. (1999) following pyrolysis GC-MS analysis of material from the mummies of Horemkenesi and Khnum-Nakht from ca. 2000 and 1000 BCE respectively, and in the



FIGURE 14
Possible brush marks observed under SEM at 100× magnification.

same investigation there was also no other evidence of bitumen (although the methods used did not target bitumen). However, these compounds are also commonly seen in modern petroleum products including coal-tar (Gerasimenko et al., 1981). The SPME analysis provided additional evidence for the possible presence of bitumen or coal-tar with peaks reported for camphor, camphene, naphthalene and alkanes C_n 5–7 (all with > 800 reverse match on NIST), but also a peak reported as anthracene (836/874 match and reverse match) which is not present in bitumen but is present in coal-tar (Gerasimenko et al., 1981). Given the lack of solubility of the resin samples in hexane, the inability to detect hopanes or steranes and the presumptive finding of anthracene, the possibility cannot be excluded that the remains may have been "re-touched" with coal-tar during their time in one of the museums.

The GC-MS results of the derivatised samples showed the presence of myristic, palmitic and stearic fatty acids which could be from animal or vegetable sources, and capric acid and azelaic acid were also seen in the sample of the amber-coloured material. Azelaic acid has previously been identified by Ribechini et al. (2009) as formed from polyunsaturated fatty acids by oxidation processes over time; Colombini et al. (2000) suggest that this could indicate the inclusion of a vegetable oil. In trying to identify a source of the original resinous material, 7-oxodehydroabietic acid was detected which has been reported by Colombini et al. (2000) as one of the main diterpenoid acids found in ancient pine resin; however, the wider range of diterpenoids expected from a resin of *Pinus pinea* were not detected (Buckley and Evershed, 2001; Clark et al., 2016; Łucejko et al., 2017), even after extracting chromatograms for the mass/charge values (m/z 241 and 257) characteristic of the diterpenoids routinely found in conifer resin (Colombini et al., 2000). Characteristic triterpenoid marker compounds for mastic resin with m/z values 189, 203, 410, 424, and 426 (Colombini et al., 2000) were also not detected, nor were any of the characteristic compounds for other previously reported resins (Evershed et al., 1997; Hamm et al., 2004; Huber et al., 2023), so the source of the resin base for the embalming material remains undetermined. Full results of the chemical analysis are available at https://osf.io/fdvpm/. Overall, the extraction failed to identify the range of chemicals seen in other samples (e.g., Squires et al., 2024; Vandenbeusch et al., 2021) which may be a limitation of the analytical techniques, may be due to the age and storage conditions of the samples, or may indicate that the recipe used for this embalming was simpler than seen in other examples.

4 Discussion

The palaeopathological study, combined with the biological information derived from computed tomography (CT) imaging, provides valuable insight into selected aspects of the individual's health status, particularly oral health and craniofacial pathology. It should be emphasised that, in the absence of the postcranial skeleton, a comprehensive reconstruction of overall health status, physical activity, and lifestyle — which typically relies on indicators such as musculoskeletal stress markers, long bone cross-sectional geometry, and joint pathology — is not possible for this individual, and the interpretations offered here are correspondingly limited to what the cranial and dental evidence can support. Osteological analysis indicates that the mummy was that of an adult man, with absence of ectocranial suture closure suggesting an age at death younger than previously assumed for individuals exhibiting comparable dental wear (Molnar, 1971, 1972); nonetheless, the estimated range of approximately 25–40 years should be treated as approximate, given the absence of postcranial age indicators. The pronounced dental wear and associated pathologies indicate the consumption of a coarse, abrasive diet consistent with established data on ancient Egyptian subsistence practices. Human dentition has long occupied a central position in bioarchaeological research, and the study of Egyptian teeth is no exception, with numerous investigations exploring their morphology and pathological patterns (Leek, 1966; Melcher et al., 1997; Nickol et al., 1995; Thekkaniyil et al., 2000).

The dentition of the mummified head examined in this study exhibits dental and periodontal disease consistent with patterns documented for the same period. Antemortem tooth loss was widespread among ancient Egyptians (Harris and Wente, 1980b), and CT analysis of the left mandible reveals

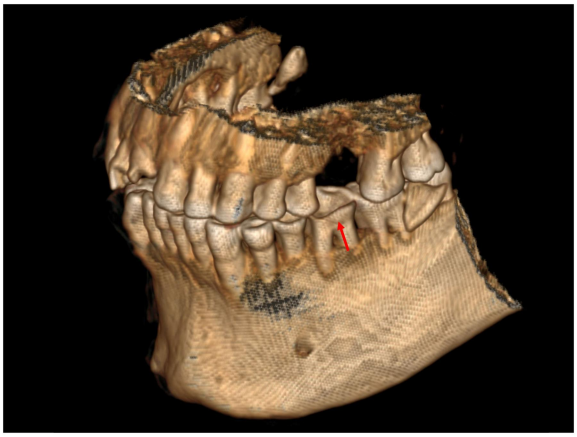

FIGURE 15
CT three-dimensional volume rendering obtained through the left mandible shows concavity of the cusps of preserved mandibular teeth. These changes are thought to result from sand and grit in the diet (red arrow).

cusp concavity in the preserved mandibular teeth (Figure 15). Such attrition has been widely attributed to the ingestion of food contaminated with sand and grit from grinding and milling processes (Hoffman and Hudgins, 2002). The presence of caries and antemortem tooth loss is equally expected given the population's carbohydrate-rich diet—Egyptians were often referred to as "eaters of bread"—which promoted plaque accumulation and subsequent decay (Miller, 2008). The combination of severe wear and carious activity likely led to the decay of the first molar, thus leading to the periapical abscess observed in Figure 5, resulting from bacterial infiltration through dentinal tubules into the pulp chamber, and progressive abrasion exposing the pulp despite secondary dentine formation. We differentiated the periapical abscess from other inflammatory periapical dental pathologies, particularly the periapical granuloma, based on distinct radiological features evident in the CT scan. The imaging demonstrated a slightly irregular, rough-walled bone cavity accompanied by a fistulous tract through which purulent material drained—findings consistent with periapical abscess formation as described in the literature (Hillson, 2023). Furthermore, we excluded various cystic pathologies from our differential diagnosis, as radiographically there were no unilocular or multilocular lucencies, which would be pathognomonic of a cystic lesion (Devenney-Cakir et al., 2011).

Similar dental wear and periodontal inflammation were found in another mummy from the Roman period curated in the National Museum of Lithuania (Piombino-Mascali et al., 2016). These findings are broadly consistent with the well-documented high prevalence of dental disease across ancient Egyptian populations (Forshaw, 2009). It should be noted, however, that documented temporal, regional, and socioeconomic variation in oral health existed within ancient Egypt, with dietary composition, food preparation methods, and access to particular food ingredients differing across social strata and periods (Forshaw, 2009; Miller, 2008); the present findings should therefore be understood as consistent with a general pattern rather than as evidence that dental disease affected all individuals uniformly irrespective of status. The cause of death cannot be definitively established from the available evidence. The chronic nature of the periapical lesion — indicated by the presence of a fistulous tract, which reflects a long-standing draining process rather than an acute infection — makes an acute fatal septicaemic event directly attributable to this lesion less likely than a slower, chronic disease course. Nonetheless, untreated dental infections were a recognised potential contributor to morbidity and, in some cases, mortality in antiquity (Dias and Tayles, 1997; Forshaw, 2014), therefore a contributory rather than sole causative role cannot be excluded.

The arachnoid fossae identified on the endocranium (Figure 6) represent areas of bone resorption associated with protrusions of the arachnoid membrane, known as Pacchionian granulations. These structures arise when the arachnoid membrane extends through the dura mater into the venous sinuses, permitting cerebrospinal fluid drainage (Rustenhoven et al., 2021). Although traditionally regarded as normal anatomical variations, recent work suggests that enlarged fossae may reflect meningeal pathology, including trauma, neoplasia, or infectious disease (Wysocka et al., 2025). The absence of the postcranial skeleton precludes the observation of pathological evidence of any of the aforementioned pathologies. Consequently, the significance of the Pacchionian granulations remains that of an isolated condition.

Regarding the mummification techniques involved, CT-derived data showed complete excerebration through transnasal craniotomy (TNC), with no attempt to fill the cranial cavity with resin or other materials. The orbital cavities and mouth were filled with linen packing or threadlike material, while the optic nerves, lenses, epiglottis, and tongue were retained. Such packing likely served to maintain a lifelike appearance by compensating for post-mortem tissue shrinkage or collapse (Ikram and Dodson, 1998). The bilateral absence of the cribriform plate observed in this specimen represents an atypical excerebration pattern. While transnasal craniotomy classically involves a single perforation through the ethmoid region to access the cranial cavity, the present findings suggest the embalmer may have created two separate access points, possibly reflecting either a technical variant of the procedure or difficulty encountered during a single-approach attempt. Given the limited comparative data on bilateral cribriform involvement in the published literature, this observation is presented descriptively, and further comparative study of similarly documented cases would help clarify whether this reflects a recognised technical variant or an idiosyncratic feature of this individual's treatment.

Aufderheide (2011) explored several hypotheses for why ancient Egyptian embalmers performed TNC despite its unclear contribution to preservation. First, he proposed that excerebration prevented brain putrefaction from extending to the eyes and facial tissues via the optic nerve; however, examination of spontaneously mummified bodies with intact brains showed no facial disfigurement, suggesting embalmers would have eventually recognised this concern as unfounded. Second, he considered whether TNC accelerated desiccation by removing body water, though the brain's modest water content (~1.2 L) compared to thoracoabdominal organs (~8 L) made

this contribution marginal. Third, he suggested TNC may have persisted as a religious ritual even after losing practical purpose, analogous to the continued use of empty canopic jars in later periods. Fourth, he proposed the nasal channel may have served as a spiritual portal for the Ka and Ba to access the body, similar to "false doors" painted in tombs. Finally, he speculated that the opening might have deliberately attracted insects whose larvae would consume intracranial soft tissues more thoroughly than mechanical removal could achieve. Among these explanations, the religious ritual hypothesis appears most consistent with the present specimen, given the complete excerebration without subsequent filling—a technically demanding procedure with minimal preservative benefit that likely persisted for ceremonial rather than practical reasons.

The absence of cranial resin, combined with the unfilled cavity, suggests this individual belonged to the non-elite social class. The Third Intermediate Period represents a phase of technical innovation in mummification practices. During the 21st Dynasty, embalmers began experimenting with subcutaneous packing techniques aimed at achieving a more lifelike appearance in the deceased (Aufderheide, 2003). However, significant variation existed within this period, as evidenced by individuals whose remains show no subcutaneous packing, minimal linen wrapping, or absence of resinous materials (Loynes, 2015). This variability likely reflects socioeconomic stratification, with individuals receiving minimal treatment probably occupying lower positions in the social hierarchy and possibly dating to the later phases of the period. The introduction of cranial resin, restricted to elite individuals, represented an elaboration of the excerebration ritual designed to signal social distinction (Wade and Nelson, 2013), whereas less affluent individuals typically had their cranial cavities filled with resin-soaked linens or left unfilled (Aufderheide, 2003). Thus, the treatment of the head was conditioned by socioeconomic status, and the present specimen reflects this pattern of non-elite mummification practice within a period of broader technical experimentation. It should be noted, however, that such associations between technique, chronology, and social status are not deterministic. Textual sources — both Egyptian and Graeco-Roman — together with the systematic archaeological study of mummified remains have progressively revealed how far the normative picture of mummification, long dominated by Herodotean accounts, diverges from actual practice. Wade et al.'s (2011) statistical analysis of a sample of 125 mummies demonstrates that no significant differences exist in the distributions of brain treatment techniques between the New Kingdom and the Late Period ($p = 0.628$), suggesting that transitions between prevalent practices were gradual and overlapping rather than abrupt. Transnasal craniotomy, for instance, although reaching its highest prevalence in the Ptolemaic Period, is already documented in a non-negligible proportion of non-elite mummies from the Third Intermediate Period. The methodological implication is that placing a single specimen within a period or a technical category does not entail full conformity to the dominant pattern of that horizon: an individual may have received a more archaic, more advanced, or simply atypical treatment relative to the statistical norm of their chronological context. The interpretation of the techniques observed in the present specimen must therefore account for this structural margin of variability, avoiding overly deterministic readings that would too rigidly tie a single technique to a specific historical period or socioeconomic level.

CT examination revealed several semi-circular inclusions with extremely low-density values (~ −900 HU) within the cranial cavity and posterior region between the skull base and atlas. Their uniform attenuation—comparable to air—suggests intracranial voids or residual desiccation spaces formed after brain removal rather than solid packing or mineralised materials. This interpretation aligns with established mummification practices described by Herodotus and confirmed by modern studies (Abdel-Maksoud and El-Amin, 2011), in which the brain was extracted through the ethmoid plate and the cavity was variably filled with resin, oils, or left partially empty. The air-equivalent inclusions may indicate incomplete filling during embalming, later taphonomic collapse of intracranial tissues, or the presence of low-density organic material (possibly cotton or plant fibre) with air pockets—a finding paralleled in both Egyptian and non-Egyptian contexts. Karlik et al. (2007) identified similar intracranial air pockets and partial preservation of cerebral convolutions in a New Kingdom mummy using MRI, while Hoffman and Hudgins (2002) observed highly variable cranial contents in nine royal mummies, with many showing complete voids corresponding to transnasal excerebration. Saleem and Hawass (2013) reported on twelve royal mummies (18th–20th Dynasties) demonstrating diverse patterns of skull-base openings and variable resin infilling, confirming that the brain cavity was sometimes left unfilled or only partially packed. Gostner et al. (2013) documented comparable low-density materials (−400 to −700 HU) attributed to wool or plant fibre with air pockets in a Peruvian mummy. These observations collectively indicate that intracranial variability reflects deliberate differences in embalming technique, social context, or resource availability rather than post-mortem damage, and considering all the data collected on the mummification techniques employed on this individual, it is more likely that these low-density objects are intracranial voids or residual desiccation spaces formed after brain removal.

The mummification techniques observed in this specimen reflect the progression of embalming practices that began during the early first millennium and continued into the Late Periods (Dunand and Lichtenberg, 2006; Ikram, 2015). From the Middle Kingdom onward, mummification—previously the privilege of royalty—became increasingly accessible to the expanding middle class (Aufderheide, 2003). By the New Kingdom, non-elite mummification was widespread (Wade et al., 2011, 2013; Wade and Nelson, 2013). Excerebration became a standardised feature of the process, and transnasal craniotomy specifically continued until the Saite period (Ikram, 2015). The present specimen's treatment is broadly consistent with this chronological framework and with technical patterns documented among non-elite individuals of the Third Intermediate Period; however, as discussed above, individual technical variability within this period was considerable, and this attribution should be understood as indicating general consistency with, rather than

definitive proof of, non-elite status and Third Intermediate Period dating on technical grounds alone — the radiocarbon result remains the primary basis for chronological placement.

Chemical analysis of the resinous material from the wrappings revealed the presence of vegetable or animal oil in the embalming mixture—most likely of vegetable origin, though from an unknown source. The high percentage of carbon and oxygen confirms the organic nature of the resin, as documented in similar analyses (Łucejko et al., 2017). Although the darkened appearance of the specimen initially suggested bitumen used as a resin substitute, chemical analysis produced conflicting results regarding this material.

Beyond the cranial cavity itself, additional technical observations offer insight into embalming procedures and their potential complications. The tooth fragment detected in the nasopharynx, while unusual, is not unprecedented. Comparable findings have been reported in the mummies of Pharaoh Amenhotep III (Hawass and Saleem, 2016) and an individual from Tomb No. 40 in the Valley of the Kings (Seiler et al., 2022). The most likely explanation is accidental dislodgement during the embalming process, particularly from mechanical manipulation associated with the mouth-opening procedure (Seiler and Rühli, 2015)—distinct from the ritualised "opening of the mouth" ceremony performed during funerary rites. Intravital displacement (e.g., through antemortem trauma) appears unlikely, as there is no radiological evidence of associated soft tissue injury or healing response. Post-excavation or post-collection damage is similarly improbable given the otherwise excellent preservation of the perioral soft tissues, which show no signs of disturbance consistent with recent mechanical interference.

Despite the absence of the postcranial skeleton, which limits reconstruction of the complete mummification protocol, the integrated radiological and compositional evidence demonstrates that this individual received standard non-elite mummification treatment characteristic of the Third Intermediate Period: complete excerebration without resin filling, subtle eye packing to maintain appearance, and vegetable oil-based embalming compounds. These findings contribute to our understanding of socioeconomic variation in mummification practices, exemplifying how funerary practices balanced ritual requirements with economic constraints, maintaining essential ceremonial elements (such as TNC) while omitting costly embellishments (such as cranial resin filling) for non-elite individuals.

4.1 On the provenance of mummy head No. 519-1

The provenance of mummy head No. 519-1 is uncertain and must be considered against the broader context of imprecise geographical attributions characteristic of antiquities collected in the late 19th century. The statement that the mummified head was found during excavations in Memphis is inherently ambiguous and may refer either to the Memphis ruin field or, more generally, to the wider Memphite region extending from the southern outskirts of modern Cairo to the latitude of Meidum and Atfih (Bunbury et al., 2017; Jones, 1996). Although Third Intermediate Period and Late Period material has been documented within the Memphis ruin field, particularly in and around Middle Birka and Kom Tumân—areas associated with the Great Temple of Ptah and the Palace of Apries (Jeffreys, 1985)—these zones are primarily characterised by religious, administrative, and residential activity. No formal burial grounds of substantial scale have been securely identified within the city proper, despite early excavation work conducted by figures such as Joseph Hekekyan, Auguste Mariette, and Flinders Petrie (Jeffreys, 1985; Petrie, 1909). While the presence of small, unrecorded burials within temple precincts cannot be entirely excluded, given the known Late Period practice of interment in sacred enclosures (Dodson, 1988; Stadelmann, 1971), the available archaeological evidence renders the city proper an unlikely point of origin for the head. By contrast, Saqqara—the principal necropolis of ancient Memphis—was the subject of extensive and often poorly documented excavation activity in the mid- to late 19th century, particularly under the direction of Auguste Mariette and his successors (Jeffreys, 1985; Mariette, 1882; Staring, 2017). Across the necropolis, intrusive Late Period burials were frequently encountered within earlier tombs and monuments and were often removed without adequate recording, especially when deemed to be of limited aesthetic or scholarly value (Radomska, 2025; Schneider, 1996). This situation was exacerbated by the flourishing antiquities trade and widespread looting of funerary contexts during the same period (Golénischeff, 1890; Mifflin, 2012; Wolfe and Singerman, 2009). In light of these factors, it is most plausible that mummy head No. 519-1 originated from an intrusive or otherwise undocumented burial at Saqqara or another site within the Memphite region and was subsequently sold in Cairo with the generalised attribution "Memphis", reflecting a commercial, rather than archaeological, designation. Such a transaction would be consistent with the broader antiquities market operating in Cairo during Churilov's documented visits, which included local intermediaries, dealers' shops, and, from the early 1890s, the sale room of the Egyptian Museum itself (see Introduction); however, no archival record identifies the specific channel through which this particular specimen changed hands. Consequently, the original archaeological context of the head cannot be reconstructed with any degree of certainty, and any attempt at more precise localisation must remain speculative.

4.2 Scientific and museological recontextualisation

Conducted within the framework of the Lithuanian Mummy Project (Piombino-Mascali et al., 2014, 2015, 2016, 2017), this research contributes substantially to the reassessment and valorisation of the Egyptian collection housed at the National Museum of Lithuania and, more broadly, to the preservation of Egyptian cultural heritage in the Baltic region. For decades, the mummified head and related artefacts remained unstudied and inaccessible. Through an integrated, non-invasive analytical approach—including CT imaging, three-dimensional reconstruction, and radiocarbon dating—this investigation reactivates a neglected specimen and demonstrates how advanced imaging can yield

new interpretative insights while preserving material integrity. In fact, this work aligns with a broader international trend emphasising the digital and scientific recontextualisation of ancient human remains. Initiatives such as the *Mummies of the World* exhibition illustrate how virtual autopsy and digital visualisation enhance both bioarchaeological interpretation and public engagement (Wieczorek and Rosendahl, 2010). Imaging technologies now function not only as diagnostic tools but also as mechanisms of museological renewal, providing access to collections otherwise restricted by conservation constraints (Cox, 2015; Payne, 2012; Saleem et al., 2023).

In this context, the present study offers a model for the scientific and cultural revitalisation of the Egyptian heritage of the National Museum of Lithuania, currently closed for restoration. The datasets and digital outputs produced can serve as the foundation for future virtual exhibitions and educational initiatives, enabling both specialists and the general public to engage with the material in new ways (e.g., Piombino-Mascali et al., 2021). Ultimately, the mummy head exemplifies how interdisciplinary collaboration and digital innovation can transform neglected artefacts into dynamic sources of knowledge, bridging the domains of conservation, scholarship, and dissemination.

5 Conclusions

The multidisciplinary investigation of mummy head No. 519-1 has provided new insights into selected aspects of the biological profile, oral health, and mummification practices of a young to middle-aged adult male individual whose linen wrappings date to the Third Intermediate Period (816–753 BC). Through CT imaging, radiocarbon dating, chemical analysis, and palaeopathological examination, this study has transformed a previously unstudied museum specimen into a valuable source of information about ancient Egyptian funerary practices and social stratification. Several important caveats, however, qualify the scope of these conclusions. Reconstruction of the individual's overall health status remains limited by the absence of the postcranial skeleton, which precludes assessment of activity patterns or musculoskeletal stress markers. Dietary interpretations rely primarily on general patterns of ancient Egyptian dental wear and attrition rather than on individualised evidence such as isotopic data. Similarly, the specimen's provenance remains speculative and cannot be securely established beyond a plausible association with the broader Memphite region. The principal contribution of this study therefore lies in the detailed, non-destructive documentation of CT findings, radiocarbon dating, and mummification procedures, and in the scientific and museological reassessment of a previously neglected specimen, rather than in a definitive reconstruction of the individual's life history.

In fact, the findings demonstrate that this individual received mummification treatment consistent with non-elite practice as documented for the Third Intermediate Period: complete excerebration through transnasal craniotomy without resin filling, facial packing to maintain appearance, and vegetable oil-based embalming compounds — while acknowledging that considerable technical variability existed within this period and that such classifications should not be read as rigidly deterministic. The severe dental pathology—including extensive attrition, caries, antemortem tooth loss, and periapical abscesses—reflects dietary patterns typical of ancient Egyptians consuming coarse, carbohydrate-rich foods. While the exact cause of death remains uncertain, the advanced periapical abscess could have proven fatal. These findings might contribute to our understanding of socioeconomic variation in mummification practices, confirming technical standardisation of cranial treatment among Egyptians.

This research exemplifies how non-invasive analytical methods can contextualise human remains long silent within museum storerooms, enabling reconstruction of provenance, dating, and biological identity without compromising specimen integrity. This approach transforms curated human remains from static relics into dynamic resources serving both scientific inquiry and public engagement.

From a museological perspective, this investigation enriches the Egyptian collection of the National Museum of Lithuania and contributes to the Lithuanian Mummy Project's mission of studying mummified remains through ethical, non-destructive methodologies. The study demonstrates that even fragmentary or poorly documented specimens retain significant research potential when approached with appropriate analytical frameworks, offering a model for balancing scientific investigation with conservation imperatives and cultural sensitivity.

Future research directions could include micro-CT analysis of intracranial materials, molecular analysis of embalming oils to identify botanical sources, and isotopic analysis of preserved tissues to refine dietary and mobility patterns—investigations that would further illuminate this individual's life history and the broader contexts of Third Intermediate Period Egypt.

Data availability statement

The datasets presented in this study can be found in online repositories. The names of the repository/repositories and accession number(s) can be found in the article/Supplementary Material.

Author contributions

RM: Conceptualization, Data curation, Formal analysis, Funding acquisition, Investigation, Methodology, Writing – original draft, Writing – review & editing. IS: Investigation, Methodology, Resources, Writing – review & editing. AD: Formal analysis, Investigation, Methodology, Writing – review & editing. RG: Formal analysis, Investigation, Methodology, Software, Writing – review & editing. AT: Formal analysis, Software, Writing – review & editing. PD: Data curation, Investigation, Validation, Writing – review & editing. DP-M: Conceptualization, Data curation, Formal analysis, Investigation, Methodology, Resources, Supervision, Validation, Visualization, Writing – review & editing.

Funding

The author(s) declared that financial support was received for this work and/or its publication. This research was supported by funding from the Erasmus+ Traineeship Programme, which enabled the first author to undertake a two-month research stay at Vilnius University (Vilnius, Lithuania), during which the specimen was examined and this study was conducted. Open access funding was provided by the Science and Innovation Center, Faculty of Medicine, Vilnius University.

Acknowledgments

We would like to thank Tadas Šėma, Senior Curator at the National Museum of Lithuania, for his support of this study and for coordinating the professional transport of the artefact.

Conflict of interest

The author(s) declared that this work was conducted in the absence of any commercial or financial relationships that could be construed as a potential conflict of interest.

Correction Note

This article has been corrected with minor changes. These changes do not impact the scientific content of the article.

Generative AI statement

The author(s) declared that generative AI was not used in the creation of this manuscript.

Any alternative text (alt text) provided alongside figures in this article has been generated by Frontiers with the support of artificial intelligence and reasonable efforts have been made to ensure accuracy, including review by the authors wherever possible. If you identify any issues, please contact us.

Publisher's note

All claims expressed in this article are solely those of the authors and do not necessarily represent those of their affiliated organizations, or those of the publisher, the editors and the reviewers. Any product that may be evaluated in this article, or claim that may be made by its manufacturer, is not guaranteed or endorsed by the publisher.

References

Abdel-Maksoud, G., and El-Amin, A. R. (2011). A review on the materials used during the mummification processes in ancient Egypt. *Mediterr. Archaeol. Archaeom.* 11 (2), 129–150.

AlQahtani, S. J., Hector, M. P., and Liversidge, H. M. (2010). The London atlas of human tooth development and eruption. *Am. J. Phys. Anthropol.* 142, 481–490. doi: 10.1002/ajpa.21258

Andrews, C. (2004). *Egyptian Mummies: Revised Edition*. Cambridge, MA: Harvard University Press.

Aufderheide, A. C. (2003). *The Scientific Study of Mummies*. Cambridge: Cambridge University Press.

Aufderheide, A. C. (2011). The enigma of ancient Egyptian excerebration. *Yearb. Mummy Stud.* 1, 7–10.

Aufderheide, A. C., Nissenbaum, A., and Cartmell, L. (2004). Radiocarbon date recovery from bitumen-containing Egyptian embalming resins. *JSSEA* 31, 87–96.

Beckett, R. G. (2014). Paleoimaging: a review of applications and challenges. *Forensic Sci. Med. Pathol.* 10 (3), 423–436. doi: 10.1007/s12024-014-9541-z

Brier, B. (1994). *Egyptian Mummies: Unraveling the Secrets of an Ancient Art*. New York: William Morrow.

Brier, B., and Wade, R. S. (2001). Surgical procedures during ancient Egyptian mummification. *Chungará (Arica)* 33, 117–123. doi: 10.4067/S0717-73562001000100021

Brier, B., and Wade, R. S. (2005). Tools of the ancient Egyptian embalmers. *J. Biol. Res.* 80, 159–163. doi: 10.4081/jbr.2005.10173

Bronk Ramsey, C. (2009). Bayesian analysis of radiocarbon dates. *Radiocarbon* 51, 337–360. doi: 10.1017/S0033822200033865

Buckley, S. A., and Evershed, R. P. (2001). Organic chemistry of embalming agents in pharaonic and Graeco-Roman mummies. *Nature* 413, 837–841. doi: 10.1038/35101588

Buckley, S. A., Stott, A. W., and Evershed, R. P. (1999). Studies of organic residues from ancient Egyptian mummies using high temperature GCMS and sequential thermal desorption GCMS and pyrolysis GCMS. *Analyst* 124, 443–452. doi: 10.1039/a809022j

Bunbury, J., Tavares, A., Pennington, B., and Gonçalves, P. (2017). "Development of the Memphite floodplain: landscape and settlement symbiosis in the Egyptian capital zone," in *The Nile: Natural and Cultural Landscape in Egypt*, eds. H. Willems, and J.-M. Dahms (Bielefeld: Transcript), 71–96.

Çelik, N., and Emin Dogan, M. (2024). Comparison of mineral density of dental structures of ancient human skeletons from the Roman period with modern-day human dental structures. *J. Clin. Densitom.* 27 (4), 101527. doi: 10.1016/j.jocd.2024.101527

Clark, K. A., Ikram, S., and Evershed, R. P. (2016). The significance of petroleum bitumen in ancient Egyptian mummies. *Philos. Trans. A Math. Phys. Eng. Sci.* 374, 20160229. doi: 10.1098/rsta.2016.0229

Colombini, M. P., Modugno, F., Silvano, F., and Onor, M. (2000). Characterization of the balm of an Egyptian mummy from the seventh century B.C. *Stud. Conserv.* 45, 19–29. doi: 10.1179/sic.2000.45.1.19

Cox, S. L. (2015). A critical look at mummy CT scanning. *Anat. Rec. (Hoboken)* 298, 1099–1110. doi: 10.1002/ar.23149

Deikun, V. (2018). "Оружие воинов махди" в собрании Государственного музея истории религии. *Tr. GMIR* 18, 104–116.

Devenney-Cakir, B., Subramaniam, R. M., Reddy, S. M., Imsande, H., Gohel, A., and Sakai, O. (2011). Cystic and cystic-appearing lesions of the mandible: review. *Am. J. Roentgenol.* 196, S45–S91. doi: 10.2214/AJR.09.7216

Dias, G., and Tayles, N. (1997). 'Abscess cavity'—a misnomer. *Int. J. Osteoarchaeol.* 7, 548–554. doi: 10.1002/(SICI)1099-1212(199709/10)7:5<548::AID-OA369>3.0.CO;2-I

Dodson, A. (1988). Some notes concerning the royal tombs at Tanis. *Chron. Égypte* 63 (126), 221–233. doi: 10.1484/j.cde.2.308777

Dunand, F., and Lichtenberg, R. (1994). *Mummies: A Voyage Through Eternity*. New York: Abrams.

Dunand, F., and Lichtenberg, R. (2006). *Mummies and Death in Egypt*. Ithaca: Cornell University Press.

Evershed, R., Van Bergen, P., Peakman, T. M., Leigh-Firbank, E. C., Horton, M. C., Edwards, D., et al. (1997). Archaeological frankincense. *Nature* 390, 667–668. doi: 10.1038/37741

Forshaw, R. J. (2009). Dental health and disease in ancient Egypt. *Br. Dental J.* 206 (8), 421–424. doi: 10.1038/sj.bdj.2009.309

Forshaw, R. J. (2014). Dental indicators of ancient dietary patterns: dental analysis in archaeology. *Br. Dental J.* 216 (9), 529–535. doi: 10.1038/sj.bdj.2014.353

Gerasimenko, V. A., Kirilenko, A. V., and Nabivach, V. M. (1981). Capillary gas chromatography of aromatic compounds found in coal tar fractions. *J. Chromatogr.* 208, 9–16. doi: 10.1016/S0021-9673(00)87953-4

Golénischeff, V. (1890). Археологическіе результаты путешествія по Египту зимой 1888–1889 г. *Записки Восточного Отделения Императорского Русского Археологического Общества* 5, 1–30.

Gostner, P., Bonelli, M., Pernter, P., Graefen, A., and Zink, A. (2013). New radiological approach for analysis and identification of foreign objects in ancient and historic mummies. *J. Archaeol. Sci.* 40, 1003–1011. doi: 10.1016/j.jas.2012.10.011

Hagen, F., and Ryholt, K. (2016). The antiquities trade in Egypt 1880–1930: the H.O. Lange papers. *Scient. Dan. Ser. H, Humanistica* 4, 44–49.

Hamm, S., Bleton, J., and Tchapla, A. (2004). Headspace solid phase microextraction for screening for the presence of resins in Egyptian archaeological samples. *J. Sep. Sci.* 27, 235–243. doi: 10.1002/jssc.200301611

Harris, J. E., and Wente, E. F. (1980a). *An X-ray Atlas of the Royal Mummies*. Chicago: University of Chicago Press.

Harris, J. E., and Wente, E. F. (1980b). "Dental disease in the royal mummies," in *An X-ray Atlas of the Royal Mummies*, eds. J.E. Harris, and E.F. Wente (Chicago: University of Chicago Press), 328–345.

Hawass, Z., and Saleem, S. N. (2016). *Scanning the Pharaohs: CT Imaging of the New Kingdom Royal Mummies*. Cairo: American University in Cairo Press.

Hillson, S. (2023). *Dental Anthropology*. 2nd ed. Cambridge: Cambridge University Press, 403–408.

Hoffman, H., and Hudgins, P. A. (2002). Head and skull base features of nine Egyptian mummies. *Am. J. Roentgenol.* 178, 1367–1376. doi: 10.2214/ajr.178.6.1781367

Hornung, E., Krauss, R., and Warburton, D. A. (2006). *Ancient Egyptian Chronology*. Leiden/Boston: Brill, 494.

Huber, B., Hammann, S., Loeben, C. E., Jha, D. K., Vassão, D. G., Larsen, T., et al. (2023). Biomolecular characterization of 3500-year-old ancient Egyptian mummification balms from the Valley of the Kings. *Sci. Rep.* 13, 12477. doi: 10.1038/s41598-023-39393-y

Ikram, S. (2015). *Death and Burial in Ancient Egypt*. Cairo: American University in Cairo Press.

Ikram, S., and Dodson, A. (1998). *The Mummy in Ancient Egypt: Equipping the Dead for Eternity*. London: Thames and Hudson.

Jeffreys, D. G. (1985). *The Survey of Memphis I: The Archaeological Report*. London: Egypt Exploration Society.

Jones, M. (1996). A Roman station at Abu-Rawash. *MDAIK* 52, 251–262.

Karlik, S. J., Bartha, R., Kennedy, K., and Chhem, R. (2007). MRI and multinuclear MR spectroscopy of a 3,200-year-old Egyptian mummy brain. *Am. J. Roentgenol.* 189, W105–W110. doi: 10.2214/AJR.07.2087

Key, C. A., Aiello, L. C., and Molleson, T. (1994). Cranial suture closure and its implications for age estimation. *Int. J. Osteoarchaeol.* 4 (3), 193–207. doi: 10.1002/oa.1390040304

Leek, F. F. (1966). Observations on the dental pathology seen in ancient Egyptian skulls. *J. Egypt. Archaeol.* 52, 59–64. doi: 10.1177/030751336605200109

Lovejoy, C. O., Meindl, R. S., Mensforth, R. P., and Barton, T. J. (1985). Multifactorial determination of skeletal age at death: a method and blind tests of its accuracy. *Am. J. Phys. Anthropol.* 68, 1–14. doi: 10.1002/ajpa.1330680102

Loynes, R. (2015). *Prepared for Eternity: A Study of Human Embalming Techniques in Ancient Egypt Using Computerised Tomography Scans of Mummies*. Oxford: Archaeopress.

Łucejko, J., Connan, J., Orsini, S., Ribechini, E., and Modugno, F. (2017). Chemical analyses of Egyptian mummification balms and organic residues from storage jars dated from the Old Kingdom to the Copto-Byzantine period. *J. Archaeol. Sci.* 85, 1–12. doi: 10.1016/j.jas.2017.06.015

Mariette, A. (1882). *Le Sérapeum de Memphis, 2 Vols*. ed. G. Maspero. Paris: Vieweg.

Meindl, R. S., and Lovejoy, C. O. (1985). Ectocranial suture closure: a revised method for the determination of age at death based on the lateral-anterior sutures. *Am. J. Phys. Anthropol.* 68, 57–66. doi: 10.1002/ajpa.1330680106

Melcher, A. H., Holowka, S., Pharaoh, M., and Lewin, P. K. (1997). Non-invasive computed tomography and three-dimensional reconstruction of the dentition of a 2,800-year-old Egyptian mummy exhibiting extensive dental disease. *Am. J. Phys. Anthropol.* 103, 329–340. doi: 10.1002/(SICI)1096-8644(199707)103:3<329::AID-AJPA3>3.0.CO;2-L

Mifflin, J. (2012). Book review: Mummies in nineteenth century America: ancient Egyptians as artifacts, by S.J. Wolfe and R. Singerman. *Am. J. Archaeol.* 116, 4. doi: 10.3764/ajaonline1164.Mifflin

Mikhailenko, P., Bertron, A., and Ringot, E. (2016). "Methods for analyzing the chemical mechanisms of bitumen aging and rejuvenation with FTIR spectrometry," in *8th RILEM International Symposium on Testing and Characterization of Sustainable and Innovative Bituminous Materials, RILEM Bookseries 11*, eds. F. Canestrari, and M.N. Partl (Dordrecht: Springer), 203–214. doi: 10.1007/978-94-017-7342-2_17

Miller, J. (2008). "Dental health and disease in ancient Egypt," in *Egyptian Mummies and Modern Science*, ed. R. David (Cambridge: Cambridge University Press), 52–70.

Molnar, S. (1971). Human tooth wear, tooth function and cultural variability. *Am. J. Phys. Anthropol.* 34 (2), 175–189. doi: 10.1002/ajpa.1330340204

Molnar, S., Barrett, M. J., Brian, L., Brace, C. L., Brose, D. S., Dewey, J. R., et al. (1972). Tooth wear and culture: a survey of tooth functions among some prehistoric populations. *Curr. Anthropol.* 13 (5), 511–526. doi: 10.1086/201284

Nickol, T., Germer, R., Lieberenz, S., Schmidt, F., and Wilke, W. (1995). An examination of the dental state of an Egyptian mummy by means of computer tomography: a contribution to 'dentistry in ancient Egypt'. *J. Hist. Dent.* 43, 105–112.

Payne, E. M. (2012). Imaging techniques in conservation. *J. Conserv. Mus. Stud.* 10, 17–29. doi: 10.5334/jcms.1021201

Petrie, W. M. F. (1909). *The Palace of Apries (Memphis II)*. London: British School of Archaeology in Egypt.

Piombino-Mascali, D., McKnight, L., and Jankauskas, R. (2014). Ancient Egyptians in Lithuania: a scientific study of the Egyptian mummies at the National Museum of Lithuania and the M. K. Čiurlionis National Museum of Art. *Papers Anthropol.* 23 (1), 127–134. doi: 10.12697/poa.2014.23.1.11

Piombino-Mascali, D., McKnight, L., Snitkuvienė, A., Jankauskas, R., Tamošiūnas, A., Valančius, R., et al. (2015). "From Egypt to Lithuania: Marija Rudzinskaitė-Arcimavičienė's mummy and its radiological investigation," in *Egyptian Bioarchaeology: Humans, Animals and the Environment*, eds. S. Ikram, J. Kaiser, and R. Walker (Leiden: Sidestone Press), 95–104.

Piombino-Mascali, D., Jankauskas, R., Snitkuvienė, A., Rutkauskas, T., and Sutherland, M. L. (2016). Radiological and archaeological investigation of a mummy from Roman Egypt curated in the National Museum of Lithuania. *Anthropol. Anz.* 73 (1), 69–79. doi: 10.1127/anthranz/2016/0593

Piombino-Mascali, D., Jankauskas, R., Snitkuvienė, A., Ikram, S., and Sutherland, M. L. (2017). On the human remains contained in count Aleksander Branicki's Egyptian coffin. *J. Anc. Egypt. Interconnect.* 15 (1), 11–17.

Piombino-Mascali, D., Jankauskas, R., and Tarasenko, M. (2021). What's hidden in the sarcophagus. The first-ever Lithuanian mummy exhibition (2021–2022). *JHIE* 4, 141–144. doi: 10.5281/zenodo.5775613

Radomska, M. (2025). Covering the deceased's heads with pottery vessels: insight from late and Ptolemaic period necropolis in Saqqara West. *Études Trav.* 38, 219–241. doi: 10.12775/EtudTrav.38.009

Reimer, P. J., Austin, W. E. N., Bard, E., Bayliss, A., Blackwell, P. G., Bronk Ramsey, C., et al. (2020). The IntCal20 northern hemisphere radiocarbon age calibration curve (0–55 cal kBP). *Radiocarbon* 62 (4), 725–757. doi: 10.1017/RDC.2020.41

Ribechini, E., Orsini, S., Silvano, F., and Colombini, M. P. (2009). Py-GC/MS, GC/MS and FTIR investigations on late Roman-Egyptian adhesives from opus sectile: new insights into ancient recipes and technologies. *Anal. Chim. Acta* 638, 79–87. doi: 10.1016/j.aca.2009.02.004

Rustenhoven, J., Drieu, A., Mamuladze, T., De Lima, K. A., Dykstra, T., Wall, M., et al. (2021). Functional characterization of the dural sinuses as a neuroimmune interface. *Cell* 184 (4), 1000–1016. doi: 10.1016/j.cell.2020.12.040

Saleem, S. N., and Hawass, Z. (2013). Variability in brain treatment during mummification of royal Egyptians dated to the 18th–20th dynasties: MDCT findings correlated with the archaeologic literature. *Am. J. Roentgenol.* 200 (4), W336–W344. doi: 10.2214/AJR.12.9405

Saleem, S. N., Seddik, S. A., and El-Halwagy, M. (2023). Scanning and three-dimensional-printing using computed tomography of the "golden boy" mummy. *Front. Med.* 9, 1028377. doi: 10.3389/fmed.2022.1028377

Schneider, H. D. (1996). *The Memphite Tomb of Ḥ.oremḥ.eb, Commander-in-chief of Tut'ankhamūn II: A Catalogue of the Finds*. London: Egypt Exploration Society.

Schwartz, J. H. (2007). *Skeleton Keys: An Introduction to Human Skeletal Morphology, Development, and Analysis*. 2nd ed. Oxford: Oxford University Press.

Seiler, R., Eppenberger, P., Bickel, S., and Rühli, F. (2022). The importance of the nasopharynx and anterior skull base in excerebration techniques from KV40, a New Kingdom Egyptian site. *Anat. Rec. (Hoboken)* 305, 1938–1946. doi: 10.1002/ar.24828

Seiler, R., and Rühli, F. (2015). The "opening of the mouth": a new perspective for an ancient Egyptian mummification procedure. *Anat. Rec. (Hoboken)* 298, 1208–1216. doi: 10.1002/ar.23140

Snitkuvienė, A. (2011). *Lietuva ir senovės Egiptas (XVI a. pab. – XXI a. prad.). Keliautojų, kolekcininkų ir mokslininkų pėdsakais*. Kaunas: Nacionalinis M. K. Čiurlionio dailės muziejus.

Squires, K., Davidson, A., Cooper, S., Viner, M., Hoban, W., Loynes, R., et al. (2024). A multidisciplinary investigation of a mummified Egyptian head and analysis of its associated resinous material from the Salinas Regional Archaeological Museum in Palermo (Sicily). *J. Archaeol. Sci. Rep.* 55, 104525. doi: 10.1016/j.jasrep.2024.104525

Stadelmann, R. (1971). Das Grab im Tempelhof: der Typus des Königsgrabes in der Spätzeit. *MDAIK* 27, 111–123.

Staring, N. (2017). "The mid-nineteenth century exploration of the Saqqara New Kingdom necropolis," in *Imaging and Imagining the Memphite Necropolis: Liber Amicorum René van Walsem*, eds. V. Verschoor, A.J. Stuart, and C. Demarée (Leiden: Nederlands Instituut voor het Nabije Oosten), 95–113.

Thekkaniyil, J. K., Bishara, S., and James, M. (2000). Dental and skeletal findings on an ancient Egyptian mummy. *Am. J. Orthod. Dentofacial Orthop.* 117 (1), 10–14. doi: 10.1016/s0889-5406(00)70242-3

Vandenbeusch, M., Stacey, R., and Antoine, D. (2021). Rediscovering Nestawedjat: embalming residue analyses reunite the mummified remains of an ancient Egyptian woman with her coffins. *J. Archaeol. Sci. Rep.* 40, 103186. doi: 10.1016/j.jasrep.2021.103186

Villa, C., and Lynnerup, N. (2012). Hounsfield units ranges in CT-scans of bog bodies and mummies. *Anthropol. Anz.* 69 (2), 127–145. doi: 10.1127/0003-5548/2012/0139

Wade, A. D., Nelson, A. J., and Garvin, G. J. (2011). A synthetic radiological study of brain treatment in ancient Egyptian mummies. *Homo* 62 (4), 248–269. doi: 10.1016/j.jchb.2011.01.004

Wade, A. D., and Nelson, A. J. (2013). Radiological evaluation of the evisceration tradition in ancient Egyptian mummies. *Homo* 64 (4), 1–28. doi: 10.1016/j.jchb.2012.11.005

Wade, A. D., Nelson, A. J., and Garvin, G. J. (2013). Evisceration and excerebration in the Egyptian mummification tradition. *J. Archaeol. Sci.* 40 (2), 4198–4206. doi: 10.1016/j.jas.2013.06.017

White, T. D., Black, M. T., and Folkens, P. A. (2012). *Human Osteology*. London: Academic Press.

Wieczorek, A., and Rosendahl, W. (2010). *Mummies of the World*. Munich: Prestel.

Wolfe, S. J., and Singerman, R. (2009). *Mummies in Nineteenth Century America: Ancient Egyptians as Artifacts*. Jefferson: McFarland & Co.

Wysocka, J., Riley, E., and Cieślik, A. (2025). Association of arachnoid fossae and endocranial lesions in a historical population from Poland: new diagnostic possibilities. *Sci. Rep.* 15, 6109. doi: 10.1038/s41598-025-89939-5

Yatsishina, K. B., Pozhidaev, V. M., Vasilyeva, O. A., Dyuzheva, O. P., Sergeeva, Y. E., Retivov, Y. M., et al. (2019). The determination of the origin of natural bitumen in mummifying resins of ancient Egyptian mummies from the collection of the Pushkin Museum of Fine Arts. *Fine Chem. Technol.* 14, 45–58. doi: 10.32362/2410-6593-2019-14-4-45-58