Heliyon 12 (2026) e45210

Contents lists available at ScienceDirect

Heliyon

journal homepage: www.cell.com/heliyon

Case report

Multiple cutaneous melanomas in a patient with Li-Fraumeni syndrome: A case report

Monika Rimdeikaite [a,*], Tomas Petras Vileikis [b], Domantas Stundys [b]

[a] Vilnius University, Faculty of Medicine, Vilnius, LT-03101, Lithuania
[b] Vilnius University, Faculty of Medicine, Institute of Clinical Medicine, Vilnius, LT-03101, Lithuania

A B S T R A C T

Li-Fraumeni syndrome (LFS) is a rare genetic condition associated with an increased predisposition to various malignancies due to a mutation in the TP53 tumour-suppressor gene. The typical LFS tumour spectrum includes osteosarcoma, soft tissue sarcoma, pre-menopausal breast cancer, brain tumours and adrenocortical carcinoma. Although melanoma is not a hallmark of LFS, sporadic cases have been described in the literature. This article reports a patient with genetically confirmed Li-Fraumeni syndrome carrying the pathogenic TP53 NM_000546.5: c.357delC (p.Lys120Serfs*3) variant, who developed three primary cutaneous melanomas in addition to several classical LFS-associated malignancies. While cutaneous tumours are not part of the typical LFS spectrum, the increased risk of multiple malignancies in LFS patients underscores the importance of annual dermatological examinations.

1. Introduction

1.1. Li-Fraumeni syndrome and associated malignancies

Li-Fraumeni syndrome (LFS) is a rare autosomal dominant condition associated with an increased lifetime cancer risk due to the mutation in the TP53 tumour-suppressor gene [1] (Fig. 1). The affected gene encodes for a p53 protein, a crucial regulator of cell apoptosis. Due to the disruption of the normal cell cycle, the condition is associated with a higher incidence of cancer, mainly presenting at an early age. The core tumour spectrum associated with Li-Fraumeni syndrome (LFS) includes osteosarcoma, soft tissue sarcoma, brain tumours, premenopausal breast cancer, and adrenocortical carcinoma. These malignancies account for the majority of early-onset cancers observed in this patient population [2,3]. Among them, the most common by cumulative incidence up to the age of 70 are breast cancer in females (54%), soft tissue sarcomas (15% in females and 22% in males), brain tumours (6% in females and 11% in males), and osteosarcoma (5% in females and 11% in males) [4]. In addition to the most common tumour types, lung cancer and lymphoma are also recognized within the core LFS tumour spectrum. Nevertheless, LFS patients are at increased risk of developing virtually any malignancy.

Although cutaneous malignancies are not traditionally considered hallmark features of LFS, emerging data and case reports suggest that it may occur more frequently than previously recognized, supporting the inclusion of regular dermatologic screening in long-term care protocols [5–12]. Given the overall increased cancer risk in LFS patients, melanocytic lesions may represent a significant concern and warrant close surveillance.

The aim of this case report is to describe a rather unusual presentation of multiple primary melanomas in a patient with genetically confirmed Li-Fraumeni syndrome, as well as to emphasize the importance of regular dermatological surveillance in this high-risk

* Corresponding author. M. K. Ciurlionio gatve 21, Vilnius, LT-03101, Lithuania.
E-mail address: monika.rimdeikaite@mf.stud.vu.lt (M. Rimdeikaite).

https://doi.org/10.1016/j.heliyon.2026.e45210
Received 20 August 2024; Received in revised form 10 July 2026; Accepted 14 July 2026
Available online 16 July 2026
2405-8440/© 2026 The Authors. Published by Elsevier Ltd. This is an open access article under the CC BY license (http://creativecommons.org/licenses/by/4.0/).

patient population.

1.2. The diagnosis of Li-Fraumeni syndrome

The definitive diagnosis of Li-Fraumeni syndrome (LFS) is established through the identification of a pathogenic germline mutation in the TP53 gene. Clinical criteria, such as the classic LFS criteria and the more inclusive Chompret criteria [13], are used to identify individuals who should be offered genetic testing. The classic criteria typically involve the presence of a sarcoma diagnosed before the age of 45, a first-degree relative with any cancer before age 45, and another first- or second-degree relative with either any cancer before age 45 or a sarcoma at any age. The Chompret criteria expand upon these to capture individuals who may not meet the classic definition but are still at elevated risk. Given the serious implications of the syndrome, early genetic confirmation is essential for guiding surveillance strategies and improving outcomes by enabling the early detection and management of associated malignancies throughout a patient's lifetime.

1.3. Treatment options

For patients with Li-Fraumeni syndrome (LFS), treatment options generally align with standard cancer therapies and include

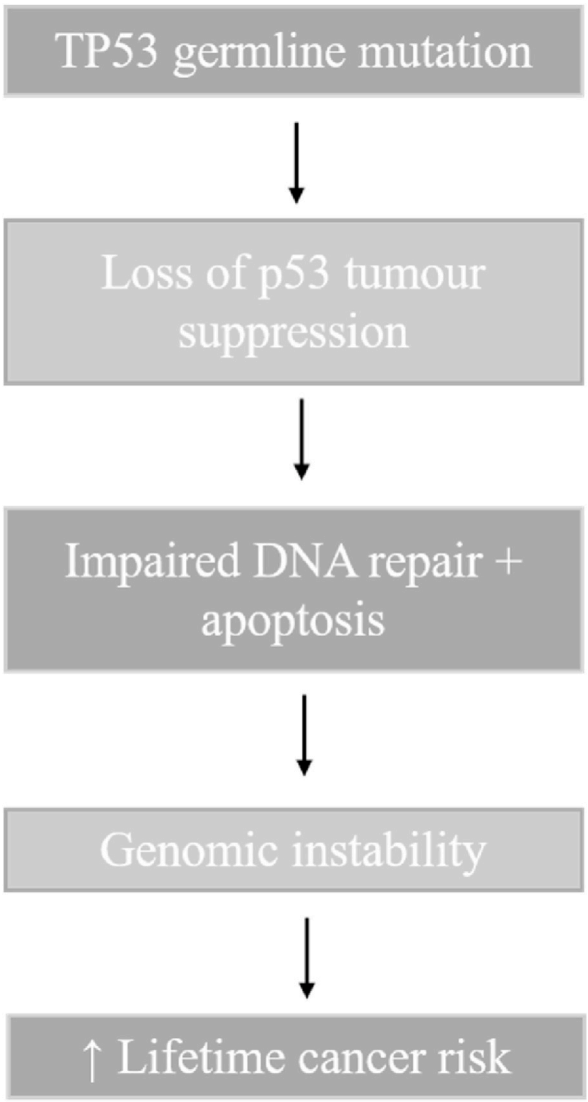

Fig. 1. Schematic overview of pathogenesis of Li-Fraumeni syndrome. Germline pathogenic variants in the TP53 gene result in loss of normal p53 tumour suppressor function, leading to impaired DNA repair, defective apoptosis, genomic instability, and an increased lifetime risk of multiple malignancies.

surgery, chemotherapy, hormone therapy, and immunotherapy. According to the literature, these treatment modalities remain fundamental in managing malignancies associated with LFS and are expected to retain their relevance in the future [14]. In contrast to standard oncologic practice, radiotherapy is typically avoided in this patient population due to their heightened sensitivity to ionizing radiation and the associated increased risk of secondary malignancies.

Nevertheless, such therapies primarily address the clinical consequences of the syndrome rather than its underlying genetic basis. While there are currently no approved targeted therapies for TP53 mutation carriers, emerging studies suggest that metformin—a widely used antidiabetic agent [15]—and Sechium extract, a polyphenol-rich compound with reported anti-inflammatory and anti-neoplastic properties [16], may warrant further investigation as potential adjunctive interventions in the future. However, these agents remain investigational and were not used in the management of the patient described in this case report.

1.4. Case/case series presentation

Informed patient consent in written form was obtained for publication of this case report.

A 30-year-old male presenting with a 2.1 × 0.9 cm pigmented atypical naevus was referred to Vilnius University Hospital Santaros Klinikos Centre of Dermatovenereology for primary consultation. The patient's medical history revealed a diagnosis of left fibular osteosarcoma at the age of 12 with a relapse at the age of 15, leading to an amputation of the lower left limb. At 19 years of age, the patient was diagnosed with histologically confirmed cutaneous melanoma with liver metastasis (Breslow 1.9 mm, pT2a, Clark Level IV, BRAF+). No new oncologic diseases were documented between the age of 19 and 25 years old. At 25 years of age, he was diagnosed with superficial spreading melanoma (Breslow 1.4 mm, pT2a, Clark Level IV, BRAF-). At the age of 26, a right forearm leiomyosarcoma was diagnosed, which was followed by the diagnosis of leiomyosarcoma of the left proximal humerus and the right knee at 29 years of age. The following year, the patient was diagnosed with melanoma in situ (pTis) of the lower left residual limb. Each intervention was determined by the treating physician and tailored to the patient's specific clinical needs. In certain cases (ages 12, 15, and 29), a combination of surgery and chemotherapy was necessary to achieve the optimal therapeutic outcome (Table 1). However, in other cases (ages 19, 25, 26, 29 and 30), surgery alone proved sufficient as the primary treatment approach.

During the intervals between the different cancers, the patient was periodically monitored by his general practitioner as well as by the specialists who were managing the previous cancer treatments. This follow-up process included routine evaluations and screenings, such as an annual physical examination, as well as annual whole-body magnetic resonance imaging (MRI), to ensure early detection and management of any new malignancies. Additionally, the analysis of the patient's family history revealed a malignant brain tumour, an LFS-associated malignancy, diagnosed in his mother at 34 years of age.

Considering the numerous malignancies arising at an early age, as well as a first-degree relative diagnosed with cancer before the age of 45, the patient was referred to a genetic consultation. The genetic analysis revealed a TP53 mutation NM_000546.5: c.357delC (p.Lys120Serfs*3) in exon 4; therefore, the diagnosis of Li-Fraumeni syndrome at 30 years of age was confirmed. As commonly observed in other LFS patients, the syndrome initially manifested as osteosarcoma and leiomyosarcoma. However, these malignancies were followed by multiple diagnoses of cutaneous melanoma, which is not a typical finding in LFS patients.

Upon referral, the patient's medical history was considered prior to initiating the treatment of the pigmented lesion. Due to the patient's genetic condition and previous diagnosis of melanoma at an early age, surgical removal of the naevus was a first-choice intervention, enabling the histological examination of the lesion. Surgical excision of the pigmented lesion was performed under local anaesthesia using lidocaine. The specimen was submitted for histopathological examination, which confirmed an atypical Spitz

Table 1
Summary of Patient's Cancer History and Treatments. Each intervention was determined based on the treating physician's judgment, tailored to the patient's needs. The data were collected from the patient's medical records.

Year	Age at Diagnosis	Diagnosis	Affected area	Intervention	Treatment outcomes
2004	12	Osteosarcoma	Left fibula	Surgery, chemotherapy	Complete remission until local recurrence in 2008
2008	15	Osteosarcoma - relapse	Left fibula	Amputation, chemotherapy	Local disease controlled. No further osteosarcoma recurrence
2011	19	Cutaneous melanoma	Back region Liver metastasis	Surgery	No evidence of local recurrence. New primary malignancies
2017	25	Cutaneous melanoma	Scalp	Surgery	Complete excision achieved
2018	26	Leiomyosarcoma	Right forearm	Surgery	Complete excision achieved
2021	29	Leiomyosarcoma	Left proximal humerus	Surgery	Complete excision achieved
2021	29	Leiomyosarcoma	Right knee	Amputation, chemotherapy (Gemcitabine and docetaxel, 3 cycles).	Disease controlled
2022	30	Cutaneous melanoma in situ	Lower left residual limb	Surgery	Complete excision achieved
2022	30	Spitz naevus	Back region	Surgery	Complete excision. No further treatment required

CARE checklist: Items 8b, 8d, 9b, 9c, 10a, 10d from CARE checklist are not applicable in this case report, because there were no diagnostic challenges due to access to testing, financial or cultural reasons. Items involving prognosis, administration, changes and tolerability of therapeutic intervention, as well as patient-assessed outcomes were not applicable. There were no adverse or unanticipated events.

naevus without evidence of malignancy. The post-operative course was uncomplicated, with satisfactory wound healing, and no additional adjuvant treatment was required.

2. Discussion

2.1. LFS and melanoma in the literature

A literature review was conducted using the PubMed and Google Scholar databases to examine the frequency of cutaneous melanoma in Li-Fraumeni patients. Based on the literature, there are currently no published articles addressing the association between the patient's identified TP53 mutation NM_000546.5: c.357delC (p.Lys120Serfs*3) and melanoma. Additionally, melanoma remains a controversial feature of LFS [5]. So far, only sporadic cases of melanoma have been associated with this syndrome; therefore, cutaneous malignancies are not considered to be the hallmarks of LFS [5–10]. Several discussions have been published on whether melanoma should be included in the LFS criteria, stating that due to an increased risk of various malignancies, LFS patients might be more susceptible to developing melanoma; nonetheless, systematic analyses supporting this hypothesis are limited [11]. A recently published Dutch cohort study reported an increased risk of melanoma in LFS patients—1.5% by age 40 compared to 0.3% in the general population, as well as 12.6% in LFS versus 2.47% in general population by the age of 70 [12]; however, more data are needed to reach a consensus.

2.2. Potential biological mechanisms between LFS and melanoma

While the TP53 mutation is a key component of LFS, melanoma is not typically associated with this mutation. The development of melanoma is more often influenced by environmental factors such as ultraviolet (UV) radiation, or by mutations in other genes, including BRAF and NRAS [17]. Under normal circumstances, functional TP53 plays a crucial role in detecting DNA damage caused by UV exposure, initiating DNA repair mechanisms and triggering apoptosis in damaged cells.

However, in the presence of a TP53 mutation (as in LFS), these protective processes are compromised, allowing damaged cells to survive and potentially give rise to malignancies such as melanoma. Although melanoma is not commonly linked to TP53 mutations, increasing number of case reports suggest that a combination of external factors (e.g., UV radiation) and additional genetic alterations may contribute to its occurrence in LFS patients. This growing body of evidence warrants further investigation.

2.3. Current guidelines

Considering the increased predisposition of LFS patients to a broad spectrum of malignancies, including those outside the classic LFS tumour profile, the National Comprehensive Cancer Network (NCCN) in the United States has proposed detailed recommendations regarding LFS patient surveillance frequency [18]. These guidelines include a comprehensive physical and neurological examination every 6 to 12 months, annual whole-body and brain MRI, colonoscopy every 2 to 5 years, and yearly dermatological evaluations, beginning at 18 years of age. The importance of annual dermatological screening is further supported by the Toronto protocol [19].

2.4. Early detection of genetic mutations

Genetic screening plays a pivotal role in the management of LFS by enabling early identification of TP53 mutations, thereby influencing treatment strategies and clinical outcomes for affected individuals [20]. In the present case, the patient's mother was diagnosed with a malignant brain tumour at the age of 34, and the patient himself was diagnosed with osteosarcoma at the age of 12. These factors suggest that an earlier diagnosis of LFS could have been possible.

Although no curative treatment currently exists for LFS, early diagnosis may have allowed the patient to benefit from syndrome-specific surveillance protocols. However, it remains uncertain whether such monitoring would have significantly improved the clinical outcome.

2.5. Melanoma screening in LFS patients

Although melanoma is not traditionally included in the LFS tumour spectrum, delayed diagnosis can significantly contribute to early mortality in this patient population. Therefore, melanoma screening should be incorporated into routine annual surveillance immediately following LFS diagnosis. Early detection through regular dermatologic evaluation is essential to improving prognosis and prolonging life expectancy.

3. Conclusion

Considering the elevated risk of multiple malignancies, patients with LFS require rigorous and multidisciplinary follow-up. Particular attention should be paid to young patients with a prior history of cancer, who should be thoroughly examined for melanocytic lesions.

Although cutaneous tumours are not core features of LFS, the integration of routine dermatological screening into standard care is crucial to ensure that potentially lethal melanocytic tumours are detected and managed promptly. The authors endorse the NCCN

recommendation that annual dermatologic screening should be conducted for all LFS patients starting at 18 years of age. A multidisciplinary approach remains essential to ensure optimal care for patients with LFS.

4. Limitations

This case report describes a single patient and, therefore, the findings cannot be generalized to all individuals with Li-Fraumeni syndrome. Moreover, although multiple melanomas were observed, a causal association between the identified TP53 mutation and melanoma cannot be established from a single case report. Larger cohort studies are required to better characterize the link between LFS and cutaneous melanoma.

CRediT authorship contribution statement

Monika Rimdeikaite: Writing – original draft, Resources, Data curation, Conceptualization. **Tomas Petras Vileikis:** Writing – review & editing, Project administration, Investigation, Data curation, Conceptualization. **Domantas Stundys:** Writing – review & editing, Visualization, Supervision, Conceptualization, Data curation, Methodology, Investigation.

Declaration of competing interest

The authors declare that they have no known competing financial interests or personal relationships that could have appeared to influence the work reported in this paper.

Acknowledgments

The authors thank the patient, who kindly gave consent for publication of this case report.

Data availability

No new data was generated for the research described in the article.

References

[1] G. Bougeard, M. Renaux-Petel, J.-M. Flaman, C. Charbonnier, P. Fermey, M. Belotti, et al., Revisiting Li-Fraumeni syndrome from TP53 mutation carriers, J. Clin. Oncol. 33 (21) (2015) 2345–2352, https://doi.org/10.1200/JCO.2014.59.5728.
[2] K. Schneider, K. Zelley, K.E. Nichols, J. Garber, Li-fraumeni syndrome, 2019.
[3] K.D. Gonzalez, K.A. Noltner, C.H. Buzin, D. Gu, C.Y. Wen-Fong, V.Q. Nguyen, J.H. Han, K. Lowstuter, J. Longmate, S.S. Sommer, J.N. Weitzel, Beyond Li Fraumeni Syndrome: clinical characteristics of families with p53 germline mutations, J. Clin. Oncol. 27 (8) (2009) 1250–1256, https://doi.org/10.1200/JCO.2008.16.6959.
[4] P.L. Mai, A.F. Best, J.A. Peters, R.M. DeCastro, P.P. Khincha, J.T. Loud, et al., Risks of first and subsequent cancers among TP53 mutation carriers in the National Cancer Institute Li-Fraumeni syndrome cohort, Cancer 122 (23) (2016) 3673–3681.
[5] C. Curiel-Lewandrowski, L.S. Speetzen, L. Cranmer, J.A. Warneke, L.J. Loescher, Multiple primary cutaneous melanomas in Li-Fraumeni syndrome, Arch. Dermatol. 147 (2) (2011) 248–250, https://doi.org/10.1001/archdermatol.2010.428.
[6] C. Pötzsch, T. Voigtländer, M. Lübbert, p53 Germline mutation in a patient with Li-Fraumeni Syndrome and three metachronous malignancies, J. Cancer Res. Clin. Oncol. 128 (2002) 456–460, https://doi.org/10.1007/s00432-002-0360-3.
[7] R. Kollipara, L.D. Cooley, K.A. Horii, M.L. Hetherington, P.E. LeBoit, V. Singh, et al., Spitzoid melanoma in a child with Li-Fraumeni syndrome, Pediatr. Dev. Pathol. 17 (1) (2014) 64–69, https://doi.org/10.2350/13-09-1380-CR.
[8] A. Villani, A. Shore, J.D. Wasserman, D. Stephens, R.H. Kim, H. Druker, et al., Biochemical and imaging surveillance in germline TP53 mutation carriers with Li-Fraumeni syndrome: 11 year follow-up of a prospective observational study, Lancet Oncol. 17 (9) (2016) 1295–1305, https://doi.org/10.1016/S1470-2045(16)30249-2.
[9] P. Giavedoni, M. Ririe, C. Carrera, S. Puig, J. Malvehy, Familial melanoma associated with Li-Fraumeni syndrome and atypical Mole syndrome: total-body digital photography, dermoscopy and confocal microscopy, Acta Derm. Venereol. 97 (6) (2017) 720–723, https://doi.org/10.2340/00015555-2639.
[10] Y.S. Baek, J.Y. Seo, J.Y. Song, S.Y. Lee, A. Kim, J. Jeon, Li-Fraumeni syndrome presenting as cutaneous melanoma in a child: case report and review of literature, J. Eur. Acad. Dermatol. Venereol. 33 (4) (2019) e174–e175, https://doi.org/10.1111/jdv.15430.
[11] J.N. Hatton, M.R. Sargen, M.N. Frone, K.C. de Andrade, S.A. Savage, P.P. Khincha, Spectrum and incidence of skin cancer among individuals with Li-Fraumeni syndrome, J. Invest. Dermatol. 142 (9) (2022) 2534, https://doi.org/10.1016/j.jid.2022.02.004.
[12] S. Nieuwenburg, F. Adan, M. Ruijs, G. Sonke, M. Van Leerdam, M. Crijns, Cumulative risk of skin cancer in patients with Li-Fraumeni syndrome, Fam. Cancer 19 (2020) 347–351, https://doi.org/10.1007/s10689-020-00178-1.
[13] T. Frebourg, S. Bajalica Lagercrantz, C. Oliveira, et al., Guidelines for the Li-Fraumeni and heritable TP53-related cancer syndromes, Eur. J. Hum. Genet. 28 (2020) 1379–1386, https://doi.org/10.1038/s41431-020-0638-4.
[14] D. Sonkin, A. Thomas, B.A. Teicher, Cancer treatments: past, present, and future, Cancer Genet. (2024), https://doi.org/10.1016/j.cancergen.2024.06.002.
[15] M. Dixon-Zegeye, R. Shaw, L. Collins, K. Perez-Smith, A. Ooms, M. Qiao, P. Pantziarka, L. Izatt, M. Tischkowitz, R.E. Harrison, A. George, Cancer precision-prevention trial of metformin in adults with Li Fraumeni syndrome (MILI) undergoing yearly MRI surveillance: a randomised controlled trial protocol, Trials 25 (1) (2024) 103, https://doi.org/10.1186/s13063-024-07929-w.
[16] A.I. Amador-Gómez, I. Aguiñiga-Sánchez, V.M. Mendoza-Núñez, J. Cadena-Iñiguez, E. Romero-López, E. Santiago-Osorio, Li–Fraumeni Syndrome: narrative review through a case report with ten years of primary tumor remission associated with sechium H387 07 supplementation, Int. J. Mol. Sci. 25 (21) (2024) 11477, https://doi.org/10.3390/ijms252111477.
[17] F. Valdez-Salazar, L.A. Jiménez-Del Rio, J.R. Padilla-Gutiérrez, Y. Valle, J.F. Muñoz-Valle, E. Valdés-Alvarado, Advances in melanoma: from genetic insights to therapeutic innovations, Biomedicines 12 (8) (2024) 1851, https://doi.org/10.3390/biomedicines12081851.

[18] National Comprehensive Cancer Network (NCCN), Genetic/Familial high-risk assessment: breast, ovarian, Pancreatic, and prostate. NCCN guidelines version 3.2026, Available from: https://www.nccn.org/guidelines/guidelines-detail?category=2&id=1545. Accessed July 2026.
[19] C.P. Kratz, M.I. Achatz, L. Brugieres, T. Frebourg, J.E. Garber, M.L. Greer, J.R. Hansford, K.A. Janeway, W.K. Kohlmann, R. McGee, C.G. Mullighan, Cancer screening recommendations for individuals with Li-Fraumeni syndrome, Clin. Cancer Res. 23 (11) (2017 Jun 1) e38–e45, https://doi.org/10.1158/1078-0432.CCR-17-0408.
[20] D. Wong, P. Luo, L.E. Oldfield, H. Gong, L. Brunga, R. Rabinowicz, V. Subasri, C. Chan, T. Downs, K.M. Farncombe, B. Luu, Early cancer detection in Li–Fraumeni syndrome with cell-free DNA, Cancer Discov. 14 (1) (2024) 104–119, https://doi.org/10.1158/2159-8290.CD-23-0456.