Cureus
Part of SPRINGER NATURE

Open Access Review Article

Reconstructive Strategies in Acute Nasal Soft-Tissue Trauma: A Narrative Review and Subunit-Based Algorithm

Review began 09/30/2026
Review ended 10/23/2026
Published 10/24/2026

© **Copyright** 2026
Maciulaitis et al. This is an open access article distributed under the terms of the Creative Commons Attribution License CC-BY 4.0., which permits unrestricted use, distribution, and reproduction in any medium, provided the original author and source are credited.

DOI: 10.7759/cureus.118536

Tomas Maciulaitis [1], Patricija Glovackaite [2], Karolis Bauzys [1]

1. Faculty of Medicine, Institute of Clinical Medicine, Clinic of Rheumatology, Orthopedics, Traumatology and Reconstructive Surgery, Vilnius University, Vilnius, LTU 2. Faculty of Medicine, Vilnius University, Vilnius, LTU

Corresponding author: Tomas Maciulaitis, tomas.maciulaitis@santa.lt

Abstract

While several subunit-based algorithms exist for oncologic nasal defects, particularly following Mohs micrographic surgery, comparable guidance for acute nasal soft-tissue trauma remains lacking. Acute traumatic defects present distinct challenges related to tissue viability, contamination, tissue salvage, timing of reconstruction, and variable patterns of tissue loss. This narrative review synthesizes the contemporary literature on acute nasal soft-tissue reconstruction and proposes a practical clinical framework for decision-making. Recurring reconstructive principles identified in the literature include preservation and salvage of viable tissue, assessment of wound suitability for definitive reconstruction, restoration of contour and airway function, and consideration of defect location, size, depth, and structural or lining involvement. Small superficial defects may be managed with secondary intention, primary closure, skin grafting, or local flaps, whereas larger, deeper, and multisubunit defects may require regional flaps, structural support, and staged reconstruction. Based on these principles, a trauma-specific algorithm is proposed that prioritizes initial trauma assessment, salvage of avulsed or amputated tissue when feasible, and determination of wound readiness before proceeding to subunit- and defect-based reconstructive selection. By translating heterogeneous and predominantly low-level evidence into a structured approach, this framework addresses a gap in the current literature and may assist surgeons in the management of acute nasal soft-tissue injuries.

Categories: Plastic Surgery, Trauma
Keywords: aesthetic subunits, nasal reconstruction, nasal trauma, reconstructive ladder, soft-tissue defects, treatment algorithm

Introduction And Background

Nasal soft-tissue defects remain among the most challenging problems in facial reconstruction due to the nose's complex three-dimensional anatomy and its critical role in both facial aesthetics and airway function [1,2]. Successful reconstruction requires restoration of contour and skin cover while preserving structural support and minimizing distortion of adjacent anatomical units [3].

The management of acute traumatic nasal defects presents challenges distinct from those encountered in planned reconstruction. Traumatic injuries may be associated with irregular wound margins, tissue loss, contamination, uncertain tissue viability, avulsion or amputation of nasal tissue, and concomitant facial injuries, necessitating early assessment and reconstructive decision-making [1,4]. The frequency of facial trauma presenting to emergency departments further emphasizes the need for a structured approach to acute nasal reconstruction [1]. In contrast, oncologic defects are generally created under more controlled conditions, allowing reconstructive planning to begin from a defined surgical defect.

Current reconstructive strategies for nasal defects are largely derived from the broader reconstructive and oncologic literature and are commonly based on the principles of nasal aesthetic subunits and the reconstructive ladder. Several authors have proposed algorithms that organize nasal reconstruction according to defect location, size, and available reconstructive options [5,6]. However, comparable trauma-specific guidance remains limited. In acute trauma, decisions regarding preservation of viable tissue, management of avulsed or amputated parts, wound contamination, and immediate versus delayed reconstruction precede selection of a definitive reconstructive technique [1,4]. While established reconstructive concepts remain applicable, the available trauma-specific literature consists predominantly of case reports and small case series, and no widely accepted trauma-oriented framework currently exists.

Despite the heterogeneity of reported injuries, several recurring principles can be identified regarding tissue salvage, wound assessment, timing of reconstruction, subunit-specific reconstruction, structural support, and indications for staged reconstruction. Synthesizing these principles into a practical clinical framework may facilitate decision-making in the acute setting.

How to cite this article
Maciulaitis T, Glovackaite P, Bauzys K (October 24, 2026) Reconstructive Strategies in Acute Nasal Soft-Tissue Trauma: A Narrative Review and Subunit-Based Algorithm. Cureus 18(10): e118536. DOI 10.7759/cureus.118536

This narrative review aims to summarize contemporary strategies for the management and reconstruction of acute nasal soft-tissue trauma and to propose an evidence-informed, subunit-based framework for reconstructive planning. The review focuses primarily on the management of the soft-tissue defect; associated skeletal, cartilaginous, and lining injuries are considered where they directly influence soft-tissue reconstruction, nasal contour, or airway function.

Review

Methods

A literature search was conducted using PubMed and Scopus to identify studies relevant to the reconstruction of acute nasal soft-tissue trauma. Additional articles were identified through manual review of the reference lists of selected publications.

English-language studies describing traumatic nasal soft-tissue defects, reconstructive techniques, and principles relevant to traumatic nasal reconstruction were included. Given the limited trauma-specific literature, studies addressing nasal reconstruction in other clinical settings were also considered when they described reconstructive principles or techniques applicable to acute traumatic defects.

The literature was analyzed qualitatively using a narrative synthesis, with particular attention to mechanism of injury, tissue viability and salvage, wound contamination, timing of reconstruction, defect location, size and depth, reconstructive technique, and the presence of structural or lining involvement when these factors influenced soft-tissue reconstruction. Recurring principles identified across the reviewed literature were synthesized into a practical subunit-based framework for acute nasal soft-tissue trauma reconstruction.

Principles of acute nasal reconstruction

Several recurring principles emerged from the reviewed literature and formed the basis of reconstructive decision-making across a wide range of traumatic nasal defects. These include initial assessment and tissue salvage, evaluation of wound conditions and timing of reconstruction, application of the aesthetic subunit concept, assessment of defect size and depth, preservation of structural support and airway function, and appropriate selection along the reconstructive ladder [4,7].

Tissue Viability and Timing of Reconstruction

Initial management should focus on patient stability, associated facial injuries, wound assessment, debridement, and evaluation of tissue viability [1,4]. Nasal bone and septal injuries, septal hematoma or abscess, and evidence of nasal airway compromise should be identified before definitive soft-tissue reconstruction is undertaken [1]. Traumatic nasal defects may present with contamination, crush injury, irregular tissue loss, and associated facial trauma, making reconstructive planning less predictable than in controlled oncologic defects [1,8]. Thorough irrigation and wound exploration are therefore essential to define the extent of soft-tissue loss and identify associated structural injury [1].

Whenever possible, viable native nasal tissue should be preserved. This is particularly relevant in avulsion and amputation injuries, in which the presence and condition of the avulsed part should be assessed early [4]. Primary reattachment or reconstruction with careful debridement, anatomical realignment, and layered repair may preserve native contour in appropriately selected injuries [4,8,9]. Ghosh described successful one-stage reconstruction of a complex facial avulsion injury and emphasized early debridement and accurate restoration of anatomical landmarks [9]. Similarly, primary reconstruction has been reported across a broader series of traumatic facial defects, supporting early repair when local and systemic conditions permit [8]. When an amputated nasal segment is available, composite grafting or microsurgical replantation may be considered in selected cases depending on the size and composition of the amputated tissue, its condition, and available expertise [6].

The timing of definitive reconstruction should be determined by the wound rather than by defect size alone. Early definitive repair is most appropriate when the patient is stable, the wound has been adequately irrigated and debrided, tissue viability is established, and contamination is controlled [1,8]. Clean, sharply defined injuries presenting early may therefore be suitable for primary repair. Selected bite injuries may also undergo early repair after meticulous irrigation and debridement when infection risk has been appropriately addressed [10]. In contrast, crush, blast, high-energy ballistic, heavily contaminated, or otherwise devitalized wounds may have an evolving zone of tissue injury and may require initial debridement, temporary wound care, and reassessment before definitive reconstruction [1,8]. The timing of interpolated flap reconstruction should be individualized according to wound contamination, tissue viability, and the adequacy of debridement; selected traumatic defects may undergo early reconstruction, whereas wounds with uncontrolled contamination or evolving tissue loss may require staged management [10].

When definitive reconstruction is not initially appropriate, temporization does not necessarily imply simple observation. Depending on the defect and wound condition, options may include local wound care, delayed

primary closure, temporary wound coverage, or staged reconstruction [1,6]. Severe composite facial injuries may require sequential restoration of the soft-tissue envelope, skeletal framework, and nasal architecture; multistage reconstruction has been described following extensive traumatic facial tissue loss [11]. Assessment of tissue salvage and reconstructive readiness should therefore precede selection of a subunit-specific technique.

The Aesthetic Subunit Concept

The aesthetic subunit concept remains an important principle of nasal reconstruction [12]. The nose is divided into distinct anatomical regions, including the dorsum, sidewalls, tip, alae, soft triangles, and columella, as illustrated in Figure *1*. Reconstruction planned according to subunit boundaries can facilitate contour restoration and scar placement along natural junctions between aesthetic units [2,3,12].

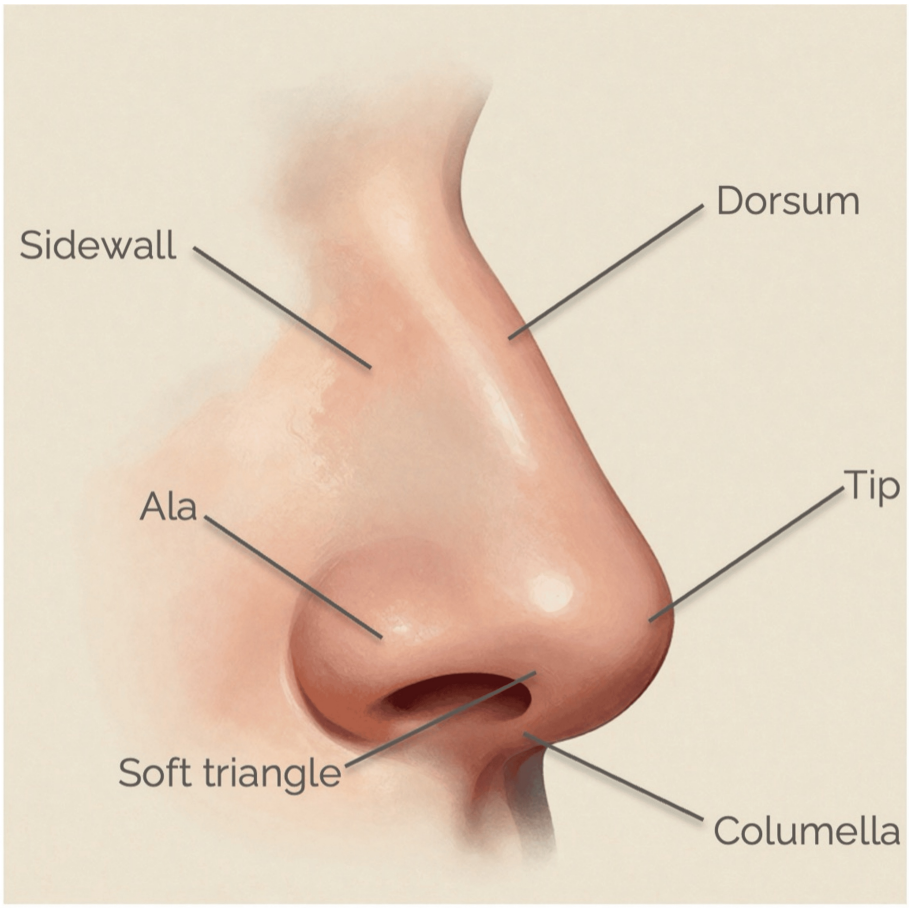

FIGURE 1: Aesthetic subunits of the nose

Image credit: Magnific AI (Freepik Company, S.L., Málaga, Spain) was used for image enhancement and refinement during the preparation of this figure. The scientific content, figure design, labeling, and final interpretation were performed and verified by the authors.

Burget and Menick advocated excision of the remaining normal tissue when a defect involves more than 50% of an aesthetic subunit, followed by reconstruction of the entire subunit [12]. This principle was developed primarily in the setting of planned reconstruction and should not be applied rigidly to acute trauma. In traumatic defects, preservation of viable native tissue generally takes priority over elective completion of a subunit, and otherwise healthy skin should not routinely be discarded solely to satisfy the >50% rule. Partial-subunit reconstruction may therefore be appropriate when viable tissue can be retained without compromising contour, wound closure, or airway function [13,14].

Subunit location also influences tissue selection. The skin of the nasal tip and ala is relatively thick, sebaceous, and less mobile, whereas the dorsal and sidewall skin is generally thinner and more mobile [3,7]. Consequently, color, thickness, texture, tissue mobility, and contour should be considered together when selecting donor tissue and determining whether defect-only or whole-subunit reconstruction is preferable [3,13,14]. The subunit principle should therefore serve as an aesthetic guide rather than an absolute rule in acute trauma.

Defect Size and Depth

Defect size and depth are major determinants of reconstructive strategy [3]. Small superficial defects may be amenable to primary closure, secondary intention healing, or full-thickness skin grafting (FTSG), whereas increasing defect dimensions generally require local or regional flap reconstruction [2,3]. Secondary intention may be particularly useful for carefully selected small defects in concave areas, where contraction can be less conspicuous than in convex nasal subunits [2,7]. Surface dimensions alone, however, do not adequately define reconstructive complexity. A relatively small defect involving the alar margin or structural support may require more complex reconstruction, whereas a larger skin-only defect in an area with greater tissue mobility may remain suitable for local tissue rearrangement [3,7].

Defect depth should therefore be assessed independently of surface size. Skin-only defects primarily require restoration of the external envelope, whereas composite defects involving cartilage require simultaneous consideration of soft-tissue coverage and structural support [3]. Full-thickness defects represent a more complex reconstructive problem because the internal lining, structural framework, and external skin cover must all be restored [15]. Failure to address these layers may compromise contour and nasal function, particularly in defects involving the lower third of the nose [15].

Accordingly, defect assessment should define not only surface dimensions but also cartilage loss, mucosal involvement, exposure of underlying structures, extension across aesthetic subunits, and potential involvement of the internal or external nasal valve. These characteristics may justify escalation to structural reconstruction, regional flaps, or staged reconstruction even when the cutaneous defect itself is relatively limited [3,15]. Detailed techniques for reconstruction of extensive intranasal lining and skeletal framework are beyond the primary soft-tissue focus of this review; however, their involvement must be recognized because they directly influence the timing and choice of soft-tissue reconstruction.

Structural Support

Structural support is particularly important in reconstruction of the lower third of the nose [3,7,15]. Defects involving the tip, ala, alar rim, or columella may compromise projection, contour, and nasal valve function even when the cutaneous component is relatively limited [3,7]. Structural loss affecting the external nasal valve, particularly at the alar rim or lateral nasal wall, may lead to retraction or inspiratory collapse, while deeper septal or lateral-wall injury may contribute to internal nasal valve compromise. Functional airway assessment should therefore accompany evaluation of the visible soft-tissue defect [1,7].

Cartilage grafting should be considered when loss of native support creates a risk of alar collapse, retraction, loss of projection, or airway compromise [3,7,15]. The requirement for structural reconstruction increases with defect depth and the extent of subunit involvement. In complex defects, cartilage grafts may be combined with local or regional soft-tissue reconstruction to recreate the three-dimensional framework rather than merely provide surface coverage [3,15].

In multisubunit and full-thickness injuries, reconstruction may require coordinated restoration of lining, support, and external cover [15]. The specific framework or lining technique should be tailored to the structures lost and falls beyond the detailed scope of this soft-tissue review; nevertheless, structural or lining deficiency should be recognized as an independent modifier of the reconstructive plan rather than considered solely as a consequence of cutaneous defect size.

The Reconstructive Ladder

The reconstructive ladder provides a practical framework for selecting among secondary intention healing, primary or delayed primary closure, skin grafting, local flaps, regional flaps, and, in exceptional extensive defects, free tissue transfer [1,2,4]. In nasal reconstruction, progression along the ladder should not be interpreted as a requirement to exhaust each simpler option before proceeding to a more complex technique. The objective is to select the least complex approach capable of restoring contour and function without creating unacceptable distortion of adjacent nasal subunits [2].

Secondary intention healing may be appropriate for selected small superficial defects, particularly in favorable concave locations [2,7]. Primary closure and FTSGs remain useful for appropriately selected superficial defects, whereas local flaps provide vascularized adjacent tissue with favorable color and texture characteristics [2]. When definitive closure must be deferred because of contamination or uncertain viability, delayed primary closure or temporary wound coverage may provide intermediate wound management before definitive reconstruction [1,6]. As defect size, depth, or structural involvement increases, regional reconstruction becomes increasingly important [3,7].

Complex traumatic defects may therefore require direct escalation to a regional flap, often combined with structural or lining reconstruction, rather than sequential progression through every step of the ladder [1,7]. Conversely, the presence of a large defect alone should not mandate immediate flap reconstruction when the recipient bed remains contaminated, or tissue viability is evolving. The reconstructive ladder should

consequently be applied only after tissue salvage, wound condition, involved subunit, and the components requiring replacement have been assessed.

Subunit-specific reconstruction strategies

Analysis of the reviewed literature demonstrated that reconstructive strategy varied primarily according to the involved nasal subunit, defect size and depth, tissue characteristics, and the presence of structural loss. Despite the heterogeneity of reported injuries, several consistent patterns emerged (summarized in Table *1*).

Nasal Subunit	Common Defect Type	Reconstructive Considerations	Reconstruction Strategies
Dorsum/sidewall	Small-moderate skin defects	Good tissue mobility	Local flaps, FTSG
Tip	Skin ± cartilage defects	Limited skin laxity, contour preservation	Bilobed flap, local flaps
Ala	Skin ± cartilage defects involving alar rim	Risk of alar collapse	FTSG + cartilage graft, nasolabial flap
Soft triangle [24,25]	Small but anatomically delicate defects	Contour preservation critical	Local flap or composite graft
Columella	Full-thickness or structural defects	Structural support required	Local flap + cartilage support

TABLE 1: Summary of reconstructive strategies for acute nasal soft-tissue defects by subunit

FTSG: full-thickness skin graft.

Dorsal and sidewall defects are generally the most amenable to conservative or local reconstructive options because of the relative mobility of adjacent tissue. Small superficial defects may be managed by primary closure, full-thickness skin grafting, or, in appropriately selected concave areas, secondary intention healing, whereas local flaps become increasingly useful as defect size increases [2,3,7]. Commonly described options include advancement, glabellar, dorsal nasal, and bilobed flaps [3,7]. Defects of the proximal dorsum are particularly amenable to glabellar flap reconstruction, whereas more distal dorsal defects may be reconstructed using local advancement or transposition flaps [1,16]. Tissue thickness and texture should also be considered, as the relatively thin dorsal and sidewall skin may make bulky tissue transfer conspicuous [3,7].

Reconstruction of the tip is more challenging because of its convex contour, thicker sebaceous skin, and limited tissue laxity [3,7]. Local flaps, including bilobed and dorsal nasal flaps, are useful for appropriately selected small-to-moderate defects, whereas larger or deeper defects may require regional reconstruction [1,7,15,16]. Bilobed flaps are particularly useful for distal nasal defects in which adjacent tissue can be recruited without excessive tension; however, inappropriate flap design or use in defects that are too large may result in pincushioning, trapdoor deformity, or distortion of the alar margin [3,7]. In selected traumatic tip defects, dorsal nasal flaps provide a one-stage reconstructive option with favorable contour restoration [17]. Larger tip defects, particularly those involving multiple tissue layers, may require forehead flap reconstruction [3,15].

Alar reconstruction requires particular attention to contour, rim position, and external nasal valve function. Even relatively small defects may produce clinically significant notching, retraction, or collapse when the alar margin or underlying support is involved [1-3]. Preservation of viable alar tissue is therefore particularly important in trauma [6]. When an avulsed segment is available, primary reattachment or composite grafting may be considered in selected defects before replacing native tissue with a flap [6,18]. Corradino et al. described reconstruction of a full-thickness alar defect following human bite injury using an auricular composite graft combined with a melolabial flap, restoring both soft-tissue cover and cartilaginous support [18].

Nasolabial and melolabial flaps provide adjacent tissue with favorable color and texture characteristics and are particularly useful for alar defects [3,19]. Depending on defect configuration and flap design, they may be transposed directly or used as interpolated flaps requiring subsequent pedicle division [3,17]. Trauma-specific reports demonstrate their applicability in this setting: Rahpeyma and Khajehahmadi described the use of the nasolabial flap for maxillofacial gunshot injuries, including reconstruction of a traumatic nasal alar defect [20]. The timing of definitive interpolated reconstruction should be individualized according to wound contamination, tissue viability, and adequacy of debridement, with staged management considered when wound conditions remain unfavorable [1,4].

Columellar defects were less frequently reported but may require restoration of both soft-tissue cover and structural support [3,15]. Because loss of columellar support may affect nasal projection and airway relationships, the depth of injury is more important than surface dimensions alone [3,15]. Composite defects involving cartilage loss are associated with increased reconstructive complexity regardless of subunit location [3,15].

The most demanding injuries involve multiple subunits of the lower third of the nose [21]. These defects frequently require staged reconstruction, restoration of the cartilaginous framework, and regional flaps, particularly the paramedian forehead flap (PMFF) [15,22]. The PMFF provides a substantial amount of well-vascularized tissue with favorable color and texture match and remains an important option for large tip, alar, and multisubunit defects [3,15,22]. Its use should nevertheless be individualized according to wound condition, defect requirements, patient factors, and the availability of suitable forehead tissue [4,15].

Collectively, these findings suggest that reconstructive selection should not be based on subunit or defect size alone. Dorsal and sidewall defects frequently permit simpler approaches, whereas injuries involving the tip, ala, columella, or multiple lower-third subunits more often require advanced soft-tissue reconstruction and, when structural support has been lost, coordinated framework restoration [7,21,23]. In acute trauma, preservation of viable native tissue, wound condition, skin characteristics, and functional consequences should modify the application of otherwise established subunit-based reconstructive principles [4,14].

Proposed subunit-based algorithm

Previous algorithmic approaches have largely focused on flap selection according to defect location, orientation, and subunit involvement, providing an important foundation for contemporary nasal reconstruction planning [5]. Based on the recurring reconstructive patterns identified in the reviewed literature, a practical algorithm for acute nasal soft-tissue trauma reconstruction was developed (Figure *2*). In contrast to algorithms developed primarily for planned defects, the proposed framework begins with acute trauma assessment and tissue salvage before proceeding to subunit-specific reconstruction. It is intended as an evidence-informed clinical guide rather than a validated treatment algorithm.

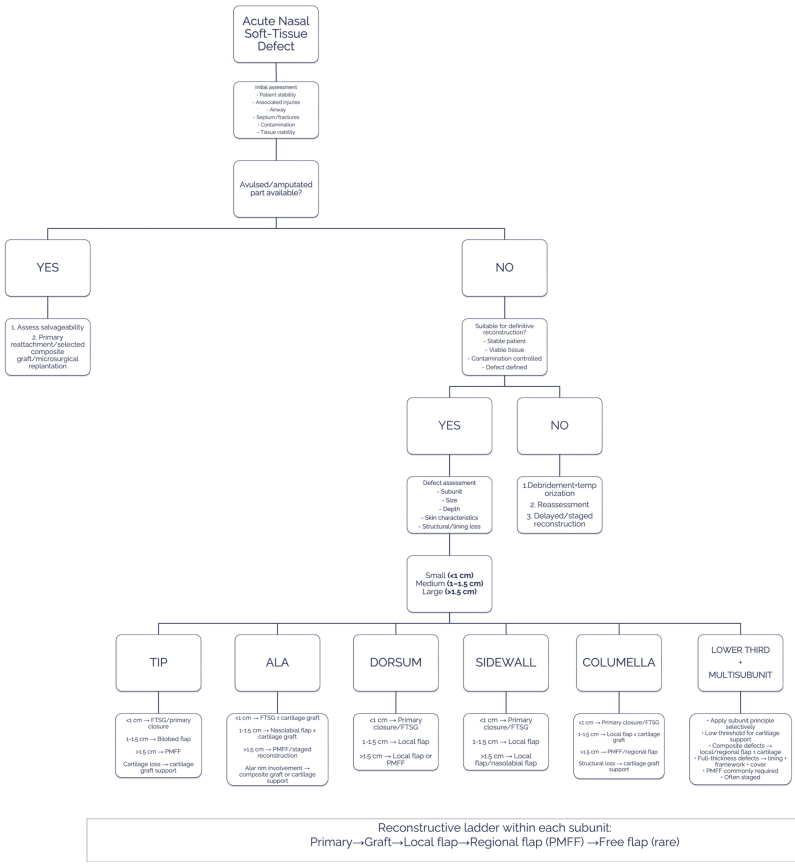

FIGURE 2: Proposed algorithm for acute nasal soft-tissue trauma reconstruction

The algorithm integrates initial trauma assessment, preservation and salvage of avulsed or amputated tissue, wound suitability for definitive reconstruction, involved nasal subunit, defect size and depth, tissue characteristics, and structural or lining loss to guide reconstructive planning. When definitive reconstruction is not initially appropriate, debridement and temporization are followed by reassessment and delayed or staged reconstruction. Size categories refer to the maximum dimension of the nasal soft-tissue defect and are defined as small (<1 cm), medium (1–1.5 cm), and large (>1.5 cm). These thresholds represent pragmatic clinical categories derived from reconstructive patterns identified in the reviewed literature and should not be interpreted as validated cutoff values.

FTSG: full-thickness skin graft; PMFF: paramedian forehead flap.

Figure created by the authors using Microsoft PowerPoint (Microsoft Corporation, Redmond, Washington) based on the literature reviewed in this narrative review.

Memar and Caughlin proposed a size- and subunit-based approach to post-Mohs nasal defects larger than 1.5 cm, emphasizing reconstruction along cosmetic subunit borders and selection of local, regional, or forehead flaps according to defect characteristics [6]. Although several of these principles remain applicable to traumatic defects, acute trauma requires additional consideration of tissue salvage, contamination, evolving tissue viability, associated injuries, and the timing of definitive reconstruction [1,4].

The first decision point is therefore whether an avulsed or amputated nasal segment is available and potentially salvageable. Viable native tissue should be preserved whenever possible, and primary reattachment or reconstruction may be appropriate in selected injuries [4,8,9]. Composite grafting or microsurgical replantation may represent additional salvage options in selected amputations depending on the size and composition of the tissue, its condition, and available expertise [4,17]. When salvage is not feasible or when no amputated part is available, management proceeds according to the characteristics of the residual wound.

Before definitive soft-tissue reconstruction, associated injuries and wound conditions should be assessed. Patient stability, nasal airway compromise, septal hematoma or abscess, nasal bone or septal injury, contamination, and tissue viability may influence the timing and extent of reconstruction [1,4,8]. Early definitive reconstruction is most appropriate when the patient is stable, tissue viability is established, and the wound has been adequately irrigated, debrided, and decontaminated [1,8]. Conversely, heavily

contaminated wounds and injuries with evolving tissue viability, including severe crush, blast, and high-energy ballistic injuries, may require debridement and temporization followed by delayed or staged reconstruction [1,8,11]. The timing of definitive interpolated flap reconstruction should be individualized according to wound contamination, tissue viability, and adequacy of debridement, with staged reconstruction considered when the recipient bed is not yet suitable [4,10].

Once the wound is suitable for definitive reconstruction, planning proceeds according to the involved nasal subunit, defect size and depth, tissue characteristics, and the presence of structural or lining loss [3]. The algorithm incorporates the principles of the reconstructive ladder within this assessment. Defects are stratified into three pragmatic size categories: small (<1 cm), medium (1-1.5 cm), and large (>1.5 cm). These thresholds were synthesized from recurring reconstructive patterns across the reviewed literature and are intended to facilitate organization of reconstructive options rather than serve as validated treatment cutoffs [3,6,17]. Importantly, defect size should not override tissue viability, depth, structural involvement, or the opportunity to preserve viable native tissue [4].

Smaller superficial defects may be amenable to secondary intention healing, primary or delayed primary closure, skin grafting, or local tissue rearrangement, depending on wound and subunit characteristics [2,3,7]. Increasing defect size, depth, or structural involvement may require escalation to regional reconstruction [3,7]. Particular attention is required for defects involving the tip, ala, and lower third of the nose, where tissue mobility is limited and loss of support may compromise contour or nasal valve function [3,15,17].

Structural or lining loss acts as an additional modifier rather than a separate size category. Defects involving the alar rim, nasal tip, columella, or multiple lower-third subunits may require structural reconstruction to maintain contour and airway function [3,15,18]. Full-thickness defects require coordinated consideration of the internal lining, structural framework, and external soft-tissue cover and may necessitate staged reconstruction [15]. Detailed selection of lining and framework techniques falls beyond the primary soft-tissue focus of the present algorithm, but their involvement should be recognized before definitive coverage is selected.

The paramedian forehead flap (PMFF) remains a principal regional option for extensive or complex nasal defects once the recipient bed is suitable for definitive reconstruction [7,15]. Comparative evidence has evaluated the PMFF and nasolabial flap as major regional reconstructive options [26], with systematic review and meta-analysis-level evidence further examining their relative outcomes [27]. Recent systematic review and meta-analytic evidence likewise supports the role of local techniques for appropriately selected distal nasal defects while demonstrating the continued importance of regional flaps for larger and more complex reconstruction [28].

Rather than assigning a single technique to a given defect, the proposed algorithm organizes decision-making sequentially: initial trauma assessment and tissue salvage; assessment of wound suitability for definitive reconstruction; evaluation of subunit, size, depth, and tissue characteristics; identification of structural or lining involvement; and selection of the least complex reconstructive option capable of restoring form and function. This sequence is intended to distinguish acute traumatic reconstruction from algorithms designed for controlled oncologic defects while preserving flexibility for surgeon judgment and individual patient factors.

Discussion

The available literature demonstrates that established principles of nasal reconstruction remain applicable to traumatic defects, but their use in the acute setting requires additional consideration of tissue salvage, wound condition, tissue viability, mechanism of injury, and the pattern of tissue loss [1,4]. Existing reconstructive algorithms have predominantly addressed oncologic defects and have organized treatment according to defect size, location, and aesthetic subunit [5,6]. In contrast, traumatic defects may be irregular, contaminated, structurally complex, and associated with avulsion or amputation, uncertain tissue viability, or additional facial injuries [1,4,8]. The framework proposed in this review therefore integrates established reconstructive principles with factors that are particularly relevant to acute trauma.

A major distinction is that reconstructive planning in trauma begins before the selection of a technique for the residual defect. When tissue has been avulsed or amputated, the potential for preservation or salvage of native nasal tissue should first be considered [4]. Primary reconstruction has been successfully applied to traumatic facial injuries, including complex avulsion defects [8,9], whereas severe composite injuries may require staged management [11,29]. The proposed algorithm therefore prioritizes tissue salvage and assessment of wound suitability for definitive reconstruction before proceeding to defect-specific planning. Patient stability, contamination, tissue viability, and associated structural or airway injuries may all influence this decision [1,4]. This trauma-first sequence distinguishes the proposed framework from algorithms developed primarily for planned oncologic defects, which generally begin with an established surgical defect [5,6].

The timing of reconstruction should similarly be individualized according to wound characteristics rather

than defect dimensions alone. Early definitive reconstruction may preserve native tissue and reduce secondary deformity when the wound has been adequately debrided, contamination is controlled, tissue viability is established, and the patient is clinically stable [1,4,8,9]. Conversely, wounds with substantial contamination, crush injury, or evolving tissue loss may benefit from temporization and reassessment before definitive reconstruction [1,8,11]. Thus, immediate and delayed reconstruction should be viewed as context-dependent pathways rather than competing strategies.

Once the wound is suitable for definitive reconstruction, the aesthetic subunit concept provides an important anatomical basis for planning. Burget and Menick established the subunit principle as a foundation of nasal reconstruction [12], and subsequent algorithms have incorporated subunit location, defect dimensions, and reconstructive complexity into treatment selection [5,6]. However, the >50% subunit principle was developed in the context of planned reconstruction and should not be applied rigidly to acute trauma. Sacrificing otherwise viable native tissue solely to complete an aesthetic subunit may be undesirable after traumatic tissue loss. Preservation of viable tissue, tissue quality, color and texture match, contour, and functional consequences should therefore be balanced against the potential aesthetic advantages of whole-subunit reconstruction [4,13,14]. Partial-subunit repair may be appropriate when these objectives can be achieved without unnecessary removal of healthy tissue [13,14].

Similarly, defect size provides a useful framework for organizing reconstructive options but should not be interpreted as the sole determinant of technique. Smaller superficial defects are generally suitable for simpler approaches, including secondary intention healing, primary or delayed primary closure, skin grafting, and local tissue rearrangement in appropriately selected wounds, whereas increasing defect size and complexity may require regional reconstruction [2,3,7]. The size categories used in the proposed algorithm should therefore be regarded as pragmatic clinical categories rather than validated treatment thresholds [3,6,17]. Defect depth, subunit characteristics, structural loss, and functional consequences may necessitate escalation to more complex reconstruction irrespective of surface dimensions [3,15].

This consideration is particularly important in the lower third of the nose, where even limited tissue loss may compromise contour or nasal valve function [3,15,17]. Full-thickness defects require coordinated consideration of the internal lining, structural framework, and external cover [15]. Consequently, defects involving cartilage loss or multiple tissue layers may require structural reconstruction in combination with local or regional soft-tissue coverage [3,15]. The paramedian forehead flap remains an important option for extensive and complex nasal defects, while local and other regional techniques remain appropriate for selected smaller defects [7,15,28]. Although detailed reconstruction of the nasal lining and cartilaginous framework falls beyond the primary soft-tissue focus of this review, failure to recognize these components during initial assessment may compromise both reconstructive planning and functional outcome.

The proposed framework should therefore not be interpreted as assigning a single reconstructive technique to each defect. Instead, it organizes decision-making according to a sequential assessment of tissue salvage, wound readiness for definitive reconstruction, subunit location, defect size and depth, tissue characteristics, structural or lining involvement, and the reconstructive complexity required. Patient-specific factors and mechanism of injury may further modify these decisions. This approach retains the flexibility necessary for traumatic injuries while incorporating principles derived from established nasal reconstruction literature.

Reconstructive success should ultimately be assessed by both aesthetic and functional outcomes. In addition to flap or graft survival, follow-up should consider contour, symmetry, alar position, scar quality, nasal airway function, and the need for secondary revision. Where feasible, standardized photography and validated patient-reported outcome measures may improve comparability between reconstructive approaches. Instruments assessing nasal obstruction and patient satisfaction, including the Nasal Obstruction Symptom Evaluation (NOSE) scale and FACE-Q modules, may provide useful complementary measures in future studies [30,31].

Importantly, the proposed algorithm is an evidence-informed synthesis rather than a validated treatment guideline. The trauma-specific literature remains dominated by case reports, small case series, and retrospective observations, while several principles incorporated into the framework are extrapolated from the broader nasal reconstruction literature. Consequently, the algorithm is intended to support, rather than replace, individualized surgical judgment. Prospective studies using standardized functional, aesthetic, and patient-reported outcomes are needed to evaluate the proposed framework and determine whether its size categories and reconstructive pathways can be further refined.

Limitations of the current evidence

Several limitations within the available literature should be acknowledged. First, trauma-specific evidence remains limited, with most published studies consisting of case reports and small case series. Consequently, the available data are inherently susceptible to publication and selection bias and do not permit robust direct comparison of reconstructive techniques or management pathways.

Second, substantial heterogeneity exists among reported injuries. Defects vary considerably with respect to

mechanism of injury, location, size, depth, tissue viability, degree of contamination, availability of avulsed or amputated tissue, and associated facial injuries. These factors influence both the timing and method of reconstruction, complicating meaningful comparison between studies and limiting the generalizability of individual reconstructive approaches. In particular, evidence supporting specific criteria for immediate versus delayed reconstruction and tissue-salvage strategies remains largely observational.

Outcome reporting is similarly inconsistent. Although most studies describe satisfactory functional and aesthetic results, objective outcome measures are rarely used, and long-term follow-up is often limited. Standardized assessment of nasal airway function, aesthetic outcomes, complications, secondary revisions, and patient-reported outcomes is uncommon, limiting meaningful comparison between reconstructive approaches.

An additional limitation is the predominance of retrospective observations. No trauma-specific reconstructive algorithm identified in the reviewed literature has undergone prospective validation, and direct comparisons of alternative reconstructive strategies for similar traumatic defect patterns remain limited. Although comparative and meta-analytic evidence exists for selected nasal reconstructive techniques, it is derived predominantly from broader nasal reconstruction rather than acute trauma-specific populations [26-28]. Furthermore, several principles incorporated into the proposed framework are necessarily extrapolated from oncologic and general reconstructive literature because corresponding trauma-specific evidence is unavailable.

Despite these limitations, several reconstructive principles were consistently observed across the reviewed literature. The recurrent importance of tissue preservation, wound condition, aesthetic subunits, defect depth, structural support, and staged reconstruction in complex injuries suggests that meaningful synthesis remains possible. Accordingly, the proposed framework should be viewed as an evidence-informed clinical guide derived from the available literature rather than a validated treatment algorithm.

Future research should focus on prospective and multicenter evaluation of defined traumatic defect patterns using standardized reporting of wound characteristics, reconstructive techniques, complications, and long-term outcomes. Incorporation of validated functional and patient-reported outcome measures, together with standardized aesthetic assessment, would facilitate comparison between reconstructive approaches and may enable future refinement and validation of trauma-specific reconstructive frameworks.

Conclusions

Although traumatic nasal defects are highly variable, several consistent reconstructive principles emerge from the available literature. Early assessment of tissue viability and salvage potential, wound condition, and suitability for definitive reconstruction should precede defect-specific planning. Once reconstruction is appropriate, preservation of viable native tissue, aesthetic subunit, defect size and depth, structural support, and functional requirements guide selection of the reconstructive approach. The proposed framework integrates these principles into a practical, trauma-oriented approach to acute nasal soft-tissue reconstruction while preserving flexibility for individual injury characteristics and surgical judgment. Given the limited quality of trauma-specific evidence, prospective studies with standardized functional, aesthetic, and patient-reported outcomes are needed to validate and refine the proposed framework.

Additional Information

Author Contributions

All authors have reviewed the final version to be published and agreed to be accountable for all aspects of the work.

Concept and design: Patricija Glovackaite, Tomas Maciulaitis, Karolis Bauzys

Acquisition, analysis, or interpretation of data: Patricija Glovackaite, Tomas Maciulaitis

Drafting of the manuscript: Patricija Glovackaite

Critical review of the manuscript for important intellectual content: Patricija Glovackaite, Tomas Maciulaitis, Karolis Bauzys

Supervision: Tomas Maciulaitis, Karolis Bauzys

Disclosures

Conflicts of interest: In compliance with the ICMJE uniform disclosure form, all authors declare the following: **Payment/services info:** All authors have declared that no financial support was received from any organization for the submitted work. **Financial relationships:** All authors have declared that they have no financial relationships at present or within the previous three years with any organizations that might

have an interest in the submitted work. **Other relationships:** All authors have declared that there are no other relationships or activities that could appear to have influenced the submitted work.

Acknowledgements

The authors acknowledge the use of Magnific AI (Freepik Company, S.L., Málaga, Spain, https://www.magnific.com/) in the preparation of Figure 1, specifically for image enhancement and refinement. The scientific content, figure design, labeling, and final interpretation were performed and verified by the authors.

References

1. Nathan JM, Ettinger KS: Management of nasal trauma . Oral Maxillofac Surg Clin North Am. 2021, 33:329-41. 10.1016/j.coms.2021.04.002
2. Weathers WM, Koshy JC, Wolfswinkel EM, Thornton JF: Overview of nasal soft tissue reconstruction: keeping it simple. Semin Plast Surg. 2013, 27:83-9. 10.1055/s-0033-1351226
3. Başağaoğlu B, Ali K, Hollier P, Maricevich RS: Approach to reconstruction of nasal defects . Semin Plast Surg. 2018, 32:75-83. 10.1055/s-0038-1642639
4. Bevans S: Management of traumatic nasal avulsion injuries . Facial Plast Surg Clin North Am. 2024, 32:315-25. 10.1016/j.fsc.2024.01.007
5. Guo L, Pribaz JR, Pribaz JJ: Nasal reconstruction with local flaps: a simple algorithm for management of small defects. Plast Reconstr Surg. 2008, 122:130e-9e. 10.1097/PRS.0b013e31818823c7
6. Memar OM, Caughlin B: Nasal reconstruction of post-Mohs defects >1.5 cm in a single cosmetic subunit under local anesthesia by a combination of plastic surgeon and Mohs surgeon team: a cross-sectional study and review of algorithmic nasal defect closures. Plast Reconstr Surg Glob Open. 2019, 7:e2277. 10.1097/GOX.0000000000002277
7. Austin GK, Shockley WW: Reconstruction of nasal defects: contemporary approaches . Curr Opin Otolaryngol Head Neck Surg. 2016, 24:453-60. 10.1097/MOO.0000000000000295
8. Chen B, Song H, Gao Q, Xu M, Chai J: Retrospective study of primary reconstruction of facial traumatic events. Int Wound J. 2017, 14:265-70. 10.1111/iwj.12598
9. Ghosh A: Primary one stage reconstruction in complex facial avulsion injury . World J Plast Surg. 2017, 6:383-6.
10. Singh K, Aggarwal K: Human bites over nose: management and reconstruction . Arch Plast Surg. 2023, 50:171-6. 10.1055/s-0042-1760406
11. Akaranuchat N, Kotistienkul B, Chungsiriwattana W: Surgical management of a patient with severe and complex maxillofacial injuries caused by a bear mauling in the forest: a case report from Thailand. JPRAS Open. 2024, 42:344-9. 10.1016/j.jpra.2024.10.009
12. Burget GC, Menick FJ: The subunit principle in nasal reconstruction . Plast Reconstr Surg. 1985, 76:239-47. 10.1097/00006534-198508000-00010
13. Núñez-Castañeda JM, Chang-Grozo SL: Surgical treatment and reconstruction of nasal defects according to the aesthetic subunits principles. Indian J Otolaryngol Head Neck Surg. 2022, 74:305-13. 10.1007/s12070-021-02475-2
14. Singh DJ, Bartlett SP: Aesthetic considerations in nasal reconstruction and the role of modified nasal subunits. Plast Reconstr Surg. 2003, 111:639-48. 10.1097/01.PRS.0000041602.85239.93
15. McAllister L, Thornton J: Complex nasal reconstruction: a methodical approach to the three-stage paramedian forehead flap. Semin Plast Surg. 2024, 38:297-303. 10.1055/s-0044-1791564
16. Andresen JR, Scheufler O: Complex nasal reconstruction for skin cancer and posttraumatic deformity using a modified frontonasal flap - case report. Int J Surg Case Rep. 2021, 83:105944. 10.1016/j.ijscr.2021.105944
17. Chen C, Patel R, Chi J: Comprehensive algorithm for nasal ala reconstruction: utility of the auricular composite graft. Surg J (N Y). 2018, 4:e55-61. 10.1055/s-0038-1639581
18. Corradino B, Di Lorenzo S, Cascino AP: Chondro-cutaneous autograft for reconstruction of the nasal ala after a human bite. Am J Case Rep. 2023, 24:e939242. 10.12659/AJCR.939242
19. Marcasciano M, Tarallo M, Maruccia M, et al.: Surgical treatment with locoregional flap for the nose . Biomed Res Int. 2017, 2017:9750135. 10.1155/2017/9750135
20. Rahpeyma A, Khajehahmadi S: Nasolabial flap in maxillofacial gunshot trauma: a case series . Arch Trauma Res. 2016, 5:e29555. 10.5812/atr.29555
21. Shwartzman B, Tomy N, Shvartzman L: Reconstruction of a multisubunit nasal defect involving the ala, nasal sidewall, and medial cheek: a case report. SAGE Open Med Case Rep. 2025, 13:2050313X251411523. 10.1177/2050313X251411523
22. Ahmadi Moghadam M, Ahmadi Moghadam S: Use of forehead flap for nasal tip reconstruction after traumatic nasal amputation. World J Plast Surg. 2017, 6:361-4.
23. Losco L, Bolletta A, Pierazzi DM, et al.: Reconstruction of the nose: management of nasal cutaneous defects according to aesthetic subunit and defect size. A review. Medicina (Kaunas). 2020, 56:10.3390/medicina56120639
24. Kim MJ, Lim H, Park DH: Current strategies for aesthetic soft tissue refinement in nasal reconstruction . Arch Craniofac Surg. 2022, 23:95-102. 10.7181/acfs.2022.00689
25. Kim ES, Heo JW, Yang CE, Kim J, Kim SW: Correction of a nasal soft triangle deficiency as a complication of augmentation rhinoplasty. Arch Craniofac Surg. 2021, 22:161-3. 10.7181/acfs.2021.00143
26. Genova R, Gardner PA, Oliver LN, Chaiyasate K: Outcome study after nasal alar/peri-alar subunit reconstruction: comparing paramedian forehead flap to nasolabial flap. Plast Reconstr Surg Glob Open. 2019, 7:e2209. 10.1097/GOX.0000000000002209
27. Chakraborty SS, Goel AD, Sahu RK, Midya M, Acharya S, Shakrawal N: Effectiveness of nasolabial flap versus paramedian forehead flap for nasal reconstruction: a systematic review and meta-analysis. Aesthetic Plast

Surg. 2023, 47:313-29. 10.1007/s00266-022-03060-w

28. Salzano G, Scocca V, Romano A, et al.: Surgical outcomes and complications of distal nasal reconstruction: a systematic review and meta-analysis. J Clin Med. 2025, 14: 10.3390/jcm14227983
29. Ali U, Ghazi KR, Kumar K, Kanza S, Shaikh SA: From injury to reconstruction, utilizing staged technique in a self-inflicted facial gunshot wound: a case report. J Med Case Rep. 2025, 19:544. 10.1186/s13256-025-05414-9
30. Sarkar A, Kumar U, Gottam SB, Sharma Y, Prasad N: Evaluation of nasal reconstruction with local flaps using the translated version of the FACE-Q scale in a local language. Cureus. 2025, 17:e80409. 10.7759/cureus.80409
31. Stewart MG, Witsell DL, Smith TL, Weaver EM, Yueh B, Hannley MT: Development and validation of the Nasal Obstruction Symptom Evaluation (NOSE) scale. Otolaryngol Head Neck Surg. 2004, 130:157-63. 10.1016/j.otohns.2003.09.016