



Myocardial Infarction Caused by Active-Fixation Ventricular Pacing Lead Screwed into the Anterior Descending Coronary Artery

Egle Majauskiene^{1, 2, *}, Gediminas Aucina^{1, 2}, Palmyra Semeniene^{1, 2}, Paulius Jurkuvenas^{1, 2}, Pranas Serpytis^{1, 2, 3}

¹ Cardiovascular Clinic, Institute of Clinical Medicine, Vilnius University, Faculty of Medicine, Vilnius, Lithuania

² University Hospital Santaros Klinikos, Cardiology and Angiology Center, Vilnius, Lithuania

³ University Hospital Santaros Klinikos, Emergency Medicine Center, Vilnius, Lithuania

ARTICLE INFO

Article Type:
Case Report

Article History:
Received: 19 Mar 2017
Revised: 28 May 2018
Accepted: 10 Jul 2018

Keywords:
Pacemaker
Myocardial Infarction

ABSTRACT

Coronary artery injury is a particularly rare complication of pacemaker implantation. Herein, we reported the case of a 76-year-old woman with sick sinus syndrome undergoing permanent pacemaker implantation who presented with chest pain a day after the procedure. During angiography, a pacemaker lead screwed into the left anterior descending coronary artery was found. The coronary artery was covered by a stent and the lead position was corrected. Based on the published research, the majority of right ventricular pacemaker leads implanted on the septum are indeed implanted on the anteroseptal junction. Since, the left anterior descending coronary artery covers this site, the risk of artery injury is higher.

1. Introduction

Increased life expectancy is evidently accompanied by an increased morbidity of aging populations, including cardiovascular diseases, which is reflected by a rise in the implantation rate of cardiac implantable electronic devices. It has been estimated that pacemaker implantation rate increased by 56% in the United States during 1993 - 2009. A similar tendency was also visible in European countries. Although pacemaker implantation is a minimally invasive procedure, some patients experience complications. According to different countries registry-based data, early complications of the first pacemaker implantation occurred in 3.6% - 5.1% of patients (1-4). The most common complications included pacemaker leads displacement, infection, pneumothorax, and bleeding (1-4). The prevalence of early complications was 5.1% among patients aged 75 years and above, but 3.4% in the younger age group (1). The most common complications are easily noticed, while rare complications are more dangerous because they are easier to misdiagnose. One of the rare complications is coronary artery injury with pacemaker lead, which is dangerous since

it can lead to myocardial infarction. This case report aims to present a rare complication of coronary artery injury caused by pacemaker implantation and to review the literature about similar cases as well as the probable reasons.

2. Case Presentation

A 76-year-old woman with a history of encephalomyelitis, hypertension, and stroke was hospitalized for elective permanent pacemaker implantation due to sick sinus syndrome. The patient complained about generalized weakness, dizziness, and repetitive syncope. Physical examination, laboratory data, and electrocardiography (ECG) on admission were within normal limits, while echocardiography showed mild mitral and aortic regurgitation. Subsequently, permanent pacemaker implantation via the left axillary vein was performed with bipolar active-fixation leads (Tendril ST 1888TC-58, OptiSense® 1999/52 [St. Jude Medical, St. Paul, MN, USA]) positioned in the right atrial appendage and at the right ventricular basal septum without any difficulties. The atrial pacing threshold was 1.8 V and the P-wave amplitude was 2.1 mV. Additionally, the ventricular pacing threshold was 0.5 V and the R-wave amplitude was 12.5 mV. A generator Zephyr model 5820 (St. Jude Medical, St. Paul, MN, USA) was then connected and ECG showed normal

*Corresponding author: Egle Majauskiene, Cardiovascular Clinic, Institute of Clinical Medicine, Faculty of Medicine, Vilnius University, Vilnius, Lithuania, Tel: 0037-062637604, E-mail: ebutkute@gmail.com.

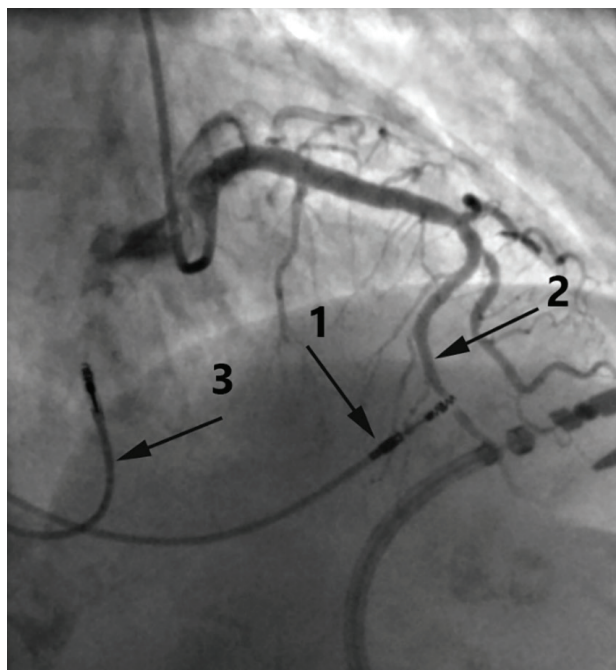
dual-chamber pacing. After the procedure, an ECG was obtained showing ST-segment elevation in the anteroseptal leads V1-V5. An hour later, atrial fibrillation occurred and sinus rhythm was restored with 200 J impulse. Due to suspicion of complication, an immediate chest X-ray and a two-hour chest computed tomography were performed, but they did not show any complications. Nonetheless, the patient complained about chest pain on the next day (18 hours after pacemaker implantation). ECG showed ST-segment elevation in the anteroseptal leads V1-V5, abnormal Q waves in II, aVF, and V3-V6, and a negative T-wave in III, aVF, and V3-V5. Laboratory tests were carried out, as well (Table 1). Elevation of troponin and creatinine kinase as well as ischemic changes on ECG were interpreted as anteroseptal Q-wave ST-segment Elevation Myocardial Infarction (STEMI) and, consequently, coronary angiography was performed immediately. Accordingly, a pacemaker electrode screwed into the 8th segment of the Left Anterior Descending (LAD) coronary artery was found (Figure 1). The partially occluded flow of the coronary artery was restored by 2.75 x 18 mm bare-metal stent implantation and the electrode position was corrected. After percutaneous transluminal coronary angioplasty, the patient remained hemodynamically stable.

Echocardiography revealed a slight decrease in ejection fraction (45 - 50%), akinesis of apical and basal-septal segments, relative thickness of the left ventricular wall, abnormal relaxation form of diastolic dysfunction, mild aortic regurgitation, and small pericardial effusion. After 11 days of hospitalization, the patient was transferred to the cardiac rehabilitation department for further treatment. Additionally recommended medications were aspirin, clopidogrel, and beta-blockers.

3. Discussion

Myocardial infarction caused by an active-fixation ventricular pacing lead screwed into the coronary artery is a particularly rare complication of pacemaker implantation. In the present case, the paroxysmal atrial fibrillation following the procedure was an early sign of a possible complication. Atrial fibrillation is considered to be a frequent complication of acute myocardial infarction, which occurs in 6 - 21% of patients with myocardial infarction and is associated with increased in-hospital and long-term mortality rates (5). After sinus rhythm restoration, our patient underwent further examination for possible complications of pacemaker implantation, but myocardial infarction had not been suspected until the following day when the patient complained about chest pain. Despite

Figure 1. Coronary Angiography Demonstrating an Extremely Rare Complication



The ventricular lead was (1) screwed into the 8th segment of the left anterior descending coronary artery (2). The atrial lead (3) did not interact with coronary arteries.

the fact that ECG had shown ST-segment elevation after pacemaker implantation, it was not interpreted as an acute myocardial ischemia. Evaluation of ECG could be difficult and misleading during the pacing of the right cardiac chambers due to the presence of a left bundle-branch block. Difficulties of suspecting acute myocardial infarction led to an 18-hour delay in treatment. It could be assumed that the late diagnosis of acute myocardial infarction was due to doubts about the origin and coincidence of ischemia with pacemaker implantation that were suspected to be related, while this particularly rare complication was not taken into consideration or might not be known at all.

To our knowledge, there are only seven published clinical cases describing coronary arteries injuries during pacemaker implantation: a penetration of the electrode into the LAD coronary artery (6), right coronary artery spasm (7), two reports of the right coronary artery perforation by active-fixation atrial pacing lead (8,9), a tip of lead positioned into the left circumflex artery (10), and two cases of coronary artery fistulas (11). In all cases, the time interval between the initial procedures to the onset of symptoms varied from

Table 1. The Results of Laboratory Tests

Laboratory Test	Result	Normal Range
CRP, nmol/L	54.29	≤ 47.62
K, mmol/L	4.5	3.8 - 5.3
Na, mmol/L	138	134 - 145
Cl, mmol/L	107	98 - 107
CK-MB, µg/L	153.78	Female: < 3.1
Creatinine, µmol/L	65	Female: 53 - 97
Troponin I, µg/L	78.404	Female: ≤ 0.0156

Abbreviation: CRP, C-reactive protein; CK-MB, creatinine kinase isoenzyme MB.

the moment of procedure to up to 6 years after pacemaker implantation. Similar to the present case, symptoms started within one hour after the procedure in three reported cases (6, 7, 10). In contrast to these cases where the first symptom of the complication was chest pain, our patient complained about chest pain on the next day.

Pacemaker implantation is performed under fluoroscopic control. However, it is rarely combined with coronarography, which can assist the operator by visualizing the coronary arteries during the procedure. Main coronary arteries are most likely injured if leads perforate myocardium because major branches lie between the myocardium and epicardium, and only minor branches pass into the myocardium. A meta-analysis of 28 studies performed over the last 25 years revealed that the average perforation rate of pacemaker leads was 0.82% (12). However, the frequency of coronary arteries injuries is unknown; only isolated cases have been reported.

Dual-chamber pacemaker leads are usually fixed in the right atrial appendage and apex or septum of the right ventricle. Right ventricular septal fixation of pacemaker leads has fewer complications of myocardial perforation and reduced left ventricular systolic function (13). Septal pacing seems to be more physiological because the electrode next to the His bundle and observed QRS complexes are narrower in comparison to apical myocardial stimulation (14). However, too high site of lead implantation in basal septum could be dangerous due to a possible left coronary artery injury close to its bifurcation, which would cause large myocardial ischemia (15). Positioning of pacing leads into the right ventricular outflow tract suggests a greater risk of anterior interventricular artery injury due to the anatomical proximity of these structures (6, 16). Based on the report by Pang BJ et al., a majority of right ventricular pacemaker leads implanted on the septum using conventional fluoroscopic criteria were indeed implanted on the anteroseptal junction (15). These leads were four times closer to the overlying LAD coronary artery compared to those in the right ventricular septum. An estimated median distance of the pacing leads in the anteroseptal junction to the LAD coronary artery was 4.7 mm (15). Our case report also proved that proximity of these structures could lead to LAD coronary artery occlusion and myocardial ischemia.

Our experience demonstrated the importance of considering coronary artery injury as a rare but possible complication of pacemaker implantation. LAD coronary artery injury can be avoided by implanting the pacemaker ventricular lead on the true septum. Yet, further researches are needed to improve fluoroscopic criteria or raise new criteria for proper electrode implantation. For example, Pang BJ et al. analyzed lead positions via cardiac computed tomography and correlated it with ECGs and fluoroscopic projections. Moreover, researchers have suggested that aiming for the middle of the cardiac silhouette in the 40° Right Anterior Oblique (RAO) fluoroscopic view, confirming rightward orientation in the 40° Left Anterior Oblique (LAO) view, and having a paced QRS duration < 140 ms might provide cardiologists with a simple, more accurate method to achieve true right ventricular septal lead positioning and avoid LAD injury (15).

Acknowledgements

The case report was conducted in Cardiovascular Clinic, Institute of Clinical Medicine, Vilnius University, Vilnius, Lithuania.

Authors' Contribution

All authors had equal roles in manuscript preparation and edition.

Financial disclosure

The authors declare that there is no conflict of interests.

Funding/Support

This study was not supported.

References

1. Armaganijan LV, Toff WD, Nielsen JC, Andersen HR, Connolly SJ, Ellenbogen KA, et al. Are elderly patients at increased risk of complications following pacemaker implantation? A meta-analysis of randomized trials. *Pacing Clin Electrophysiol.* 2012;**35**(2):131-4.
2. Gadler F, Valzania C, Linde C. Current use of implantable electrical devices in Sweden: data from the Swedish pacemaker and implantable cardioverter-defibrillator registry. *Europace.* 2015;**17**(1):69-77.
3. Gupta N, Kiley ML, Anthony F, Young C, Brar S, Kwaku K. Multi-Center, Community-Based Cardiac Implantable Electronic Devices Registry: Population, Device Utilization, and Outcomes. *J Am Heart Assoc.* 2016;**5**(3):e002798.
4. Urra FG, Luque Lezcano AO, Cardiologic Intensive C, Cardiopulmonary Resuscitation Section of the Spanish Society of Intensive Care Medicine C, Coronary U. MAMI registration report 1996-2010. *Cardiol J.* 2012;**19**(6):603-11.
5. Schmitt J, Duray G, Gersh BJ, Hohnloser SH. Atrial fibrillation in acute myocardial infarction: a systematic review of the incidence, clinical features and prognostic implications. *Eur Heart J.* 2009;**30**(9):1038-45.
6. Parwani AS, Rolf S, Haverkamp W. Coronary artery occlusion due to lead insertion into the right ventricular outflow tract. *Eur Heart J.* 2009;**30**(4):425.
7. Tint D, Ortan FO, Ursu ME, Micu S. Right coronary artery spasm-a complication of cardiac pacemaker implantation. *Anadolu Kardiyol Derg.* 2013;**13**(8):815-8.
8. Nakagawa E, Abe Y, Komatsu R, Naruko T, Itoh A. Right coronary artery perforation by an active-fixation atrial pacing lead resulting in life-threatening tamponade. *J Arrhythm.* 2015;**31**(5):313-5.
9. Overbeck M, Kolb C, Schmitt C, Schomig A, Lange R. Accidental transarterial implantation of dual chamber pacemaker leads in the left ventricle and the right coronary artery. *Pacing Clin Electrophysiol.* 2005;**28**(5):469-71.
10. Issa ZF, Gill JB. Transarterial pacemaker lead implantation results in acute myocardial infarction. *Europace.* 2010;**12**(11):1654-5.
11. Saeian K, Vellinga T, Troup P, Wetherbee J. Coronary artery fistula formation secondary to permanent pacemaker placement. *Chest.* 1991;**99**(3):780-1.
12. Vamos M, Erath JW, Benz AP, Bari Z, Duray GZ, Hohnloser SH. Incidence of Cardiac Perforation With Conventional and With Leadless Pacemaker Systems: A Systematic Review and Meta-Analysis. *J Cardiovasc Electrophysiol.* 2017;**28**(3):336-46.
13. Mond HG. The road to right ventricular septal pacing: techniques and tools. *Pacing Clin Electrophysiol.* 2010;**33**(7):888-98.
14. Victor F, Mabo P, Mansour H, Pavin D, Kabalu G, de Place C, et al. A randomized comparison of permanent septal versus apical right ventricular pacing: short-term results. *J Cardiovasc Electrophysiol.* 2006;**17**(3):238-42.
15. Pang BJ, Joshi SB, Lui EH, Tacey MA, Ling LH, Alison J, et al. Validation of conventional fluoroscopic and ECG criteria for right ventricular pacemaker lead position using cardiac computed tomography. *Pacing Clin Electrophysiol.* 2014;**37**(4):495-504.
16. Pang BJ, Joshi SB, Lui EH, Tacey MA, Alison J, Seneviratne SK, et al. Proximity of pacemaker and implantable cardioverter-defibrillator leads to coronary arteries as assessed by cardiac computed tomography. *Pacing Clin Electrophysiol.* 2014;**37**(6):717-23.