

Postcholecystectomy bile duct injuries: evolution of surgical treatment

Audrius Šileikis¹, Rūta Žulpaitė², Auksė Šileikytė², Martynas Lukšta²

¹Clinic of Gastroenterology, Nephrourology and Abdominal Surgery, Institute of Clinical Medicine, Faculty of Medicine, Vilnius University, Vilnius, Lithuania
²Vilnius University, Faculty of Medicine, Lithuania

Article history: Received: 15.09.2018 Accepted: 10.12.2018 Published: 11.12.2018

ABSTRACT:

Introduction: Bile duct injuries (BDIs) still occur during laparoscopic cholecystectomy. Although management of such complications is challenging, collaboration of a multidisciplinary team and development of treatment methods and materials often lead to successful treatment.

Materials and methods: Medical records of 67 patients who have experienced bile duct injuries after laparoscopic cholecystectomy were retrospectively reviewed. All injuries were classified according to the European Association for Endoscopic Surgery ATOM classification and investigated by manifestation of the injury, surgical repair technique, early and late complications.

Results: In 28 (41.8 %) patients with partial divisions, the surgical treatment of BDI was completed with endoscopic retrograde cholangiopancreatography (ERCP) and stenting while in 14 (20.1%) cases, the defect of bile duct was closed by suture. End-to-end ductal anastomosis was performed for 6 (13.4%) patients with complete division while 19 (28.3%) patients underwent hepaticojejunostomy. We followed up 58 (92.1%) of 63 patients. The mean follow-up duration was 25.7 (3 - 123) months. Twenty-three (39.7%) patients were found to have strictures.

Discussion: Intraoperative detection and management of BDIs is crucial to achieve good results. The routine intraoperative cholangiography and possibilities of repair by initial surgeons in peripheral hospitals remain controversial. Stenting with a covered self-expanding metal stent is promising for the patients with partial divisions of bile ducts. Initial hepaticojejunostomy is often a preferred treatment for transected bile ducts because of a lower rate of anastomosis strictures. However, as end-to-end anastomosis is more physiological, and endoscopy allows successful management of the strictures, we suggest choosing this treatment when possible. Recommendation for paperwork content: Classifying bile duct injuries according to the new ATOM classification may be useful in choosing the most appropriate treatment in each case.

KEYWORDS:

complications, laparoscopic cholecystectomy, bile duct injury

INTRODUCTION

Cholecystectomy is one of the most routinely performed procedures in surgery and a gold standard for the patients with symptomatic cholelithiasis. Despite the fact that laparoscopic cholecystectomy has been practiced for more than 25 years, bile duct injuries (BDI) still occur during this procedure with a rate of 0.3-0.86% [1].

The most recent studies report that the incidence of BDIs after laparoscopic cholecystectomy has not changed during the last decade [2, 3]. As this complication may endanger or at least significantly impair the quality of life in patients who are mostly otherwise healthy, it is essential to choose the most effective way of treatment in each case when injury has not been avoided.

Even though management of such complications is challenging, collaboration of a multidisciplinary team and development of treatment methods and materials often minimize the harm to patients [4]. In this study, we present our 15 years' experience in the management of BDIs after laparoscopic cholecystectomy. The aim of this retrospective study was to evaluate our results of treatment and to calculate what was developed and improved during this period.

MATERIALS AND METHODS

We retrospectively reviewed medical records of patients treated in our Center from 2002 to 2017 due to BDI after laparoscopic cholecy-

stectomy. All injuries were classified according to the European Association for Endoscopic Surgery (EAES) ATOM classification [5]. Gender and age of the patients, manifestation of BDI (bile leak through the drainage period, peritonitis, hyperbilirubinemia, intra-abdominal infection), time of BDI detection, surgical repair technique (endoscopic retrograde cholangiopancreatography (ERCP) and stenting, closing the defect by suture, end-to-end anastomosis, hepaticojejunostomy), early outcomes after operation according to the Clavien-Dindo classification [6] and late complications focusing on bile duct strictures were investigated.

Ethylene-vinyl acetate (Olympus, Hamburg, Germany) and fully covered self-expanding-metal stents (Hanaro, M.I. Tech, Seoul, Korea) from 7.5 – Fr to 11.5 Fr were used in our study. Experienced surgeons and endoscopists performed all procedures. To conduct the research, permit No. EK-13 (2016-03-03) was received from our Hospital Ethics Commission. Informed consent is not necessary due to the retrospective design of the study.

RESULTS

A total of 67 patients with BDIs after laparoscopic cholecystectomy were treated in our Center from 2002 to 2017. Among them, there were 30 (44.7%) males and 37 (55.3%) females. The mean age of patients was 60.45 ± 16.2 years. In 27 (40.9%) cases, BDI occurred in our hospital while the remaining 40 (59.7%) patients were referred from peripheral hospitals. Thirty-two (47.8%) of 67 pa-

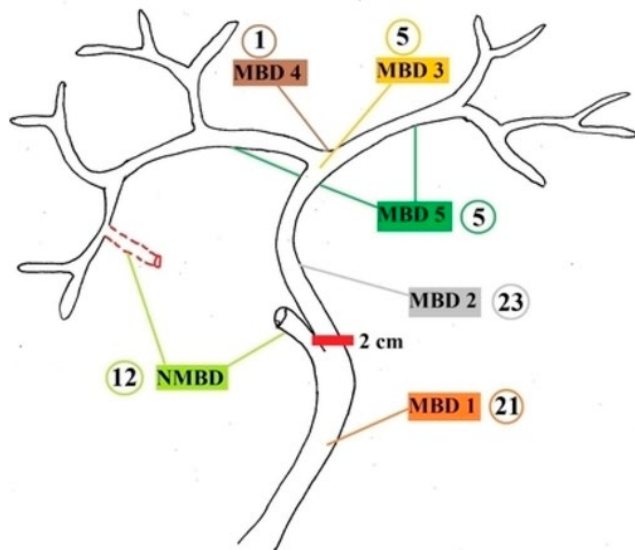


Fig. 1. Anatomic levels of bile duct injuries: NMBD—nonmain biliary duct, MBD1— ≥ 2 cm from lower border of superior biliary confluence, MBD2— < 2 cm from lower border of superior biliary confluence, MBD3 involves the superior biliary confluence but communication right left is preserved, MBD4 involves superior biliary confluence but communication right left is interrupted, MBD5 right or left hepatic duct.

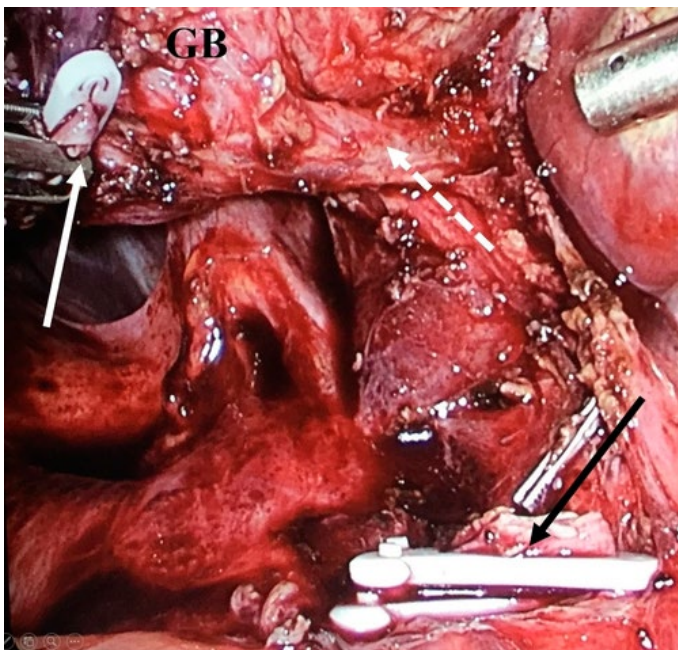


Fig. 2. Intraoperative detection of BDI. A clipped and cut proximal part of the common bile duct is visible (black arrow); a clipped and cut distal part of the common bile duct is visible (white arrow); common hepatic duct (white dashed arrow) and gallbladder (GB) merge without apparent cystic duct.

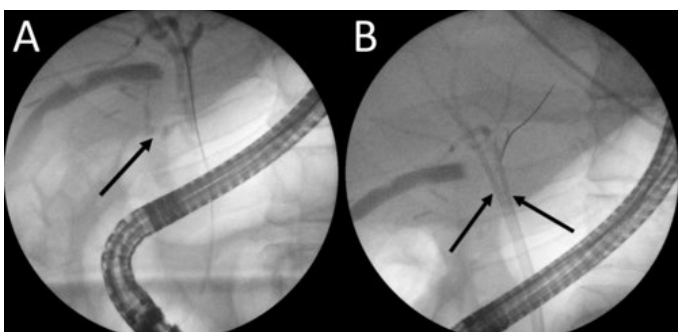


Fig. 3. Bile leak detection and management by ERCP. A—Extravasation of contrast in the region of the cystic duct is visible. B—After the insertion of stents into the right and left hepatic ducts no contrast extravasation is visible.

tients were operated on due to acute cholecystitis and 35 (52.2%) due to chronic cholecystitis; one of them was diagnosed with gallbladder cancer after a final pathological examination.

Early complications were evaluated according to the Clavien-Dindo classification. The morbidity and mortality after surgical repair of BDI were high: I – 2 (3%), II – 1 (1.5%), III – 61 (91%) and V (mortality) – 4 (6%). We followed up 58 (92.1%) of 63 patients (4 of 67 patients died). The mean follow-up duration was 25.7 (3 - 123) months.

Anatomic characteristics of BDI

The most common anatomic levels of BDIs were the main bile duct (MBD) 2 – 23 (34.3%) and MBD1 – 21 (31.3%) (Figure 1); the most complicated levels – MBD2 – 23 (34.3%) and MBD3 – 5 (7.5%). A total of 39 injuries were detected in these 28 patients and among them there were 11 complete divisions with a loss of substance.

Time of detection

In 17 (25.4%) patients, BDIs were detected in early intraoperative time. All the intraoperative diagnoses were made in our hospital making a total of 63% of BDIs that occurred in our center (Figure 2). In other cases, patients from other hospital presented with bile leak through the drainage (25 (50%)), peritonitis (10 (20%)), hyperbilirubinemia (8 (16%)) or intraabdominal abscess (7 (14%)). Endoscopic retrograde cholangiopancreatography (ERCP) (Figure 3), spiral computed tomography (CT) scan, magnetic resonance imaging (MRI) (Figure 4) or intraoperative cholangiography (Figure 5) was used to specify the anatomic level of BDI.

After early intraoperative detection, 8 injuries were closed by suture; 1 injury was managed with ERCP and stenting (it was technically impossible to close the duct with laparoscopic approach); 3 patients underwent end-to-end ductal anastomosis; and hepaticojejunostomy was performed in 5 patients.

The remaining 50 (74.6%) patients were operated on in the early or late postoperative period immediately after the detection of BDI. Endoscopic retrograde cholangiopancreatography before surgical treatment was performed in almost all of them (45 (90%) of 50). Spiral CT scan or MRI with intravenous contrast was used for diagnostics in 8 (16%) patients with hyperbilirubinemia or suspected intraabdominal infection.

Mechanism

Mechanical injuries occurred in 61 (91%) cases. The remaining 6 (9%) patients had energy driven injuries. We preferred gallbladder dissection with scissors.

BDI MANAGEMENT

ERCP and stenting

In 28 (41.8 %) patients, surgical treatment of BDI was completed with ERCP and stenting. Twelve (42.9%) of these patients were successfully managed with one single stenting – 9 (75%) with plastic and 3 (25%) with a covered self-expanding metal stent (Table I).

In 16 (57.1 %) of the remaining patients, additional operations were performed: 5 (31.1 %) patients underwent laparotomy and drainage; 3 (18.8%) patients received restenting twice; 3 (18.8%) – sonoscopic drainage of bile collections; 3 (18.8%) - laparotomy defect closure by suture and drainage; 2 (12.5 %) patients – relaparoscopy and drainage. One (3.6 %) patient died soon after relaparoscopy. In 5 (17.8%) of 28 patients, bile duct occlusions with gallstones were found. All of them were successfully treated endoscopically. Twenty-six (92.3%) of 28 patients were followed up on average 26 (3 - 39) months. In the late postoperative period, 12 (46.2%) patients needed multiple restentings (collectively 44). For 2 (16.6%) of them, balloon dilation was necessary and 3 (25%) patients underwent hepaticojejunostomy due to recurrent bile duct strictures.

Defect closure by suture

In 14 (20.1%) cases, the defect of bile duct was closed by suture. Additional treatment was necessary for 6 of them (Table II). One patient died from liver cirrhosis. Eleven (84.6%) of 13 patients were followed up on average of 23.5 (3 - 123) months. One patient in the late postoperative period underwent hepaticojejunostomy due to the stricture which damaged more than 50% of the bile duct lumen.

End-to-end anastomosis

End-to-end ductal anastomosis was performed for 6 (13.4%) patients (Table III). No extra interventions were necessary in the early postoperative period after end-to-end anastomosis. All 6 patients (100%) were followed up on average 46 (10 - 28) months. In the late postoperative period, only one patient did not need additional procedures. The other 5 (83.3%) patients developed anastomosis strictures that were managed with multiple stenting and balloon dilations. Two (40%) patients finally underwent hepaticojejunostomy since attempts to treat strictures endoscopically were unsuccessful.

Hepaticojejunostomy

Hepaticojejunostomy was performed in 19 (28.3%) patients (Table IV). Concomitant injury of the right hepatic artery was detected in 2 (10.5%) cases. Hepaticojejunostomy was successful in 15 (78.9%) of 19 patients. Four (21.1%) patients developed early postoperative complications which required relaparotomy or sonoscopic drainage of abscess. One (5.3%) patient died from septic complications. Fifteen (78.9%) of 19 patients were followed up on average 18.7 (11 - 30) months. In late postoperative time, 5 (27.8%) patients developed strictures. Rehepaticojejunostomy was performed in 4 (80%) of them and 1 (20%) patient underwent percutaneous cholangiostomy and balloon dilation.

DISCUSSION

As literature reveals, BDIs remain an extremely problematic complication with a high morbidity (9.3%-43%) and an early mortality (0%-1.7%) reported [11]. The complication rate according to the Clavien-Dindo classification in our study was 3% for grade I, 1.5% for grade II and 91% for grade III. Mortality rate was 6%. The success of BDI management depends on various factors, such as anatomic location of the injury, presence of concomitant vascular injury, time of detection of BDI, acuteness of inflammation, and ge-

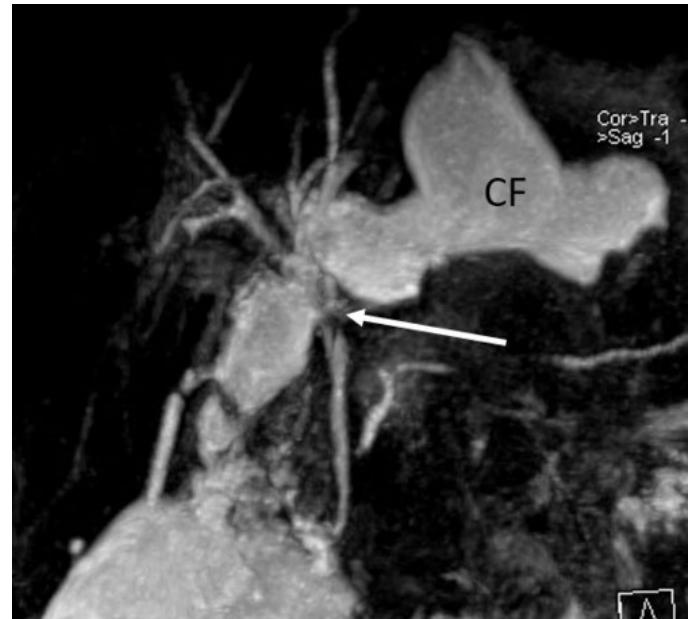


Fig. 4. BDI detection by MRI. The open end of the left hepatic duct at the level of bifurcation is visible (white arrow). The massive collection of fluid (CF) in the subhepatic space coming from the left hepatic duct is visible.

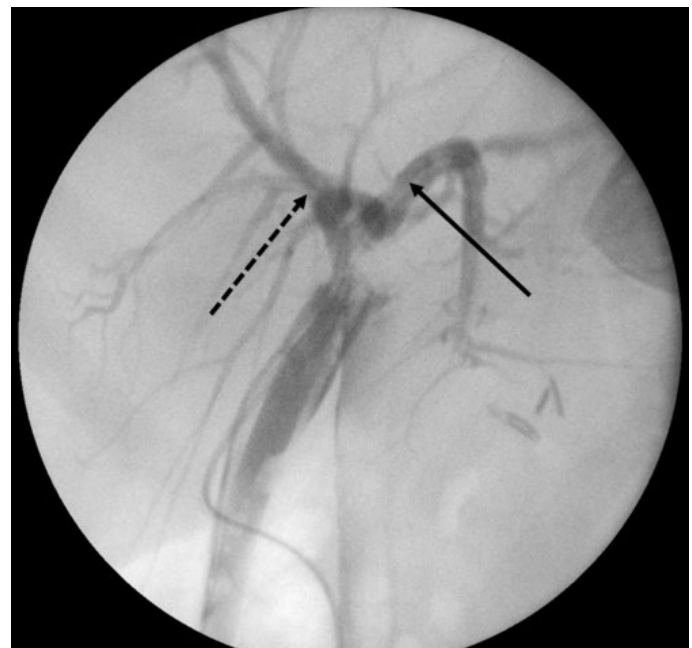


Fig. 5. Loss of communication between right and left hepatic ducts detected by intraoperative cholangiography. Right (black dashed arrow) and left (black arrow) hepatic ducts are contrasted separately after injection of the contrast media through the different drains.

neral state of the patient, as well as experience of the surgeons [11].

It is preferable that all BDIs be detected intraoperatively. Rystedt et al. [12, 13] reported that an exceptionally high proportion of BDIs were diagnosed during the cholecystectomy – 92%. The average length of hospital stay for patients with BDIs detected intraoperatively was significantly shorter (14 days vs. 58 days) [12] and the quality of life was comparable to patients who underwent cholecystectomy without complications [13]. Although many recent studies report markedly better outcomes when bile duct reconstruction is performed in a tertiary center/referral hepatobiliary center [14-16], Rystedt et al. [12, 13] state that immediate repair in conjunction with cholecystectomy can be successful even when

Tab. I. Results of our center in treating BDI using ERCP and stenting.

Anatomic level	ANATOMICAL CHARACTERISTICS					TIME OF DETECTION			MECHANISM		TREATMENT ERCP + stenting (single)	
	Type and extent of injury					VB injury	Ei	Ep	L	Me		ED
	Occlusion		Division									
C	P	C	P	LS								
MBD												
1				6				4	2	5	1	3
2				9			1	6	2	7	2	2
3				1				1			1	
4				1					1	1		
5				2				2		2		1
6												
NMBD		9					1	6	2	9		6
Total				28								

MBD main biliary duct, NMBD nonmain biliary duct, level 1 \geq 2 cm from lower border of superior biliary confluent, level 2 < 2 cm from lower border of superior biliary confluent, level 3 involves the superior biliary confluent but communication right left is preserved, level 4 involves superior biliary confluent, but communication right left is interrupted, level 5a right or left hepatic duct, level 5b right sectorial duct but bile duct still continuity, C complete, P partial, LS loss of substance, Me mechanical, ED energy driven, VBI vascular and biliary involvement, RHA right hepatic artery, Ei early intraoperative, Ep early postoperative (fewer than 7 days), L late (more than 7 days).

Tab. II. Results of our center in treating BDI using closure by suture.

Anatomic level	ANATOMICAL CHARACTERISTICS					TIME OF DETECTION			MECHANISM		TREATMENT			
	Type and extent of injury					VB injury	Ei	Ep	L	Me	ED	Closure by suture	Closure by suture + ERCP and stenting	Repeated surgery and suturing
	Occlusion		Division											
C	P	C	P	LS										
MBD														
1			7			6			1	7		2	4	1
2			4					4		4		4		
3														
4														
5			1			1				1			1	
6														
NMBD			2			1			1	2		2		
Total			14											

MBD main biliary duct, NMBD nonmain biliary duct, level 1 \geq 2 cm from lower border of superior biliary confluent, level 2 < 2 cm from lower border of superior biliary confluent, level 3 involves the superior biliary confluent but communication right left is preserved, level 4 involves superior biliary confluent, but communication right left is interrupted, level 5a right or left hepatic duct, level 5b right sectorial duct but bile duct still continuity, C complete, P partial, LS loss of substance, Me mechanical, ED energy driven, VBI vascular biliary involvement, RHA right hepatic artery, Ei early intraoperative, Ep early postoperative (fewer than 7 days), L late (more than 7 days).

performed by an index surgeon in a non-hepatobiliary center. We believe that delaying repair of intraoperatively detected BDI is inexcusable when seeking the best possible outcomes. Therefore, we support attempts to repair injury immediately, even in peripheral hospitals if there is any possibility. However, the high rate of early intraoperative BDI detection remains a goal to achieve. Only 25.4% of cases were detected during cholecystectomy in our study, which is comparable to other recent studies [17-20]. This rate is not satisfactory, as delayed diagnosis worsens the general condition of a patient and makes the repair more difficult. Intraoperative cholangiography for BDI prevention during cholecystectomy is not routinely used in our hospital, and this question remains controversial. However, Rystedt et al. [12, 13] explain that such a high rate of intraoperative diagnosis is a result of Swedish surgery tradition to perform intraoperative cholangiographies frequently. In their other study, the same group revealed that routine intraoperative cholangiography is a cost-effective method [21].

Another highly discussed question is the time of bile duct reconstruction when BDI is detected postoperatively. It seems that biliary leaks in the absence of complete division of the bile duct may be successfully managed with ERCP and stenting in despite of when the injury was diagnosed [22, 23]. In cases when the bile duct is transected, some authors suggest delaying the reparation until 6 weeks with intent to avoid peritonitis at repair, reduce the local inflammation in the hepatoduodenal area, and to drain abscesses and biloma during this time [24, 25].

Ismael et al. [26] reported similar morbidity but higher mortality among patients who underwent bile duct repair within 30 days after the injury compared to patients undergoing delayed reconstruction. In this study, infection and peritonitis were found as independent predictors of negative outcomes of bile duct repair. However, many recent studies reported similar long-term outcomes of early and late bile duct reconstruction concluding that it is not necessary to wait, and the patient should be operated as

Tab. III. Results of our center in treating BDI using end-to-end anastomosis.

Anatomic level	ANATOMICAL CHARACTERISTICS					TIME OF DETECTION			MECHANISM		TREATMENT	
	Type and extent of injury					VB injury	Ei	Ep	L	Me	ED	End-to-end anastomosis
	Occlusion		Division									
C	P	C	P	LS								
MBD												
1	2		3				3	2		5		5
2					1			1		1		1
3												
4												
5												
6												
NMBD												
Total			6									

MBD main biliary duct, NMBD nonmain biliary duct, level 1 \geq 2 cm from lower border of superior biliary confluent, level 2 < 2 cm from lower border of superior biliary confluent, level 3 involves the superior biliary confluent but communication right left is preserved, level 4 involves superior biliary confluent, but communication right left is interrupted, level 5a right or left hepatic duct, level 5b right sectorial duct but bile duct still continuity, C complete, P partial, LS loss of substance, Me mechanical, ED energy driven, VBI vascular biliary involvement, RHA right hepatic artery, Ei early intraoperative, Ep early postoperative (fewer than 7 days), L late (more than 7 days).

Tab. IV. Results of our center in treating BDI using hepaticojejunostomy.

Anatomic level	ANATOMICAL CHARACTERISTICS					TIME OF DETECTION			MECHANISM		TREATMENT		
	Type and extent of injury					VB injury	Ei	Ep	L	Me	ED	H-J	H-J + additional drainage
	Occlusion		Division										
C	P	C	P	LS									
MBD													
1			3				1	2		3		2	
2			3	1	5		2	7		8	1	8	1
3			0	1	4	1	2	3		4	1	3	1
4													2
5				2		1		2		2		2	
6													
NMBD													
Total			19										

MBD main biliary duct, NMBD nonmain biliary duct, level 1 \geq 2 cm from lower border of superior biliary confluent, level 2 < 2 cm from lower border of superior biliary confluent, level 3 involves the superior biliary confluent but communication right left is preserved, level 4 involves superior biliary confluent, but communication right left is interrupted, level 5a right or left hepatic duct, level 5b right sectorial duct but bile duct still continuity, C complete, P partial, LS loss of substance, Me mechanical, ED energy driven, VBI vascular biliary involvement, RHA right hepatic artery, Ei early intraoperative, Ep early postoperative (fewer than 7 days), L late (more than 7 days).

soon as the injury is detected [14-16, 27]. There is no significant evidence that clearly answers the question of whether bile duct repair should be delayed or not, and in most of the cases the decision remains individual. In our center, we follow a protocol to repair bile ducts as early as the injury is diagnosed, certainly taking into consideration the general state of the patient. We noticed that presentation of other complications such as peritonitis, intraabdominal abscess or severe jaundice within the early postoperative period often convince surgeons to re-operate on the patient and perform bile duct repair during the same procedure.

Several types of surgical or endoscopic treatment are possible depending on the time of detection with its related issues and severity of injury. If diagnosis of BDI is immediate, usually following an intraoperative cholangiography, the most acceptable choice is surgical management performed in conjunction with cholecystectomy – defect closure by suture, end-to-end anastomosis of bile duct or hepaticojejunostomy. Internal drainage solely with T-tube

or ERCP stent should not be a preferred treatment, except for the cases of inadequate technical resources or lack of experience of the index surgeon [14]. We had only one case when intraoperatively diagnosed partial dissection of the duct was managed endoscopically as attempts to close the defect were unsuccessful and bile leaked through the suture.

The main diagnostic method of BDIs in both early and late post-cholecystectomy periods is ERCP, which is usually also a tool of minimal invasive treatment (stenting) for partial divisions of ducts [28]. ERCP is useful not only for detection of anatomic location of injury but also the remaining stones in bile ducts can be successfully removed during this procedure – we had 5 such cases. As has been well-described in the literature, endoscopic treatment (typically ERCP and a short transpapillary stent placement) is the most appropriate choice for cystic stump leaks with a success rate reaching 100% [28]. In our study, 7 of 8 patients with cystic stump leaks were successfully managed endoscopically; 1 patient suddenly

died in the early postoperative period. According to the European Society of Gastrointestinal Endoscopy (ESGE) clinical guideline, partial divisions of ducts can be successfully treated endoscopically in more than 90% of cases [22]. Endoscopic therapy of postcholecystectomy bile duct strictures by placing multiple plastic stents with or without balloon dilation seems to be efficient in 75.5-100% of cases [29-33]. Costamagna et al., who first introduced this aggressive endoscopic approach in 2001 [29], reported very good results after a mean follow-up period of 13.7 years: Only 11.4% patients had recurrent strictures after more than 6 years from the end of treatment [34]. The main disadvantage of the multiple stenting strategy, which increases costs and inconvenience for the patient, is necessary for repeated ERCP sessions – placement of additional large-bore plastic stents (10Fr) and exchanging stents every 3-6 months for at least 1 year [35]. As an alternative, self-expandable metallic stent placement can be considered. While this method is widely used and effective for long-term palliation of malignant bile duct obstructions [22], the idea to use it for benign biliary strictures is still under discussion. Compared with malignant diseases, the bile duct after cholecystectomy complication is otherwise not harmful; therefore, self-expanding metal stents must be partially or fully covered to avoid ingrowth and make them possible to remove [36]. Despite the high price and possible limitations of this method compared to multiple plastic stenting [37], recent studies showed promising results. Kahaleh et al. [37] reported stricture resolution in 90% (59 of 65) of patients after a median follow-up of 12 months. Other studies showed similar efficacy of covered self-expandable metallic stents [38, 39]. While endoscopic plastic stent placement is successful in most of the bile leaks, the role of self-expandable metallic stents in this situation seems to be limited. However, these types of stents may be considered as an option for patients who fail conventional endoscopic therapy and present refractory bile duct leaks or in cases of high-grade leaks [36]. Recently published studies show that fully covered self-expandable metallic stent placement allows healing of biliary leaks at a rate 90.5-100% [23, 40-42]. In our study, 12 (42.9%) of 28 patients were successfully treated with one stenting – 9 of them with plastic and 3 with a covered self-expandable metallic stent. All attempts to use self-expandable metallic stents were successful and we noticed that using this stent once is less demanding on the patient and more cost-effective compared with multiple plastic stenting. Therefore, we seek to incorporate covered self-expandable metallic stents as an improvement to our routine practice of BDI management.

It is well agreed that intraoperatively diagnosed partial divisions of bile ducts should be closed by suture and abdominal drains placed in the area [43, 44]. In our study, 8 cases of intraoperative BDI were managed by primary defect closure. However, 5 of 8 (62.5%) patients developed complications which required additional treatment (stenting, secondary closure or hepaticojejunostomy). The limited number of patients may explain this discordance with recommendations.

The treatment is much more challenging when the division of the duct is complete, with or without loss of substance. The choice between end-to-end anastomosis of the transected duct and hepaticojejunostomy is a highly discussed topic in the literature. Some authors report a preference for the initial hepaticojejunostomy as a treatment with a lower rate of anastomosis strictures, while the others support end-to-end anastomosis that is more physiological. It has been suggested that the rate of postoperative end-to-

-end anastomosis strictures may reach 80%, which is consequently associated with a high incidence of secondary repair [45, 46]. For this reason, many authors prefer hepaticojejunostomy as a first-line treatment. We observe the same tendency in our practice: For 15 years, end-to-end anastomosis was performed only for 6 patients with BDI compared with 19 hepaticojejunostomies. None of the patients with end-to-end anastomosis had early postoperative complications, however, 5 of them (83.3%) later developed anastomosis strictures, and this corresponds to the previously mentioned data of other authors [45, 46]. As opening of the alimentary tract is necessary to perform bilioenteric anastomosis, this treatment has a higher rate of early postoperative complications [47]. In our study, 4 patients (21.1%) presented with peritonitis and abdominal abscess after hepaticojejunostomy. The rate of late postoperative strictures for hepaticojejunostomy was 5 of 19 cases (27.8%), which is much lower compared to end-to-end anastomosis strictures. However, after hepaticojejunostomy, bile flows directly to the jejunum, excluding the duodenum. It is reported that such a disturbance of physiology impairs natural release of gastrointestinal hormones and subsequently leads to maldigestion, malabsorption, as well as increased risk of duodenal ulcers for these patients [3, 47]. Another advantage of end-to-end ductal anastomosis is the availability to manage postoperative strictures by endoscopic dilation, which is not possible for the strictures of bilioenteric anastomosis. In our study, 3 out of 5 patients who developed strictures after end-to-end anastomosis were successfully managed with several series of stenting and balloon dilation. Hepaticojejunostomy was necessary for the remaining 2 cases that failed endoscopic treatment. To compare, 4 of 5 strictures that developed after the initial hepaticojejunostomy required relaparotomy with re-hepaticojejunostomy and one was managed with a percutaneous transhepatic biliary drainage and balloon dilation. Since an endoscopic approach is currently well developed, recent larger studies reveal good long-term outcomes of end-to-end anastomosis. In the series of Reuver et al. [18], 56 patients were managed endoscopically after stricture of end-to-end anastomosis with 91% overall 5 years stricture-free survival. Kohneh et al. [48] reported better results with end-to-end ductal anastomosis (100%) than with hepaticojejunostomy (71.4%) when repair was performed less than 30 days after the initial injury. Some authors recommend performing end-to-end anastomosis only in the presence of appropriate conditions, that is when BDI is detected intraoperatively, there is no extensive loss of substance and it is possible to connect endings without tension [18]. If the duct is thinner than 4 mm, more than 4 cm of tissue is lost, or the endings of transection are influenced by inflammation, hepaticojejunostomy should be performed [47, 49]. We believe that maintenance of physiological bile flow, higher possibility to manage postoperative complications in a minimally invasive way and to avoid relaparotomy is a huge advantage of end-to-end ductal anastomosis.

To sum up, intraoperative detection of BDI is preferable, however, it still needs improvement. When BDI is detected postoperatively, management should not be delayed, if possible. Endoscopic retrograde cholangiopancreatography is undoubtedly the main diagnostic tool for postoperatively suspected injuries and the main approach for injuries that maintain continuity of duct. Stenting with a covered self-expandable metallic stent is a new, effective and promising method for these patients. Both hepaticojejunostomy and end-to-end anastomosis of ducts showed good results while treating complete divisions of bile ducts.

REFERENCES

- Ingraham AM, Cohen ME, Ko CY et al.: A Current Profile and Assessment of North American Cholecystectomy: Results from the American College of Surgeons National Surgical quality improvement program. *J Am Coll Surg.* 2010; 211(2): 176–186;
- Pioche M, Ponchon T: Management of bile duct leaks. *J Visc Surg.* 2013; 150: S33–S38;
- Jablonska B, Lampe P: Iatrogenic bile duct injuries: etiology, diagnosis and management. *World J Gastroenterol.* 2009; 15(33): 4097–4104;
- Khan MH, Howard TJ, Fogel EL, et al.: Frequency of biliary complications after laparoscopic cholecystectomy detected by ERCP: experience at a large tertiary referral center. *Gastrointest Endosc.* 2007; 65(2): 247–252;
- Barrett M, Asbun HJ, Chien HL, et al.: Bile duct injury and morbidity following choelcystectomy: a need for improvement. *Surg Endosc.* 2017;
- Nijssen MA, Schreinemakers JM, Meyer Z, et al.: Complications After Laparoscopic Cholecystectomy: A Video Evaluation Study of Whether the Critical View of Safety was Reached. *World J Surg.* 2015; 39(7): 1798–1803;
- Pucher PH, Brunt LM, Fanelli RD, et al.: SAGES expert Delphi consensus: critical factors for safe surgical practice in laparoscopic cholecystectomy. *Surg Endosc.* 2015; 29(11): 3074–3085;
- de Reuver PR, Rauws EA, Bruno MJ, et al.: Survival in bile duct injury patients after laparoscopic cholecystectomy: a multidisciplinary approach of gastroenterologists, radiologists, and surgeons. *Surgery.* 2007; 142(1): 1–9;
- [9] Fingerhut A, Dziri C, Garden OJ, et al.: ATOM, the all-inclusive, nominal EAES classification of bile duct injuries during cholecystectomy. *Surg Endosc.* 2013; 27(12): 4608–4619;
- Dindo D, Demartines N, Clavien PA: Classification of surgical complications: a new proposal with evaluation in a cohort of 6336 patients and results of a survey. *Ann Surg.* 2004; 240(2): 205–213;
- Barbier L, Souche R, Slim K, Ah-Soune P: Long-term consequences of bile duct injury after cholecystectomy. *J Visc Surg.* 2014; 151(4): 269–279;
- Rystedt J, Lindell G, Montgomery A: Bile Duct Injuries Associated With 55,134 Cholecystectomies: Treatment and Outcome from a National Perspective. *World J Surg.* 2016; 40(1): 73–80;
- Rystedt JM, Montgomery AK: Quality-of-life after bile duct injury: intraoperative detection is crucial. A national case-control study. *HPB (Oxford).* 2016; 18(12): 1010–1016;
- Perera MT, Silva MA, Hegab B, et al.: Specialist early and immediate repair of post-laparoscopic cholecystectomy bile duct injuries is associated with an improved long-term outcome. *Ann Surg.* 2011; 253(3): 553–560;
- Stewart L, Way LW: Laparoscopic bile duct injuries: timing of surgical repair does not influence success rate. A multivariate analysis of factors influencing surgical outcomes. *HPB(Oxford).* 2009; 11(6): 516–522;
- Thomson BN, Parks RW, Madhavan KK, et al.: Early specialist repair of biliary injury. *Br J Surg.* 2006; 93(2): 216–220;
- Fischer CP, Fahy BN, Aloia TA, et al.: Timing of referral impacts surgical outcomes in patients undergoing repair of bile duct injuries. *HPB (Oxford).* 2009; 11(1): 32–37;
- de Reuver PR, Busch OR, Rauws EA, et al.: Long-term results of a primary end-to-end anastomosis in Perioperative detected bile duct injury. *J Gastrointest Surg.* 2007; 11(3): 296–302;
- Stilling NM, Frstrup C, Wettergren A, et al.: Long-term outcome after early repair of iatrogenic bile duct injury. A national Danish multicentre study. *HPB (Oxford).* 2015; 17(5): 394–400;
- Pitt HA, Sherman S, Johnson MS, et al.: Improved outcomes of bile duct injuries in the 21st century. *Ann Surg.* 2013; 258(3): 490–499;
- Rystedt JML, Tingstedt B, Montgomery F, Montgomery AK: Routine intraoperative cholangiography during cholecystectomy is a cost-effective approach when analysing the cost of iatrogenic bile duct injuries. *HPB (Oxford).* 2017; 19(10): 881–888;
- Dumoncau JM, Tringali A, Blero D, et al.: Biliary stenting: indications, choice of stents and results: European Society of Gastrointestinal Endoscopy (ESGE) clinical guideline. *Endoscopy.* 2012; 44(3): 277–298;
- Canena J, Horta D, Coimbra J, et al.: Outcomes of endoscopic management of primary and refractory postcholecystectomy biliary leaks in a multicentre review of 178 patients. *BMC Gastroenterol.* 2015; 15: 105;
- de Reuver PR, Grossmann I, Busch OR, et al.: Referral pattern and timing of repair are risk factors for complications after reconstructive surgery for bile duct injury. *Ann Surg* 2007; 245(5): 763–770;
- Schmidt SC, Langrehr JM, Hintze RE, et al.: Long-term results and risk factors influencing outcome of major bile duct injuries following cholecystectomy. *Br J Surg.* 2005; 92(1): 76–82;
- Ismael HN, Cox S, Cooper A, et al.: The morbidity and mortality of hepaticojejunostomies for complex bile duct injuries: a multi-institutional analysis of risk factors and outcomes using NSQIP. *HPB (Oxford).* 2017; 19(4): 352–358;
- Sicklick JK, Camp MS, Lillemoe KD, et al.: Surgical management of bile duct injuries sustained during laparoscopic cholecystectomy: perioperative results in 200 patients. *Ann Surg.* 2005; 241(5): 786–792;
- Baillie J: Endoscopic Approach to the Patient with Bile Duct Injury. *Gastrointest Endosc Clin N Am.* 2013; 23(2): 461–472;
- Costamagna G, Pandolfi M, Mutignani M, et al.: Long-term results of endoscopic management of postoperative bile duct strictures with increasing numbers of stents. *Gastrointest Endosc.* 2001; 54(2): 162–168;
- Bergman JJ, Burgemeister L, Bruno MJ, et al.: Long-term follow-up after biliary stent placement for postoperative bile duct stenosis. *Gastrointest Endosc.* 2001; 54(2): 154–161;
- De Palma GD, Galloro G, Romano G, et al.: Long-term follow-up after endoscopic biliary stent placement for bile duct strictures from laparoscopic cholecystectomy. *Hepatogastroenterology.* 2003; 50(53): 1229–1231;
- Draganov P, Hoffman B, Marsh W, et al.: Long-term outcome in patients with benign biliary strictures treated endoscopically with multiple stents. *Gastrointest Endosc.* 2002; 55(6): 680–686;
- Kuzela L, Oltman M, Surka J, et al.: Prospective follow-up of patients with bile duct strictures secondary to laparoscopic cholecystectomy, treated endoscopically with multiple stents. *Hepatogastroenterology.* 2005; 52(65): 1357–1361;
- Costamagna G, Tringali A, Mutignani M, et al.: Endotherapy of postoperative biliary strictures with multiple stents: results after more than 10 years of follow-up. *Gastrointest Endosc.* 2010; 72(3): 551–557;
- Perri V, Familiari P, Tringali A, et al.: Plastic biliary stents for benign biliary diseases. *Gastrointest Endosc Clin N Am.* 2011; 21(3): 405–433;
- Pausawasaki N, Soontornmanokul T, Rerknimitr R: Role of Fully Covered Self-Expandable Metal Stent for Treatment of Benign Biliary Strictures and Bile Leaks. *Korean J Radiol.* 2012; 13(Suppl 1): S67–S73;
- Kahaleh M, Behm B, Clarke BW, et al.: Temporary placement of covered self-expandable metal stents in benign biliary strictures: a new paradigm? (with video). *Gastrointest Endosc.* 2008; 67(3): 446–454;
- Saxena P, Diehl DL, Kumbhari V et al.: A US Multicenter Study of Safety and Efficacy of Fully Covered Self-Expandable Metallic Stents in Benign Extrahepatic Biliary Strictures. *Dig Dis Sci.* 2015; 60(11): 3442–3448;
- Mahajan A, Ho H, Sauer B, et al.: Temporary placement of fully covered self-expandable metal stents in benign biliary strictures: midterm evaluation (with video). *Gastrointest Endosc.* 2009; 70(2): 303–309;
- Wang A, Ellen K, Berg C, et al.: Fully covered self-expandable metallic stents in the management of complex biliary leaks: preliminary data – a case series. *Endoscopy.* 2009; 41(9): 781–786;
- Canena J, Liberato M, Horta D, et al.: Short-term stenting using fully covered self-expandable metal stents for the treatment of refractory biliary leaks, post-sphincterotomy bleeding and perforations. *Surg Endosc.* 2013; 27(1): 313–324;
- Akbar A, Irani S, Baron T, et al.: Use of fully covered self-expandable metal stents for endoscopic management of benign biliary disease not related to stricture (with video). *Gastrointest Endosc.* 2012; 76(1): 196–201;
- Pekolj J, Alvarez FA, Palavecino M, et al.: Intraoperative management and repair of bile duct injuries sustained during 10,123 laparoscopic cholecystectomies in a high-volume referral center. *J Am Coll Surg.* 2013; 216(5): 894–901;
- Renz BW, Bösch F, Angele MK: Bile Duct Injury after Cholecystectomy: Surgical Therapy. *Visc Med.* 2017; 33(3): 184–190;
- Rossi RL, Tsao JI: Biliary reconstruction. *Surg Clin North Am.* 1994; 74(4): 825–841;
- Stewart L, Way LW: Bile duct injuries during laparoscopic cholecystectomy. Factors that influence the results of treatment. *Arch Surg.* 1995; 130(10): 1123–1128;
- Jablonska B, Lampe P, Olakowski M, et al.: Hepaticojejunostomy vs. end-to-end biliary reconstructions in the treatment of iatrogenic bile duct injuries. *J Gastrointest Surg* 2009; 13(6): 1084–1093;
- Kohne SN, Lasnier C, Paineau J: Bile duct injuries at laparoscopic cholecystectomy: early repair results. *Ann Chir.* 2005; 130(4): 218–223;
- Mercado MA, Chan C, Orozco H et al.: To stent or not to stent bilioenteric anastomosis after iatrogenic injury: a Dilemma not answered? *Surgery.* 2002; 137(1): 60–3.

Word count: 4530 Page count: 8 Tables: 4 Figures: 5 References: 49

DOI: 10.5604/01.3001.0012.7810 Table of content: <https://ppch.pl/issue/11803>

Copyright: Copyright © 2019 Fundacja Polski Przegląd Chirurgiczny. Published by Index Copernicus Sp. z o. o. All rights reserved.

Competing interests: The authors declare that they have no competing interests.



The content of the journal „Polish Journal of Surgery” is circulated on the basis of the Open Access which means free and limitless access to scientific data.



This material is available under the Creative Commons - Attribution 4.0 GB. The full terms of this license are available on: <http://creativecommons.org/licenses/by-nc-sa/4.0/legalcode>

Corresponding author: Audrius Šileikis; Clinic of Gastroenterology, Nephrourology and Abdominal Surgery, Institute of Clinical Medicine, Faculty of Medicine, Vilnius University, Santariškių Str. 2, LT-08661 Vilnius, Lithuania; E-mail: audrius.sileikis@santa.lt

Cite this article as: Šileikis A., Žulpaitė R., Šileikytė A., Lukšta.: Postcholecystectomy bile duct injuries: evolution of surgical treatment; Pol Przegl Chir 2019; 91 (1): 14–21
