

## Case Report

# Bone Remineralization around Dental Implants following Conservative Treatment after Peri-Implantitis

Algirdas Puisys <sup>1,2</sup>, Viktorija Auzbikaviciute <sup>1,2</sup>, Renata Simkunaite-Rizgeliene,<sup>3</sup>  
Dainius Razukevicius,<sup>4</sup> Rokas Linkevicius,<sup>2,4</sup> and Tomas Linkevicius<sup>2,3</sup>

<sup>1</sup>Vilnius Implantology Center, Vilnius, Lithuania

<sup>2</sup>Vilnius Research Group, Vilnius, Lithuania

<sup>3</sup>Vilnius University, Vilnius, Lithuania

<sup>4</sup>Lithuanian University of Health Science, Kaunas, Lithuania

Correspondence should be addressed to Algirdas Puisys; [algirdas@vicklinika.lt](mailto:algirdas@vicklinika.lt)

Received 1 April 2019; Accepted 8 July 2019; Published 5 September 2019

Academic Editor: Miguel Peñarrocha

Copyright © 2019 Algirdas Puisys et al. This is an open access article distributed under the Creative Commons Attribution License, which permits unrestricted use, distribution, and reproduction in any medium, provided the original work is properly cited.

The aim of this case report is to show that bone remineralization around dental implants with a history of peri-implantitis is possible after irritant factors are removed and only conservative treatment is performed. Patient came to the clinic after three years of dental implant placement complaining about swelling, sensitivity and gingiva color changes at the posterior part of the maxilla. During radiographic and intraoral examinations peri-implantitis of the #24 implant site was diagnosed. The surgical treatment method was rejected and performed conservative treatment instead. The outcome is promising; periapical radiographs three months later showed bone remineralization as well as stable bone after 10 years. *A key clinical message:* Bone remineralization around dental implants with a history of peri-implantitis is possible after irritant factors are removed and conservative treatment performed.

## 1. Introduction

Biological complications predisposed by undetected cement remnants are receiving much attention recently. It was shown that excess cement might be responsible not only for quick peri-implantitis development but also for delayed or chronic manifestation of the disease many years after cementation [1, 2]. In vitro and clinical studies show that it is very difficult or in some cases even impossible to completely clean up cement excess from subgingival margins—the most popular position of a cementation line—when cement-retained restorations are fabricated [3–5]. The outcome of biological complications due to cement excess may vary from temporary inflammation of soft peri-implant tissues without serious esthetic and functional consequences to implant loss. There is a variety of scientific evidence that described treatment modalities to prevent or suppress the disease. However,

there is still the lack of information about nonsurgical treatment and bone remineralization around implants.

This case report describes peri-implantitis caused by residual cement and the solution of the complications and provides a nonsurgical approach of the treatment.

## 2. Case History

A patient presented in 2009 with the main complaint of a fistula and tenderness on chewing and touching of the tissues above the implant restoration (Figure 1). Anamnesis revealed that this case was restored approximately 3 years before.

The patient's history chart showed that a regular connection two-piece implant (BioHorizons Internal, Birmingham, AL, USA) was placed and achieved successful integration. A standard abutment was used to support metal ceramic restoration, which was cemented with glass-ionomer modified

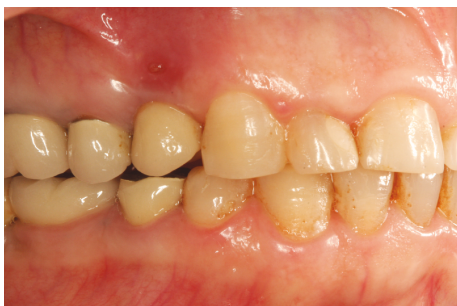

FIGURE 1: Draining sinus tract over implant-supported restoration.

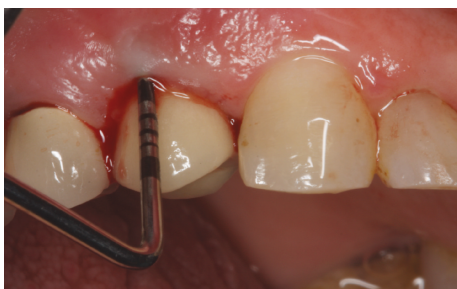

FIGURE 2: Bleeding on probing.

with a resin luting agent (Fuji Plus, GC, Tokyo, Japan). It was recorded in that cement remnants were cleaned, and radiographic examination did not show any residue. The treatment was considered being finished; the patient was satisfied and did not seek any consultation or intervention after the treatment.

Intraoral observation revealed deep pockets up to 8 mm; also, profuse bleeding on probing was recorded (Figure 2). However, general periodontal condition around other teeth was good; BOP and PI around other teeth were  $\leq 15\%$ .

Radiographic examination showed severe crestal bone loss till the third thread of the implant. The bone loss pattern was characteristic to peri-implantitis. No cement remnants could be noticed; also, the bone level of adjacent teeth indicated that the patient is not periodontally involved (Figures 3(a) and 3(b)). Clinical and radiological evaluation helped to determine the diagnosis of chronic peri-implantitis.

Initial treatment plan included removal of the restoration and evaluation of the peri-implant tissues. The restoration occlusal surface was swirled through to get the access to the abutment screw. The screw was loosened, and restoration was removed. Surprisingly, a big piece of cement rest was located in the buccal site of the implant, thus invisible to radiographic examination (Figures 4(a) and 4(b)).

An extensive undercut between the cementation line on the standard abutment (lower arrow) and emergence profile of the restoration in the buccal side (upper arrow) was present (Figure 4(b)). Exactly on this side cement remnant was located in peri-implant mucosa. Thus, undercut can be described as the distance between the cementation (cement extrusion) line and the emergence profile of the restoration.

It was shown that a bigger undercut results in worse cement remnant removal (Vindasiute et al. 2013).

The cement rest was removed, and peri-implant tissues were abundantly rinsed with chlorhexidine-digluconate 0.12% solution (PerioAid, Dentaaid, Barcelona, Spain). There was a bed sore in peri-implant tissues, where cement remnants were resting (Figure 5(a)). Then, chlorhexidine gel (PerioAid Gel, Dentaaid, Barcelona, Spain) was applied on the healing abutment, and it was tightened to the implant (Figures 5(b) and 5(c)). The excess of the gel was washed away. The patient was instructed to rinse the infected site with the same chlorhexidine-digluconate solution twice a day for 1 week.

The patient presented at 1 week after removal of the cement excess. The fistula was not present; the patient did not report any tenderness of the site. Clinically, soft tissues appeared healthy; there was restricted blushing of the gingiva in the place of previous fistula. The removed restoration was screwed back to the implant, and occlusal entrance was isolated with polytetrafluorethylene tape and adhesively covered with composite (Figure 6). The decision was made not to proceed with any kind of antibacterial, surgical, or regenerative treatment of peri-implantitis, and the patient was scheduled for observation visits every 6 months.

### 3. Follow-Up

The patient presented after 1 year post removal of the cement excess without any complains. Radiological examination showed bone remineralization of the previously infected implant (Figure 7(b)). After 2 years, a full regrowth of the crestal bone around the implant was observed (Figure 7(c)). During this time, the patient had an adjacent tooth replaced with an implant. In 2019, 10 years after, a new periapical X-ray reveals stable bone around implant #24 (Figure 7(d)).

Clinically soft tissues were healthy; the bone contour was improved, compared to the previous situation, and only a minor change in soft tissue color remained (Figure 8).

### 4. Discussion

There was a visible crestal bone resorption due to cement remnants in this clinical case. It was shown that an individual abutment does not guarantee total cement excess cleaning at the subgingival margin [6, 7].

However, after the elimination of the residue, not only the soft tissue inflammation resolved but also bone remineralization occurred. This might be compared to remineralization of the alveolar bone around the tooth, which also can be expected. It was shown that bone regeneration occurs in infrabony pockets in patients maintained on an optimal standard of oral hygiene [8]. When infection and irritants are removed, remineralization of the bone organic matrix occurs. It can be speculated that a similar situation occurred in this implant case. Cement excess was acting like "artificial calculus," which predisposed peri-implant disease. This case report could suggest that surgical intervention is not always

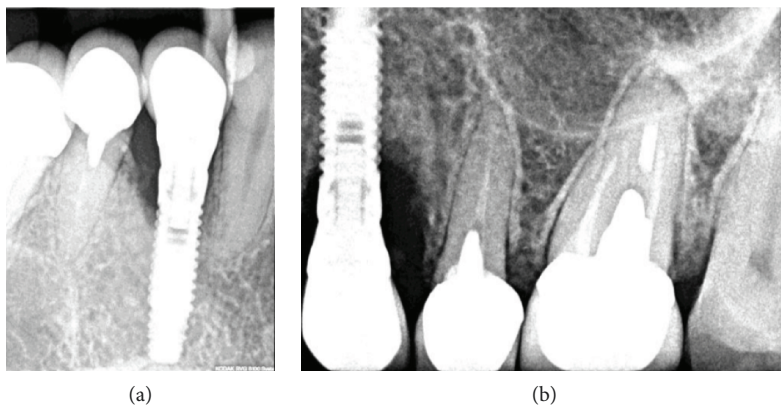


FIGURE 3: (a, b) Radiographic examination with different positions of the holder.

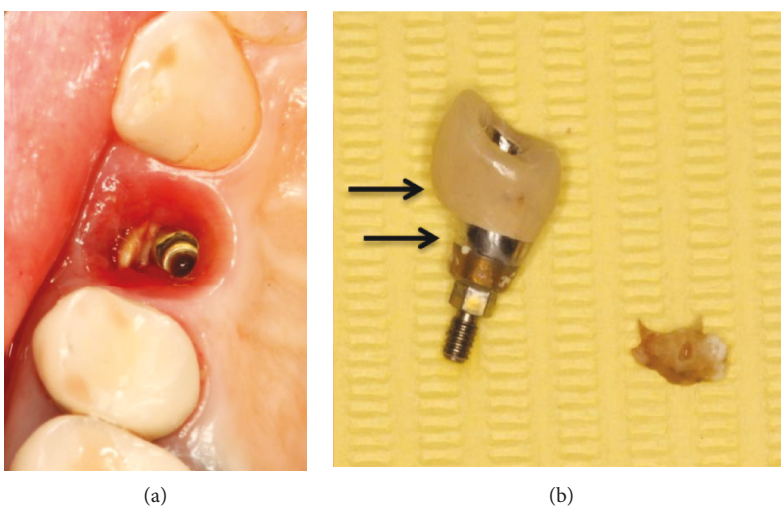


FIGURE 4: (a) Undetected cement remnants in peri-implant sulcus; (b) removed cement excess and size of undercut of the restoration.

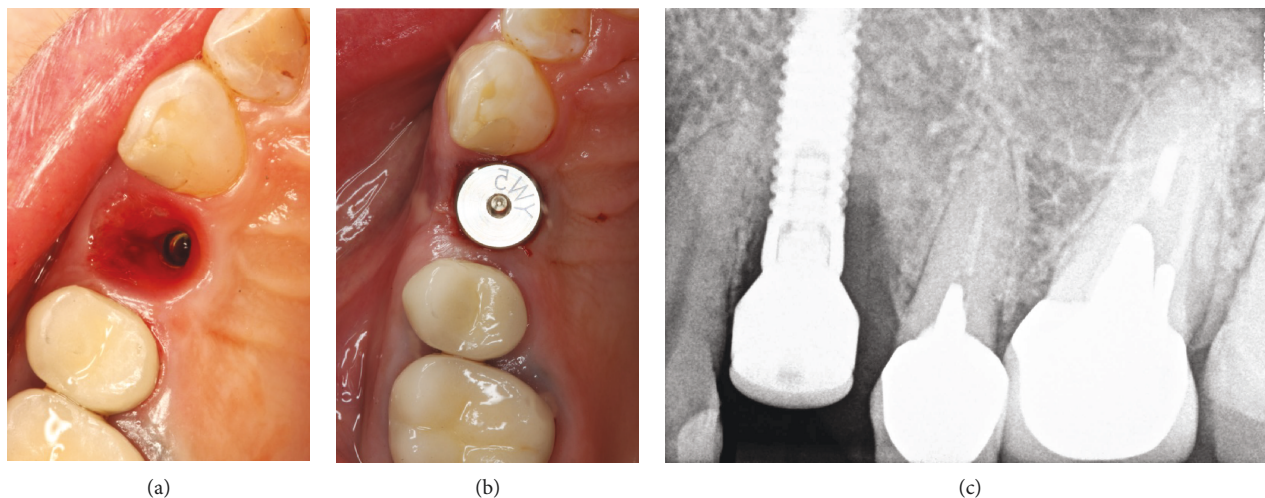


FIGURE 5: (a) Peri-implant sulcus after removal of cement excess, (b) healing abutment connection, and (c) radiographic verification.

necessary as a part of cement-related peri-implantitis treatment. When cement rest is removed and the patient is not periodontally compromised, remineralization of the crestal bone can occur.

The bone loss around a dental implant due to cement remnants is not direct bone loss but rather demineralization. The question arises: how long should it take to destroy all organic matrix and when to predict bone remineralization



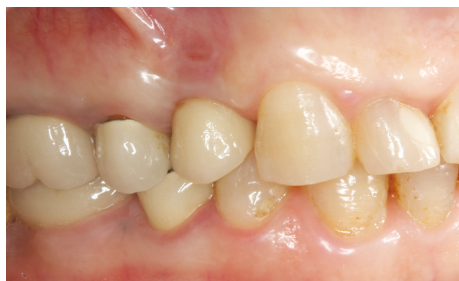

FIGURE 6: Sinus tract has healed.

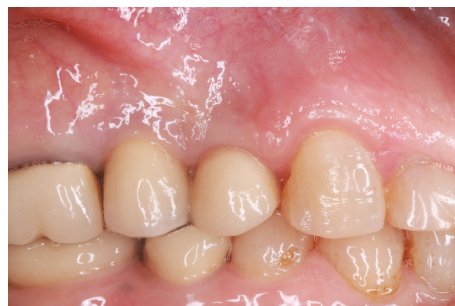

FIGURE 8: Clinical appearance of implant-supported restoration 10 years after treatment.

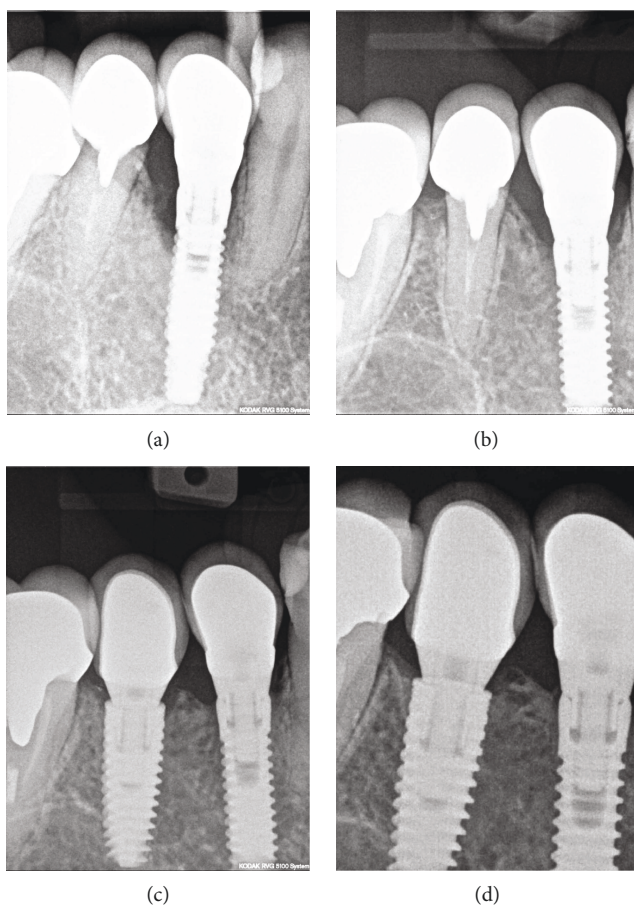


FIGURE 7: (a) Reference radiograph in 2009; (b) partial remineralization of the bone defect in 2010; (c) full reestablishment of the bone level in 2012; (d) stable bone after 10 years.

around dental implant? Perhaps, there is strong probability for a direct correlation between host response and microbiota of peri-implant sulcus.

The lack of information about bone demineralization and remineralization kinetics is also observed. It can only be speculated as a process similar to periodontal tissue changes.

Demineralization is the process caused by inflammation when mineral ions of hydroxyapatite (HA) are removed from the hard tissues, particularly in the bone [9]. Even though HA is one of the most stable calcium phosphate salts [10], the

inflammation process might lead to the bone matrix changes following bone loss. Inflammation is related to the overproduction of various cytokines and bone cells [11]. It initiates hyperactivation of osteoclasts and leads to the bone degradation; also, some cytokines negatively affect osteoblast function [12]. Remineralization might be achieved by increasing osteoblast function; particularly, these cells promote crystal formation of hydroxyapatite, propagate growth in the interior part of membrane-limited matrix vesicles [13], and induce crystals in the collagenous extracellular matrix thus mineralizing bone matrix overall [14].

Recent publications regarding peri-implantitis treatment have various treatment methods in order to obtain bone remineralization, but most of them contain surgical interventions [15–19]. A study performed by Froum et al. proposed a regenerative approach for peri-implantitis treatment [16] with a consecutive series of 170 implants in 100 patients up to a 10-year follow-up. The treatment consisted of flap elevation, surface decontamination, use of enamel matrix derivative (EMD) or platelet-derived growth factor (PDGF), and guided bone regeneration with mineralized freeze-dried bone and/or organic bovine bone (with PDGF or EMD) and covered with an absorbable membrane or subepithelial connective tissue graft. In the results, it was stated that probing depth reduction averaged 5,1 mm and bone level gain averaged 1,77 mm.

While taking a look in scientific articles reporting non-surgical treatment for peri-implantitis, the mean differences were evaluated between either presence or absence of bleeding and changes in probing depth. From the existing literature on nonsurgical therapy of peri-implantitis, it seems that limited clinical improvements have been found following mechanical therapy with ultrasonic devices or carbon-fiber curettes. In the controlled study by Karring et al. [20], peri-implantitis treatment was performed with either carbon-fiber tip with aerosol spray with hydroxylapatite or carbon-fiber curette. None of these methods in the randomized split-mouth study resulted in healing of the peri-implantitis lesions. In a randomized controlled trial comparing the use of either titanium curettes or ultrasonic device for implants, a significant reduction in bleeding and plaque scores was noted after six months, but probing depths were not improved [21]. In the clinical study performed by Sahm et al., it was noted that air-abrasive treatment

resulted in significantly higher bleeding on probing reduction compared with mechanical debridement with carbon-fiber curette [22]. In the Büchter and coworker study, it is already stated that local antimicrobial treatment gives positive results in reduction of pocket probing depth of about 1,15 mm [23]. A number of case series and clinical trials have reported similar results in terms of enhancing effectiveness of peri-implantitis treatment supplemented with local antimicrobials [24–27]. The question arises: does conservative treatment of peri-implantitis lead not only to absence of inflammation and reduction of probing depth but also to remineralization around the implant site?.

The main limitation to any human clinical study is the lack of histology needed to determine the newly formed bone of the remineralization process. There is still considerable uncertainty with regard to effectiveness of the proposed treatment; in fact, further experimental investigations are needed to estimate the accurate results.

### Additional Points

*A Key Clinical Message.* Bone remineralization around dental implants with a history of peri-implantitis is possible after irritant factors are removed and conservative treatment is performed.

### Conflicts of Interest

The authors declare that they have no conflicts of interest.

### References

- [1] T. G. Wilson Jr., “The positive relationship between excess cement and peri-implant disease: a prospective clinical endoscopic study,” *Journal of Periodontology*, vol. 80, no. 9, pp. 1388–1392, 2009.
- [2] T. Linkevicius, A. Puisys, E. Vindasiute, L. Linkeviciene, and P. Apse, “Does residual cement around implant-supported restorations cause peri-implant disease? A retrospective case analysis,” *Clinical Oral Implants Research*, vol. 24, no. 11, pp. 1179–1184, 2013.
- [3] J. R. Agar, S. M. Cameron, J. C. Hughbanks, and M. H. Parker, “Cement removal from restorations luted to titanium abutments with simulated subgingival margins,” *The Journal of Prosthetic Dentistry*, vol. 78, no. 1, pp. 43–47, 1997.
- [4] T. Linkevicius, E. Vindasiute, A. Puisys, and V. Peciuliene, “The influence of margin location on the amount of undetected cement excess after delivery of cement-retained implant restorations,” *Clinical Oral Implants Research*, vol. 22, no. 12, pp. 1379–1384, 2011.
- [5] T. Linkevicius, E. Vindasiute, A. Puisys, L. Linkeviciene, N. Maslova, and A. Puriene, “The influence of the cementation margin position on the amount of undetected cement. A prospective clinical study,” *Clinical Oral Implants Research*, vol. 24, no. 1, pp. 71–76, 2013.
- [6] G. Wasiluk, E. Chomik, P. Gehrke, M. Pietruska, A. Skurska, and J. Pietruski, “Incidence of undetected cement on CAD/CAM monolithic zirconia crowns and customized CAD/CAM implant abutments. A prospective case series,” *Clinical Oral Implants Research*, vol. 28, no. 7, pp. 774–778, 2017.
- [7] S. Kappel, C. Eiffler, J. Lorenzo-Bermejo, T. Stober, and P. Rammelsberg, “Undetected residual cement on standard or individualized all-ceramic abutments with cemented zirconia single crowns - a prospective randomized pilot trial,” *Clinical Oral Implants Research*, vol. 27, no. 9, pp. 1065–1071, 2016.
- [8] B. Rosling, S. Nyman, and J. Lindhe, “The effect of systematic plaque control on bone regeneration in infrabony pockets,” *Journal of Clinical Periodontology*, vol. 3, no. 1, pp. 38–53, 1976.
- [9] E. A. Neel, A. Aljabo, A. Strange et al., “Demineralization–remineralization dynamics in teeth and bone,” *International Journal of Nanomedicine*, vol. Volume 11, pp. 4743–4763, 2016.
- [10] E. E. Machtei, Y. Mayer, J. Horwitz, and H. Zigdon-Giladi, “Prospective randomized controlled clinical trial to compare hard tissue changes following socket preservation using alloplasts, xenografts vs no grafting: clinical and histological findings,” *Clinical Implant Dentistry and Related Research*, vol. 21, no. 1, pp. 14–20, 2019.
- [11] A. Kantarci, L. Will, and S. Yen, Eds., *Tooth Movement. Frontiers of Oral Biology, Vol 18*, Karger, Basel, 2016.
- [12] A. Insua, A. Monje, H.-L. Wang, and R. J. Miron, “Basis of bone metabolism around dental implants during osseointegration and peri-implant bone loss,” *Journal of Biomedical Materials Research Part A*, vol. 105, no. 7, pp. 2075–2089, 2017.
- [13] T. Hasegawa, “Ultrastructure and biological function of matrix vesicles in bone mineralization,” *Histochemistry and Cell Biology*, vol. 149, no. 4, pp. 289–304, 2018.
- [14] L. Hesse, K. A. Johnson, H. C. Anderson et al., “Tissue-nonspecific alkaline phosphatase and plasma cell membrane glycoprotein-1 are central antagonistic regulators of bone mineralization,” *Proceedings of the National Academy of Sciences*, vol. 99, no. 14, pp. 9445–9449, 2002.
- [15] A. C. Wetzel, J. Vlassis, R. G. Caffesse, C. H. F. Hammerle, and N. P. Lang, “Attempts to obtain re-osseointegration following experimental peri-implantitis in dogs,” *Clinical Oral Implants Research*, vol. 10, no. 2, pp. 111–119, 1999.
- [16] S. Froum, S. Froum, and P. Rosen, “A regenerative approach to the successful treatment of peri-implantitis: a consecutive series of 170 implants in 100 patients with 2- to 10-year follow-up,” *The International Journal of Periodontics & Restorative Dentistry*, vol. 35, no. 6, pp. 857–863, 2015.
- [17] S. Froum and P. Rosen, “Reentry evaluation following treatment of peri-implantitis with a regenerative approach,” *The International Journal of Periodontics & Restorative Dentistry*, vol. 34, no. 1, pp. 47–59, 2014.
- [18] S. Renvert and I. N. Polyzois, “Clinical approaches to treat peri-implant mucositis and peri-implantitis,” *Periodontology 2000*, vol. 68, no. 1, pp. 369–404, 2015.
- [19] S.-Y. Park, K.-H. Kim, S.-H. Rhee et al., “An immediate peri-implantitis induction model to study regenerative peri-implantitis treatments,” *Clinical Oral Implants Research*, vol. 28, no. 1, pp. 36–42, 2017.
- [20] E. S. Karring, A. Stavropoulos, B. Ellegaard, and T. Karring, “Treatment of peri-implantitis by the VectorR system. A pilot study,” *Clinical Oral Implants Research*, vol. 16, no. 3, pp. 288–293, 2005.
- [21] S. Renvert, E. Samuelsson, C. Lindahl, and G. R. Persson, “Mechanical non-surgical treatment of peri-implantitis: a

- double-blind randomized longitudinal clinical study. I: clinical results," *Journal of Clinical Periodontology*, vol. 36, no. 7, pp. 604–609, 2009.
- [22] N. Sahn, J. Becker, T. Santel, and F. Schwarz, "Non-surgical treatment of peri-implantitis using an air-abrasive device or mechanical debridement and local application of chlorhexidine: a prospective, randomized, controlled clinical study," *Journal of Clinical Periodontology*, vol. 38, no. 9, pp. 872–878, 2011.
- [23] A. Büchter, U. Meyer, B. Kruse-Lösler, U. Joos, and J. Kleinheinz, "Sustained release of doxycycline for the treatment of peri-implantitis: randomised controlled trial," *British Journal of Oral and Maxillofacial Surgery*, vol. 42, no. 5, pp. 439–444, 2004.
- [24] M. de Araujo Nobre, C. Capelas, A. Alves et al., "Non-surgical treatment of peri-implant pathology," *International Journal of Dental Hygiene*, vol. 4, no. 2, pp. 84–90, 2006.
- [25] E. E. Machtei, S. Frankenthal, G. Levi et al., "Treatment of peri-implantitis using multiple applications of chlorhexidine chips: a double-blind, randomized multi-centre clinical trial," *Journal of Clinical Periodontology*, vol. 39, no. 12, pp. 1198–1205, 2012.
- [26] G. R. Persson, G. E. Salvi, L. J. A. Heitz-Mayfield, and N. P. Lang, "Antimicrobial therapy using a local drug delivery system (ArestinR) in the treatment of peri-implantitis. I: microbiological outcomes," *Clinical Oral Implants Research*, vol. 17, no. 4, pp. 386–393, 2006.
- [27] G. E. Salvi, G. R. Persson, L. J. A. Heitz-Mayfield, M. Frei, and N. P. Lang, "Adjunctive local antibiotic therapy in the treatment of peri-implantitis II: clinical and radiographic outcomes," *Clinical Oral Implants Research*, vol. 18, no. 3, pp. 281–285, 2007.





**Hindawi**

Submit your manuscripts at  
[www.hindawi.com](http://www.hindawi.com)

