

# Incarcerated obturator hernia in 49 year old women: a case report and review of the literature

## Įstrigusios obturatorinė išvarža 49-erių metų moteriai: atvejo aprašymas ir literatūros apžvalga

Marius Markevičius, Raimundas Lunevičius, Vitalijus Markovas, Juozas Stanaitis

*Vilnius University, Center of General Surgery, Vilnius University Emergency Hospital, Šiltnamių str. 29, LT-04139 Vilnius, Lithuania*

*E-mail: marijuss@gmail.com*

---

### Introduction

Incarcerated obturator hernia is a rare cause of bowel obstruction. This case report aimed to review the diagnosis and management of obturator hernia by describing the anatomy, clinical presentation, diagnostic modalities, and predisposing factors.

### Case presentation

A 49-year-old woman presented to emergency department with progressive spastic abdominal pain, vomiting, abdomen enlargement, and tenesmus. One month before this episode she was diagnosed a carcinoma of the cervix uteri which was defined as T1b N1 M0 G2. She has undergone a curative R0 type surgery and adjuvant chemoradiation. There were no pelvic abnormalities described in the operative protocol. She lost 20 kg in two years. Because of ineffective conservative treatment, progression of acute bowel obstruction and signs of local peritonitis, she underwent an urgent curative laparotomy. It was confirmed that a loop of ileum was incarcerated and irreducible in the canal of right side of pelvis that suited to obturatoric foramen.

### Conclusions

Rarity of such a condition makes great difficulties in diagnosing it. CT is needed to recognize obturator hernia in early stages before its incarceration. Significant lost weight (> 20 kg), and adjuvant chemoradiotherapy were most possible predisposing risk factors for right obturator hernia in 49 years old female.

**Key words:** obturator hernia, strangulated hernia, risk factors, laparoscopy, laparotomy.

---

### Introduction

The obturator hernia is classified as a very rare type of abdominal hernia [1–3]. It was first time reported by Arnaud de Ronsil in 1724 and successfully repaired by

Henry Obre in 1851 [4]. It accounts for 0.07–1% of all hernias and 0.2–1.6 % of all small bowel obstructions [2, 5].

There are a plenty of risk factors described for obturator hernia: age greater than 70, emaciation, conditions

with increased intra-abdominal pressure, multiparity. However, due to rareness of this type hernia we think that it is important to report the symptomatic obturator hernia cases emphasizing possible risk factors either new or known. This case report aimed to review the diagnosis and management of obturator hernia by describing the anatomy, clinical presentation, diagnostic modalities, and predisposing factors.

### Case report

A 49-year-old woman presented to emergency department (ED) with progressive spastic abdominal pain, nausea, vomiting, abdomen enlargement, fullness in intestines, and tenesmus. Her medical history indicated that two years ago she felt very similar visceral pain which spontaneously resolved. One month before this episode she was diagnosed a carcinoma of the cervix uteri which was defined as T1b N1 M0 G2. She has undergone a curative R0 type surgery without lateral lymph node dissection. Adjuvant chemoradiation was employed too. It is important to note that there were no pelvic abnormalities described in the operative protocol. She lost 20 kg in two years.

Physical examination revealed that her BMI was within normal limits. There was no fever. Her pulse rate was 84 bpm and her blood pressure was 140/90 mm Hg. An abdomen was soft but painful to palpation in left lower quadrant. There were no signs of peritonitis and visceral hernia. Howship-Romberg sign was not present. A laboratory evaluation revealed leucocytosis (10,100) and hemoconcentration (HGB – 167 g/L and HCT – 0,52). There were no deviations in blood biochemistry and coagulation. Initial plain abdominal X-rays showed mild signs of bowel obstruction. The patient was treated conservatively with intravenous fluid intake, enemas, antiemetic drugs, analgetics, and gastric decompression by nasogastric tube. Follow up plain abdominal X-ray done 8 hours from the admission of the patient confirmed progression of bowel obstruction. She underwent an urgent laparotomy.

It was found that a loop of ileum was incarcerated and irreducible in the canal of right side of pelvis that suited to obturatoric foramen (Figure). It was the cause of acute small bowel obstruction. When loop was released from obturatoric foramen, a foramen was closed by

interrupted U form vicril suture. There were no signs of cancer in peritoneal cavity. A postoperative period was uneventful. The patient was discharged in fifth postoperative day. She came back for examination two months later. There were no any complaints.

### Review

The obturator foramen is the largest foramen in the body being formed by the rami of ischium and pubis [1–3]. The obturator membrane covers the obturator foramen except antero-superior part of the foramen where the obturator canal is located. The obturator canal is 2–3 cm long and 1 cm wide. The obturator nerve and associated blood vessels are located in this canal and are surrounded by fatty tissue [2, 3, 6].

There are three anatomical stages of the formation of obturator hernia [2, 7, 8]. First, entrance of preperitoneal tissue into the pelvic orifice of the obturator canal. Second, development of a dimple in the peritoneum overlying the canal. Third, onset of symptoms produced by entrance of an organ into the canal. Even though the first stage is a pre-hernial condition it is unlikely that fat plugs are high risks. But development of peritoneal dimples may be a marker of potential hernia formation [7]. The hernial sac in most instances contains small intestine, usually ileum [3], but can also include large bowel omentum, fallopian tube, appen-

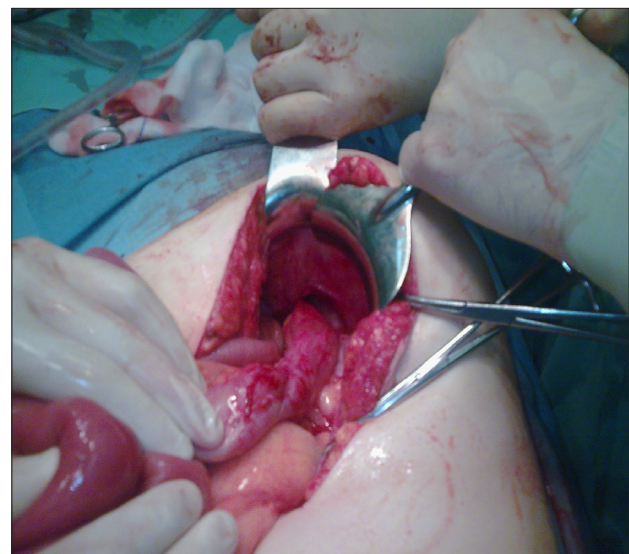


Fig. Incarceration of small bowel in right obturatoric canal

dix, urinary bladder, and uterus [7–10]. Rarely, it was reported that ovary or Meckel's diverticulum can also be incarcerated [8].

Incidence of obturator hernia is 6–9 times higher in females due to their wider pelvis, more triangular obturator canal opening and greater transverse diameter [2, 4–6, 9, 11, 12]. It occurs most frequently in emaciated patients aged between 70 and 90 years, and hence its nickname is “little old lady's hernia”. The loss of protective preperitoneal fat and lymphatic tissue around the obturator vessels and nerves facilitates the formation of hernia [2, 12]. Multiparity is also considered to be as predisposing factors of obturator hernia [4, 13]. It is uncertain if concomitant conditions that lead to constant and increased intraabdominal pressure such as chronic constipation, ascites, chronic obstructive pulmonary disease, pregnancy, or kyphoscoliosis are risk factors for obturator hernia [4–6, 8].

The right side is more commonly involved with ratio of 3 : 1 [3, 4, 11] because of sigmoid colon tends to prevent it on left [5]. About 6 % of cases are bilateral and some may be associated with other types of hernia such as indirect inguinal hernia, the direct inguinal hernia, or the femoral hernia [7, 8, 12]. Some authors describe up to 15 % of bilateral obturator hernia [10]. Clinical diagnosis is often difficult because the condition is uncommon, the location is deep within the pelvis, and there are non-specific signs. Strangulated obturator hernias are diagnosed preoperatively in only 10–40 % of cases [6, 7, 14]. The most common presentation (90 %) of obturator hernia is mechanical small bowel obstruction caused by incarceration of the bowel into the obturator canal. One third of the patients have a history of intermittent previous attacks of small bowel obstruction [4, 5]. Mechanical intestinal obstruction is characterized by cramping midabdominal pain which tends to be more severe the higher the obstruction. The pain occurs in paroxysms, and the patient is relatively comfortable in the intervals between the pains. Symptoms of bowel obstruction, including dull, cramping abdominal pain, nausea, and vomiting are reported in more than 80 % of patients with obturator hernia. The symptoms may be acute or intermittent if the hernia content reduces into the peritoneal cavity spontaneously. In some cases the initial symptoms are mild nausea, vomiting and anore-

xia, probably due to incomplete herniation or Richter's type incarceration [8].

The hernial sac causes pressure on the obturator nerve resulting in pain radiating down the medial aspect the thigh to the knee and, less often, the hip (Howship–Romberg sign). This pain may be provoked or worsened by coughing or by extension, abduction or internal rotation of the hip. Flexion of the thigh usually relieves the pain. The Howship–Romberg sign is pathognomic of obturator hernia and is present only in 12.5 %–65 % cases [2, 4–8, 13, 15–18]. The pain is often overlooked and sometimes falsely attributed to osteoporosis, arthritis or trauma, especially in the geriatric population [6]. One more diagnostic sign was described in 1980. Hannington–Kiff sign is loss of the adductor reflex of the thigh in the presence of the positive patellar reflex. It is said to be more specific but less known than Howship–Romberg sign [2–5, 8, 12]. None of them was present in our described patient. Other clinical sign is peritonitis. When we have such a case a laparotomy should not be delayed for diagnostic testing [4]. Hernial mass can be palpated through rectum or vaginal approach. Palpation of a tender and painful mass in the obturator region is of great value in obtaining the correct diagnosis, and suggests incarceration or strangulation of the hernia [3, 8].

Several imaging modalities have been described to diagnose obturator hernia including plain radiographs of abdomen, herniography, ultrasonography, barium enema, MRT [7, 8]; the most relevant is CT, and laparoscopy as a gold standard in diagnosing obturator hernia [8]. Plain radiography provides no specific findings apart from a dilated bowel loop, and can not reveal any significant information as to the cause of intestinal obstruction. It is almost unuseful in diagnosing obturator hernia. Herniography can directly demonstrate the hernial sac, but has no place in the emergency diagnosis of obturator hernia and is used only in elective cases [8]. Barium enema may show an opacified bowel loop which may or may not be reducible. This may not be an easy and rewarding procedure to do in cases of intestinal obstruction, as the flow of barium is likely to be slow due to the obstruction, hence prolonging the examination [7].

Ultrasonography (US) of the inguinal region and inner aspect of the thigh for the diagnosis of hernia was

first reported in 1975 [7]. It has been noted as a reliable examination, with the commonest appearance being a hypoechoic tubular structure representing the hernial sac. If there are oedematous and fluid-filled segments of intestine within the hernial sac, these are seen as an echogenic mass. The major advantages of US are that it is non-invasive, allows for comparison with the asymptomatic side, and is able to be performed in physiological positions with dynamic scanning. Operator dependency and the relatively long learning curve are limiting factors. Too much pressure on the transducer can also reduce the sensitivity of detection of hernias. Direct and indirect inguinal hernias can be distinguished by the position of the hernia relative to the inferior epigastric vessels which can be identified on US. However obturator hernias are not as easily identified due to their deep location within the pelvic musculature and smaller hernial sac [7].

Magnetic resonance imaging when first reported in the evaluation of hernias utilised standard nondynamic sequences which limited its usefulness [7]. In 1983, computed axial tomography (CAT) of the pelvis was used to diagnose obturator hernia. Subsequently, increasing evidence indicates that CT scanning has superior sensitivity and accuracy in the preoperative diagnosis of obturator hernia. Some authors propose that emergency CT scanning could lead to rapid diagnosis and early surgical intervention particularly in elderly patients presenting with ileus of unknown origin [18]. CT is able to accurately diagnose obturator hernias which can be hard to diagnose clinically. With CT, the contents of the hernia can easily be identified. The hernial sac and its contents can lie between the pectineus and obturator externus muscles, or the superior and middle fascicles of obturator externus muscles, or the obturator internus and externus muscles. Some of the advantages of CT include: more accurate identification of abdominal wall hernias and their contents, differentiation of hernias from other abdominal masses (tumors, haematomas, abscesses, undescended testes and aneurysms), and detection of complications (incarceration, bowel obstruction, volvulus and strangulation). Spiral CT, and now multi-slice CT (MSCT), with its thinner slice sections and multiplanar capabilities can precisely delineate hernia type, location, size, and shape. In addition,

because of its superior anatomical detail, MSCT may potentially detect subtle signs of strangulation, such as mesenteric stranding, poor bowel wall enhancement, wall thickening, free air, or fluid in the hernial sac. Postural manoeuvres, such as prone or decubitus positioning, and scanning while the patient performs the Valsalva manoeuvre may help depict subtle hernias as well [7, 16]. Diagnostic laparoscopy is more specific than any types of imaging as it gives concrete diagnosis and helps to decide subsequent management [18]. There is a general agreement that obturator hernia must be treated surgically. A variety of operative approaches to obturator hernias have been described including retropubic approach, obturator approach, inguinal extraperitoneal approach, transperitoneal approach through midline incision and combined approach with either a laparotomy or laparoscopy. However, because of the rarity of this condition, there is no consensus on the most proper approach. In patients with an established preoperative diagnosis, an extraperitoneal approach is the best surgical procedure. However, a transperitoneal approach will be necessary in those patients with intestinal obstruction of uncertain cause [8].

The abdominal approach via a low midline incision is most commonly favoured, as the advantages of this approach include establishing a diagnosis, avoidance of obturator vessels, better exposure of the obturator ring, and facilitation of bowel resection, if necessary [2]. Many authors prefer a simple closure of the hernial defect with one or more interrupted sutures as it leads to an acceptable recurrence rate of less than 10 %. The defect can be closed by synthetic mesh, although a myriad of things have been used in the past, such as costal cartilage, innermost fibres of pectineus muscle, rolled-up tantalum gauze, osteoperiosteal flap from the pubic bone, free omentum and uterine fundus or round ligament [2–4].

The laparoscopic approach is an alternative to diagnose, reduce and repair an obturator hernia in selected cases. Both transabdominal and extraperitoneal approaches have been described. This approach is minimally invasive and provides some benefits for high-risk patients like less postoperative pain, less ileus, fewer pulmonary complications, and a shorter hospital stay. Whatever the approach, the emphasis should be on rapid evaluation, adequate resuscitation, and early operative intervention,

to reduce the morbidity and mortality [2, 18]. Bowel obstruction was once considered a relative contraindication for laparoscopic surgery because of the risk of bowel perforation during port insertion and handling of friable, distended gut. It is important to note that if we want to be sure and not to feel additional difficulties during laparoscopic approach, we need to operate in an early stage when the abdomen is not grossly distended, giving adequate working space [18].

Bowel resection is required in 25–75 % of cases, as most of them were diagnosed too late [4, 10]. The mortality rate has been reported to be between 12 and 70 % [4, 10]. Unfavorable outcomes are commonly associated with delay in diagnosis and surgical intervention, poor general condition, elderly patients having

coexistent diseases, and a high rate of bowel gangrene [4, 10].

## Conclusions

Rarity of such a condition makes great difficulties in diagnosing it. CT is needed to recognize obturator hernia in early stages before its incarceration. An urgent diagnostic laparotomy is necessary in case of severe progression of acute bowel obstruction. Clinical case described might be regarded as interesting one due to right obturator hernia link with the significant lost weight (> 20 kg), and adjuvant chemoradiotherapy. They are most possible predisposing risk factors for obturator hernia in 49 years old female.

## REFERENCES

1. Townsend CM, Evers BM, Mattox KL. Sabiston Textbook of surgery 18<sup>th</sup> edition. 2008; 1156–1157, 1180–1181.
2. Mantoo SK, Mak K, Tan TJ. Obturator hernia: diagnosis and treatment in the modern era. Singapore Med J 2009; 50 (9): 866–70.
3. Skandalakis LJ, Androulakis J, Colborn GL, Skandalakis JE. Obturator hernia. Embryology, anatomy, and surgical applications. Surg Clin North Am 2000; 80: 71–84.
4. Green BT. Strangulated obturator hernia: still deadly. South Med J 2001; 94 (1): 81–83.
5. Nakayama T, Kobayashi S, Shiraishi K, Nishiumi T, Mori S, Isobe K, Furuta Y. Diagnosis and treatment of obturator hernia. Keio J Med 2002; 51 (3): 129–32.
6. Guillem P, Bounoua F, Duval G. A case of hip pain in an elderly woman. The Brit J of Radiology 2000; 73: 1233–1234.
7. Dundamadappa SK, Tsou IYY, Goh JSK. Clinics in diagnostic imaging. Singapore Med J 2006; 47 (1): 89–94.
8. Zhang H, Cong J, Chen C. Ileum perforation due to delayed operation in obturator hernia: a case report and review of literatures. WJG 2010; 16: 126130.
9. Zausner J, Dupont AE, Ring SM. Obturator hernia. New York; 1972: 408–409.
10. Sun HP, Chao YP. Preoperative diagnosis and successful laparoscopic treatment of incarcerated obturator hernia. Hernia 2010; 14 (2): 203–206.
11. Haraguchi M, Matsuo S, Kanetaka K, Tokai H, Azuma T, Yamaguchi S, Kanematsu T. Obturator hernia in ageing society. Ann Acad Med Singapore 2007; 36 (6): 413–415.
12. Jacob TJ, Gaikwad P, Tirkey AJ. Perforated obturator Littre hernia. Can J Surg 2009; 52 (3): 77–78.
13. Schmidt PH, Bull WJ, Jeffery KM, Martindale RG. Typical versus atypical presentation of obturator hernia. Am Surg. 2001; 67 (2): 191–195.
14. Gilliam A, O'Boyle CJ, Wai D, Perry EP. Ultrasonic diagnosis of strangulated obturator hernia. Euro J Surg 2000; 166 (5): 420–421
15. Paulson EK, Keogan MY, Folz EK. Gastrointestinal case of the day. AJR 1995; 165: 192–193.
16. Wang G, Qian H, Cai X. Strangulated obturator hernia diagnosed preoperatively by spiral CT: case report. Chin Med J 2007; 120 (20): 1855–1856.
17. Avaro JP, Biance N, Savoie PH. Incarcerated obturator hernia: early diagnostic using helical computed tomography. Hernia 2008; 12: 199–200.
18. Chan ES, Tang C, Ha JP. Laparoscopic repair of obturator hernia. Surg pract 2006; 10: 167–170.