

Congenital methemoglobinemia: Rare presentation of cyanosis in newborns

Ernestas Viršilas, Lina Timukienė, Arūnas Liubšys

Faculty of Medicine, Institute of Clinical Medicine, Vilnius University, Vilnius, Lithuania

Abstract

Methemoglobin (MetHb) is an oxidized form on hemoglobin, which is unable to bind oxygen and consequently carry it to the tissues. Normally present in small quantities (<1%) without detrimental effects, its elevation produces hypoxemia which can be profound and even lethal. Methemoglobinemia is an abnormal increase of MetHb (>3%) of total hemoglobin. It can be classified in two types: hereditary and acquired. Acquired form is caused by exogenous oxidizing agents, such as nitrites or certain medications, while hereditary types of disease are the result of genetic deficiency in cytochrome B₅ reductase, an enzyme responsible for MetHb reduction to hemoglobin. Little data is available on the epidemiology of methemoglobinemia. In general population only sporadic cases are described, while some isolated ethnic populations have increased incidence, possibly inherited from a common ancestor. We present a case of congenital methemoglobinemia in which detection of MetHb was hampered by faulty initial blood gas spectrometry results. A short literature review is also included.

Case Report

A 2-day-old male infant presented with central and peripheral cyanosis. No others signs of respiratory distress or hypoxia were observed and pulseoxymetry test showed a saturation of 86-90% at room air.

Infant was born through spontaneous vaginal delivery to 28-year-old woman (gravida 2 para 2, GA 40 wk), who received routine prenatal care and screening. Apgar scores at birth were 10/10 at 1 and 5 minutes, respectively. According to mother, infant was feeding regularly and she did not notice any abnormalities in his behavior. Her firstborn child is healthy and asymptomatic.

Complete blood count revealed hematocrit (Hct) of 0.85% (reference range 0.45-

0.72) and hemoglobin of 289 g/L (reference range 145-220).¹ C reactive protein, procalcitonin, blood gases (capillary) were within normal ranges, no abnormalities were found on chest x-ray, neurosonography and echocardiography. Methemoglobin (MetHb) level was normal 2.6% (<3%).

Non-invasive respiratory support with continuous positive airway pressure and supplemental oxygen was started but had no effect on saturation or cyanosis. After blood work and diagnostic testing, intravenous glucose was started as treatment for polycythemia. Cyanosis and low saturation remained even with improvement of Hct after intravenous glucose infusion. Methemoglobinemia was not considered due to low apparent MetHb concentration (ABL90 FLEX analyzer). Lack of inflammatory markers and narrow nature of clinical presentation made early onset of infection unlikely. Neither clinical presentation, respiratory support or oxygen supply, nor changes on chest x-ray confirmed respiratory distress syndrome. Mothers' blue fingers and lips were noticed by clinician (Figure 1). Additional questioning revealed that some of 2nd, 3rd, 4th degree relatives possess persistent blueish discoloration of the lips and fingertips. There were no consanguineous marriages in family's history and both parents were of European descent. Neither mother, nor relatives have complaints or associated symptoms with aforementioned discoloration.

As there was high suspicion (atypical phenotype in mother and relatives) of possible hereditary methemoglobinemia, additional tests were performed. Control analyte test was performed with blood being drawn from the patient, patient's mother and two healthy control samples for MetHb content analysis and sent to central laboratory for analysis. Color difference in patients' and his mothers' blood samples was also distinctively noticeable compared to healthy controls (Figure 2). Results from central laboratory (using ABL800 BASIC analyzer) revealed increased MetHb in the mother (14.8%) as well as the infant (4.0%) confirming congenital methemoglobinemia (Table 1). Previous treatments were suspended, no specific treatment for methemoglobinemia was applied due to low concentration of MetHb. Patient was discharged in a stable condition with mild, barely noticeable cyanosis only while crying. Hemoglobin electrophoresis obtained later was unremarkable. Cytochrome B₅ reductase (CYB₅R) activity level, sequence analysis of the β and γ globin genes were not obtained, due to limited availability in the region. No developmental delay or growth retardation was observed (head cir-

Correspondence: Ernestas Viršilas, Faculty of Medicine, Institute of Clinical Medicine, Vilnius University, Vilnius, Lithuania. Tel.: +370.6078.7438. E-mail: ernestas.virsilas@santa.lt

Key words: Neonatal; Cyanosis; Hemoglobinopathies; Congenital hereditary methemoglobinemia.

Contributions: EV and LT drafted the article; AL critically revised the article for important intellectual content; EV, LT and AL were involved in the final approval of the article.

Conflict of interest: the authors declare no potential conflict of interest.

Funding: none.

Ethical statement: the informed consent was obtained from the patient.

Received for publication: 5 August 2019.

Revision received: 22 October 2019.

Accepted for publication: 23 October 2019.

This work is licensed under a Creative Commons Attribution NonCommercial 4.0 License (CC BY-NC 4.0).

cumference between 25-50 centile, weight and height between 50-75 centiles) at 6 months of age.

Discussion

Congenital methemoglobinemia is a very rare cause of childhood cyanosis. Pathogenesis is best described by the increased and sustained concentration of oxidized hemes. This results in inability of hemoglobin to bind and carry oxygen shifting oxygen dissociation curve to the left, thus compromising oxygen supply to the tissues. Under normal conditions MetHb levels are kept under 1%.² Methemoglobinemia can be acquired (caused by various oxidizing agents) or genetic (caused by deficiency of CYB₅R or cytochrome B₅ systems). Acquired is usually attained by nitrite ingestion or exposure to certain medications (anesthetics being most frequent).² Symptoms of methemoglobinemia are associated with hypoxemia (produced by inefficient gas exchange) which directly correlates with MetHb plasma levels³ (Table 2).

Congenital methemoglobinemia is categorized into two forms: type I (more common) and type II (rare and severe). Type I is characterized by CYB₅R functional deficiency in red blood cells. This type of disor-

der results in MetHb concentrations up to 40%,² although most patients adapt to increased MetHb levels by compensatory polycythemia and have little to no symptoms unless exposed to oxidizing agents.⁴ This form is distributed worldwide, although endemic zones exist.⁵ Type II is CYB₅R deficiency in all cells. Life expectancy is short – most die in infancy, compared to normal life expectancy in type I. In addition to the usual symptoms caused by increased MetHb in the blood, affected infants exhibit mental retardation and developmental delay at an early age with full phenotype manifestation at 4-9 months of life.^{6,7}

Diagnosis

Blood gas analysis is simple, precise and most readily available diagnostic test. During analysis, RBCs are hemolyzed and exposed to polychromatic light toward the spectrometer where different fractions of hemoglobin absorb distinct wavelengths. The corresponding fractions of wavelengths are converted to numerical values representing various hemoglobin concentrations.⁸ P50 oxygen dissociation curve analysis is provided by most blood gas analyzers. Although very useful measurement in critically ill, P50 is unsuitable for neonates as a result of reference range absence.⁹

Noninvasive pulse co-oximetry is another reliable tool for diagnosing dismethemoglobinemias with the advantage rapid and painless determination of hemoglobin fractions, although this determination is less precise compared to blood gas analysis.¹⁰

Several bedside tests were created in attempt to provide means of diagnosis when neither of abovementioned tests can be performed. Visual analysis: blood high in MetHb appears chocolate brown opposed to dark red/violet of deoxygenated blood. Comparing normal and patient's blood side by side can also be helpful. Color chart was created to aid interpretation.¹¹ Blood drop test consists of placing 1-2 drops of patient's blood on white filter paper and exposing it to atmospheric/supplemental oxygen. While venous (deoxyhemoglobin rich) blood brightens upon oxygen exposure, no change occurs in patients with methemoglobinemia. However, all bedside tests rely considerably on clinician's perception of color and therefore are prone to variable interpersonal interpretation.

Diagnosis of hereditary methemoglobinemia requires additional investigation alongside the aforementioned. CYB₅R activity test is important to establish an accurate diagnosis. Neonates have only 50-60% of the normal adult level of CYB₅R

activity and it is not until the age of 12 months that the adult range is attained.¹² Observing reduced CB₅R activity in leuco-

cytes as well as erythrocytes confirms diagnosis of type II methemoglobinemia.⁷ Genetic testing for type II disease should be

Table 1. Capillary blood gas measurement results.

Blood gas analyzer	ABL90 FLEX		ABL800 BASIC*	
pH	7.422	7.415	7.450	7.450
pO ₂	48.0	48.4	46.5	55.3
pCO ₂	37.7	42.2	38.4	31.4
MetHb (%)	2.8	2.6	3.2	4.0
BE	0.4	1.9	2.6	-0.5
Lac	1.9	1.7	1.3	-

*Central laboratory analyzer. MetHb, methemoglobin; BE, base excess; Lac, lactate.

Table 2. Clinical symptoms in relation to MetHb blood concentration.

MetHb % of total Hb	Symptoms
<10	Asymptomatic
10-20	Cyanosis
20-40	Headache, fatigue, weakness, tachycardia, and dizziness
40-50	Dyspnea and lethargy
50-70	Acidosis, arrhythmias, hypoxia, seizures and coma
>70	Death

MetHb, methemoglobin; Hb, hemoglobin.

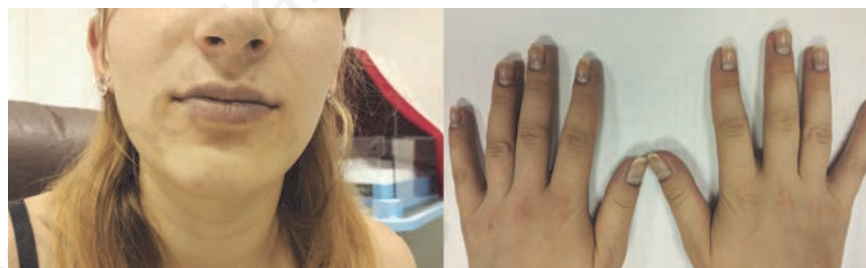


Figure 1. Phenotypic features of the mother.



Figure 2. Markedly darker discoloration of blood compared with healthy controls (1, patient; 2, patient's mother; 3, 4, healthy controls).

made available to all affected families, due to high recurrence rate and poor prognosis.⁵ Hemoglobin electrophoresis is necessary for excluding hemoglobinopathies such as hemoglobin M disease.¹³

In our case primary testing of MetHb was faulty and misleading, which resulted in misdiagnosis and unnecessary interventions for the child, unwarranted separation and anxiety for the parents as well as increased length of stay associated with treatment expenses. Both blood gas analyzers used use spectrophotometry for measuring MetHb in blood, only ABL800 BASIC analysis revealed increased MetHb content. We were unable to ascertain the cause, as sampling or storing errors could not account for inaccurate readings for multiple samples taken before and after device calibration. The case highlights the importance of critical evaluation of device measurements even in tested analyzers as failing measurements or false results can occur.^{14,15} Although our diagnosis was not complete, as Cytochrome B reductase activity was not determined, no clinical signs except of mild cyanosis, no cognitive delay in child's development at 6 months of age and otherwise healthy family phenotype suggests type I disease.⁶ Early cyanosis, which improved over time without specific treatment could be explained by low CYB₅R activity in infants at birth.¹⁶ It is unlikely, that in our patients MetHb concentration would increase without external offending agents or oxidative stress, as CYB₅R activity increases with age and reaches adult levels at the end of 1 year of life.¹²

Management

Increased MetHb concentration above 10% should be the indication for treatment of methemoglobinemia in neonates. Mainstay of therapy is IV administration of methylene blue (0.5-2mg/kg over 5 min) with or without placement in hyperbaric oxygen chamber.¹⁷ Effects usually are visible within an hour, but if insufficient reduction is achieved, infusion can be repeated after 60 minutes. In neonates it is recommended to start at lower end of the dose, as it might be as effective as higher and carries lower risk of hemolysis.¹⁸ If side effects (hemolytic anemia) arise or there is no effect of medical treatment, exchange blood

transfusion may be recommended.¹⁹

Conclusions

Congenital methemoglobinemia is a rare condition, presenting with cyanosis without respiratory distress and should rouse suspicion in clinicians when more common causes are eliminated. Syndrome severity depends on percentage of MetHb in the blood and ranges from asymptomatic presentation to life threatening hypoxia, due to reduced oxygen availability to the tissues. In neonatal population, treatment should be initiated early, due to limited compensatory capabilities in the first month of life. Prognosis depends on the disease type: type I leads a normal life while most patients with type II succumb to the disease in infancy.

References

- Christensen RD, Henry E, Jopling J, Wiedmeier SE. The CBC: reference ranges for neonates. *Semin Perinatol* 2009;33:3-11.
- Agarwal N, Nagel RL, Prchal JT. Dyshemoglobinemias. In: Steinberg MH, Forget BG, Higgs DR, Weatherall DJ, eds. *Disorders of hemoglobin*. Cambridge: Cambridge University Press; 2009. pp. 607-622.
- Lin CY, Yang JM, Chen CT, et al. Anesthetic management of a patient with congenital methemoglobinemia. *Acta Anaesthesiol Taiwan* 2009;47:143-6.
- Jaffé ER. Hereditary methemoglobinemias associated with abnormalities in the metabolism of erythrocytes. *Am J Med* 1966;41:786-98.
- Percy MJ, Lappin TR. Recessive congenital methaemoglobinaemia: Cytochrome b5reductase deficiency. *Br J Haematol* 2008;141:298-308.
- Toelle SP, Boltshauser E, Mössner E, et al. Severe neurological impairment in hereditary methaemoglobinaemia type 2. *Eur J Pediatr* 2004;163:207-9.
- Ewencyk C, Leroux A, Roubergue A, et al. Recessive hereditary methaemoglobinaemia, type II: Delineation of the clinical spectrum. *Brain* 2008;131:760-71.
- Toobiak S, Sher EA, Shaklai M, Shaklai N. Precise quantification of haemoglobin in erythroid precursors and plasma. *Int J Lab Hematol* 2011;33:645-50.
- Srinivasan AJ, Morkane C, Martin DS, Welsby IJ. Should modulation of p50 be a therapeutic target in the critically ill? *Expert Rev Hematol* 2017;10:449-58.
- Caboot JB, Jawad AF, McDonough JM, et al. Non-invasive measurements of carboxyhemoglobin and methemoglobin in children with sickle cell disease. *Pediatr Pulmonol* 2012;47:808-15.
- Shihana F, Dissanayake DM, Buckley NA, Dawson AH. A simple quantitative bedside test to determine methemoglobin. *Ann Emerg Med* 2010;55:184-9.
- Panin G, Pernechele M, Giurioli R, et al. Cytochrome b5 reductase activity in erythrocytes and leukocytes as related to sex and age. *Clin Chem* 1984;30:701-3.
- Rehman HU. Methemoglobinemia. *West J Med* 2001;175:193-6.
- Seeger C, Kawiecki RW, Kristensen HB. Analytical performance of the ABL90 FLEX blood gas analyzer. *Point Care* 2011;10:108-15.
- Schiemsky T, Penders J, Kieffer D. Failing blood gas measurement due to methemoglobin forming hemoglobin variants: a case report and review of the literature. *Acta Clin Belg* 2016;71:167-70.
- Wright RO, Lewander WJ, Woolf AD. Methemoglobinemia: etiology, pharmacology, and clinical management. *Ann Emerg Med* 1999;34:646-56.
- Da-Silva SS, Sajan IS, Underwood JP. Congenital methemoglobinemia: a rare cause of cyanosis in the newborn—a case report. *Pediatrics* 2003;112:158-61.
- Guay J. Methemoglobinemia related to local anesthetics: a summary of 242 episodes. *Anesth Analg* 2009;108:837-45.
- Kern K, Langevin PB, Dunn BM. Methemoglobinemia after topical anesthesia with lidocaine and benzocaine for a difficult intubation. *J Clin Anesth* 2000;12:167-72.