

# Iatrogenic colonoscopic perforations: a review of 8 158 patients

---

Darius Kazanavičius<sup>1</sup>,

Narimantas Evaldas  
Samalavičius<sup>2</sup>

<sup>1</sup>Center of Oncosurgery,  
Institute of Oncology,  
Vilnius University,  
Vilnius, Lithuania;  
Medical Faculty of  
Vilnius University

<sup>2</sup>Clinic of Internal Diseases,  
Family Medicine and Oncology,  
Medical Faculty,  
Vilnius University;  
Center of Oncosurgery,  
Institute of Oncology,  
Vilnius University,  
Vilnius, Lithuania

**Purpose.** The aim of the study is to determine the incidence of perforation after colonoscopy (CP) in our institution, and to evaluate the endoscopic information, clinical presentation, diagnosis workup, intra-operative findings, management and outcomes of patients with CP.

**Methods.** All colonoscopies performed between January 2005 and December 2011 at the Oncology Institute of Vilnius University, Lithuania, searched for colonoscopic perforations. Medical records of all CP patients were reviewed. Incidence of CP, patients' characteristics, endoscopic information, intra-operative findings, management and outcomes were analyzed.

**Results.** A total of 8,158 colonoscopies (7,467 diagnostic and 691 therapeutic) were performed in our hospital over a 7-year period. Five patients (0.061%) had CP: 2 from diagnostic colonoscopy (incidence 0.027%) and 3 from therapeutic one (0.43%). In two cases, perforation was noticed by the endoscopist through visualization of extra-intestinal tissue during the procedure. Other perforations (n = 3, 60%) were diagnosed after the procedure. The most consistent symptom was abdominal pain followed by tenderness, abdominal distension, leukocytosis. The most common site of perforation was in the sigmoid colon (n = 3, 60%). Perforations were caused by direct trauma from the endoscope (n = 2, 40%) and endoscopic polypectomy (n = 3, 60%). All patients with CP underwent surgical management: primary repair. The mortality rate was 0% and the postoperative complication rate was 40%.

**Conclusions.** CP is a serious but rare complication of colonoscopy. Incidence of CP was 0.061%. Therapeutic procedures have a higher perforation risk than diagnostic procedures. The sigmoid colon is the area at the greatest risk of perforation. Surgery is still the mainstay of CP management.

**Key words:** colon perforation, colonoscopy, complication, incidence

---

Correspondence to: Darius Kazanavičius, Centre of Oncosurgery, Institute of Oncology, Vilnius University, Santariškių 1, LT-08406 Vilnius, Lithuania.  
E-mail: dkazanavicius@gmail.com

## INTRODUCTION

There are increasing numbers of patients undergoing colonoscopy for diagnostic and therapeutic purposes such as screening and surveillance of colorectal cancer, polypectomies (1). The increasing

number of indications associated with more aggressive therapeutic measures has resulted in an increase in the number of iatrogenic complications (2). One of the most serious complications is perforation of the colon (CP). The incidence of CP during diagnostic versus therapeutic colonoscopy ranges between 0.03–0.9% and 0.7–2%, respectively (1–3).

Although CP is a rare complication, it is associated with a high rate of morbidity and mortality. This complication could result in operation, stoma formation, intraabdominal sepsis, prolonged hospital stay and even death. The reported morbidity following CP is about 40% and mortality might be up to 14% (1, 3–6).

The purpose of this article is to determine the incidence of perforation after colonoscopy of our institution, and to evaluate the clinical presentation, diagnosis workup, intra-operative findings, management and outcomes of these patients.

## MATERIALS AND METHODS

Colonoscopies performed between January 2005 and December 2011 at the Oncology Institute of Vilnius University, Lithuania, searched for colonoscopic perforations. Medical records of all CP patients were reviewed.

A perforation was defined as a visualization of extraintestinal structure during the endoscopic examination, presence of pneumoperitoneum or retroperitoneal gas with signs of peritonitis after the procedure, and intraoperative findings of a perforated colon. The time to presentation was divided into three periods: <12 hours, 12–24 hours and >24 hours.

The incidence of CP, patients' characteristics, management, intra-operative findings and outcomes were analyzed.

## RESULTS

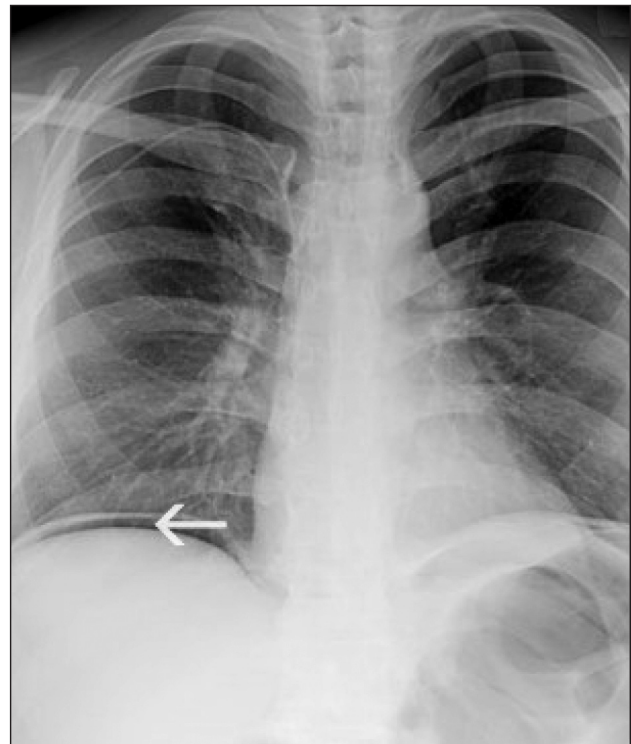
Between 2005 and 2011, a total of 8,158 endoscopic procedures of the colon (7,467 diagnostic and 691 therapeutic) were performed in our hospital. In this 7-years period, 5 patients were found to have iatrogenic perforation, meaning a perforation rate of 0.061%. Diagnostic procedures accounted for 2 (0.027%) perforations, and 3 (0.43%) occurred during therapeutic colonoscopies (Table 1).

**Table 1.** Incidence of perforation after colonoscopy

	Diagnostic	Therapeutic
	0.027%	0.43%
Total	0.061%	

The mean age at the time of CP diagnosis was 64 (range 54–71 years), and all the patients were male. Primary colonoscopic indications included polyps (n = 3, 60%) and positive iFOBT reaction (n = 2, 40%).

Perforations were caused by direct trauma from the endoscope (n = 2, 40%) and endoscopic polypectomy (n = 3, 60%). In two cases, perforation was noticed by the endoscopist through visualization of extra-intestinal tissue during the procedure. Other perforations were diagnosed after the procedure: 1 within the first 12 hours, 1 between 12 and 24 hours, and 1 patient had delayed diagnosis after 24 hours (27 hours). The most consistent symptom was abdominal pain followed by guarding and rebound tenderness, abdominal distension, leukocytosis. Four patients (80%) had local or diffuse peritonitis (Table 2). Presence of pneumoperitoneum for the patients in whom the perforation was not directly seen during the endoscopy but was suspected based on the signs and symptoms, was diagnosed by X-ray (Figure).



**Figure.** Presence of intraperitoneal air in chest X-ray

**Table 2.** Clinical presentation and frequency of symptoms in colonoscopic perforations

Symptoms and signs	Frequency, %
Abdominal pain	100
Guarding and/or rebound tenderness	80
Abdominal distention	80
Tachycardia	60
Leukocytosis	40
Perforation seen during colonoscopy	40
Haemorrhage	20

Altogether, four patients underwent surgery on the same day as endoscopy, one on the second day. Most perforations were found in the sigmoid colon ( $n = 3$ , 60%) and 1 each in the ascending colon and the splenic flexure of the colon. Although, in one of 5 cases, ischemic polypectomy site was seen with no actual perforation. All patients underwent primary repair: colorrhaphy without diversion.

Of the four patients, 3 (60%) had no complications and showed a fast postoperative recovery. The

remaining two experienced complications: wound infection. For all the patients, the mean hospital stay was 10.8 days (range 8–15). We had no fatal outcomes. Details of all clinical features of the perforation are shown in Table 3.

## DISCUSSION

The incidence of CP in the high-volume centers is estimated between 0.1% and 0.6% in various case series (1, 4, 5, 7–12). The incidence of CP from diagnostic colonoscopy ranges between 0.03% and 0.9%, while the same incidence from therapeutic colonoscopy ranges from 0.7% to 2% (1–3). Our overall perforation rate of 0.061% or one perforation per 1,631 colonoscopies is in accordance with the above range reported in the literature. The perforation rate regarding diagnostic and therapeutic colonoscopy was 0.27% and 0.43%, respectively, during a 7-years period with 8,158 procedures. The incidences of CP in our study and some larger series are shown in Table 4 (1, 4, 5, 7–12). However,

**Table 3.** Details of patients with colonoscopic perforation (CP)

Age, sex	Endoscopic procedure	Time to CP presentation	Perforated site	Size of defect, mm	Hospital stay, days
69, M	D	During colonoscopy	Sigmoid colon	20	10
67, F	D	During colonoscopy	Sigmoid colon	10	10
70, M	T (polypectomy)	< 12 hours	Sigmoid colon	7	11
54, M	T (polypectomy)	> 24 hours	Ascending colon	23	15
64, M	T (polypectomy)	12–24 hours	Splenic flexure	n/a	8

M = male, F = female, T = therapeutic colonoscopy, D = diagnostic colonoscopy, n/a = not available

**Table 4.** Incidence of CP, management and outcomes from recent series

Author	Year	Number of patients	CP rate, %	Surgical treatment, %	Mortality, %
Araghizadeh et al. [8]	2001	34 620	0.090	74	3.2
Gatto et al. [7]	2003	74 584	0.145	n/a	5.6
Korman et al. [11]	2003	116 000	0.032	95	0.0
Cobb et al. [10]	2004	43 609	0.032	93	0.0
Lüning et al. [5]	2007	30 366	0.115	100	8.6
Rabeneck et al. [12]	2008	97 091	0.085	n/a	n/a
Iqbal et al. [1]	2008	258 248	0.070	92	7.0
Teoh et al. [4]	2009	37 971	0.113	91	25.6
Arora et al. [9]	2009	277 434	0.082	n/a	n/a
Our study	2012	8 158	0.061	100	0.0

CP = colonoscopic perforation, n/a = not available

it has to be mentioned that there may be small sub-clinical perforations which healed spontaneously or patients with perforations who presented late in a different hospital and, thus, were missed in the follow-up and not included in the above rate calculations.

There has been convincing evidence that therapeutic colonoscopies have a significantly higher rate of CP than diagnostic colonoscopies (9, 12, 13). The increased likelihood of CP in therapeutic endoscopy is because the perforation can occur not only through mechanisms that are similar to those seen for diagnostic colonoscopy (mechanical perforation by the endoscope's top or loop, barotraumas from overinsufflation), but also during a snare polypectomy or with direct thermal injury to the bowel wall.

Furthermore, CPs after therapeutic procedures are often diagnosed late, probably because of the abovementioned different pathophysiologic mechanisms. In diagnostic procedures, perforations most often result from pressure to the colonic wall and can be noticed immediately via visualization of extra-intestinal tissue by the endoscopist. In the case of therapeutic procedures, ischemia of the colonic wall caused by electrical or thermal injury after electrocoagulation can cause delayed perforation. In our study CPs after diagnostic colonoscopies were noticed immediately during the procedure, as compared with 0.65 days until perforation diagnosis after therapeutic procedures.

Other risk factors for CP may include female gender, advanced age, a history of diverticular disease, previous intraabdominal surgery or colonic obstruction as an indication for colonoscopy (7, 9, 11, 14–16).

Saunders and co-workers demonstrated that women had a greater colonic length and a more mobile transverse colon, suggesting this as the cause for more difficult procedures (17). Pelvic surgery, more commonly performed for females, is another risk factor for CP mentioned in the literature (11). Unexpectedly, in our study, 80% of CP occurred in males, probably due to low CP count.

Patients over 75 years of age also have an approximately 4–6 fold rise in the CP rate as opposed to younger patients (7, 12, 13, 18). Possible explanations include the fact that the elderly have a declining colonic wall mechanical strength as recognized in colonic diverticular disease, and

they often have a greater frequency of abnormal colorectal findings which may require endoscopic intervention.

In our study the sigmoid colon was perforated in 3 of 5 cases. It is known that the sigmoid colon is the most common site of CP (1, 3–5, 11, 13). Several factors making this bowel segment vulnerable to being injured include a sharp angulation or great mobility of the sigmoid colon. Additionally, the sigmoid colon is commonly involved in diverticular formation (19), and the muscular layer may be thin or fragile due to previous inflammation (diverticulitis). Pelvic adhesions following previous pelvic operation or infection also contribute to a high incidence of sigmoid perforation (1).

All patients with CP in our institute received surgical treatment. Most authors emphasize this strategy (1–5, 8, 20). Clearly, it is indicated for patients with diffuse peritonitis, those who fail non-operative treatment, and those with large injuries. The specific operative procedure selected will depend on the size and duration of the perforation, the degree of peritoneal soilage, the presence of associated colon pathology, the stability and overall medical condition of the patient. If there is no specific pathology and extensive wall inflammation at the site of the perforation, which is usually the case with patients that are diagnosed in the first 12 hours after the colonoscopy, then a primary repair of the defect may be performed with or without creation of protective ostomy. If, however, the segment of the perforated bowel contains tumour, stricture or a large injury with very inflamed wall, then colon resection should be the selected surgical option (1–5, 8, 20).

More recently, there have been reports of successful nonoperative management in selected patients. Conservative management is reserved for CP patients in good general condition and without any sign of peritonitis. This approach involves intravenous fluids, absolute bowel rest and intravenous administration of broad-spectrum antibiotics. This management is similar to that used to treat acute diverticular disease. The reported success rate with this option varies from less than 20% to 73% (1–4, 10, 21, 22). If there is no resolution of signs and symptoms, surgical treatment is warranted.

With recent advances in endoscopic technology, increasing experience of endoscopic interventions,



it is possible to perform the endoscopic closure of CP, since the first successful endoscopic repair of CP was reported in 1997 (23). The ability to close the defect will depend on 4 main factors: (1) localization and size of perforation (recommended <10 mm), (2) stool contamination, (3) availability of instruments and (4) endoscopist's expertise and skills. The reported success rate is between 69% and 93% (2, 3, 24, 25).

Another issue under discussion is the role of laparoscopic surgery for CP. The perforation can be identified, and small perforations can be sewn or small tangential resections can be performed. The laparoscopic approach is feasible in experienced hands in 70% of the cases (26–28). Laparotomy is considered if the perforation is not identified and if doubts regarding the repair process exist (29).

However, the management of CP remains controversial, since there are no randomized trials or specific guidelines. It has to be stated clearly that each case needs to be managed individually, taking into account the comorbidities of the patient and the exact interventions and mechanisms during the colonoscopy that lead to the perforation.

Patients with CP could have a remarkably high morbidity and mortality rate. Reported 30-d morbidity and mortality rates are 21–53% and 0–26%, respectively (1, 3–6). The average length of hospital stay in CP patients is 1–3 weeks (3, 4, 6, 20). Our overall morbidity rate of 50% without fatal outcomes is in accordance with the above range reported in the literature. Surgical site infection is the most common complication (1, 3). We cannot identify risk factors for developing postoperative complication in CP patients due to a small sample size and limitation in its power. However, some investigators have suggested that predisposing factors for poor outcomes of CP patients include a large perforation site, delayed diagnosis, extensive peritoneal contamination, poor bowel preparation, corticosteroid use, anticoagulants or antiplatelet therapy, prior hospitalization, advanced age of patients, and severe comorbid diseases (1, 4, 30).

## CONCLUSIONS

Iatrogenic colonic perforation is a serious but rare complication of colonoscopy. Risk of perforation was 0.061% that is comparable with frequencies

found in literature. Therapeutic procedures have a higher perforation risk than diagnostic procedures. The sigmoid colon is the area at the greatest risk of perforation. Immediate operative management, preferably primary repair, appears to be the best strategy for most patients.

Received 21 January 2012

Accepted 21 February 2012

## References

1. Iqbal CW, Cullinane DC, Schiller HJ, Sawyer MD, Zietlow SP, Farley DR. Surgical management and outcomes of 165 colonoscopic perforations from a single institution. *Arch Surg.* 2008; 143(7): 701–6.
2. Lohsiriwat V. Colonoscopic perforation: incidence, risk factors, management and outcome. *World J Gastroenterol.* 2010; 16(4): 425–30.
3. Lohsiriwat V, Sujarittanakarn S, Akaraviputh T, Lertakyamanee N, Lohsiriwat D, Kachinthorn U. Colonoscopic perforation: a report from World Gastroenterology Organization endoscopy training center in Thailand. *World Gastroenterol.* 2008; 14: 6722–5.
4. Teoh AY, Poon CM, Lee JF, Leong HT, Ng SS, Sung JJ, et al. Outcomes and predictors of mortality and stoma formation in surgical management of colonoscopic perforations: a multicenter review. *Arch Surg.* 2009; 144: 9–13.
5. Lüning TH, Keemers-Gels ME, Barendregt WB, Tan AC, Rosman C. Colonoscopic perforations: a review of 30,366 patients. *Surg Endosc.* 2007; 21: 994–7.
6. Mai CM, Wen CC, Wen SH, Hsu KF, Wu CC, Jao SW, et al. Iatrogenic colonic perforation by colonoscopy: a fatal complication for patients with a high anesthetic risk. *Int J Colorectal Dis.* 2009; Epub ahead of print.
7. Gatto NM, Frucht H, Sundararajan V, Jacobson JS, Grann VR, Neugut AI. Risk of perforation after colonoscopy and sigmoidoscopy: a population-based study. *J Natl Cancer Inst.* 2003; 95: 230–6.
8. Araghizadeh FY, Timmcke AE, Opelka FG, Hicks TC, Beck DE. Colonoscopic perforations. *Dis Colon Rectum.* 2001; 44: 713–6.
9. Arora G, Mannalithara A, Singh G, Gerson LB, Triadafilopoulos G. Risk of perforation from

- a colonoscopy in adults: a large population-based study. *Gastrointest Endosc.* 2009; 69: 654–64.
10. Cobb WS, Heniford BT, Sigmon LB, Hasan R, Simms C, Kercher KW, et al. Colonoscopic perforations: incidence, management, and outcomes. *Am Surg.* 2004; 70: 750–8.
  11. Korman LY, Overholt BF, Box T, Winker CK. Perforation during colonoscopy in endoscopic ambulatory surgical centers. *Gastrointest Endosc.* 2003; 58: 554–7.
  12. Rabeneck L, Paszat LF, Hilsden RJ, Saskin R, Leddin D, Grunfeld E, et al. Bleeding and perforation after outpatient colonoscopy and their risk factors in usual clinical practice. *Gastroenterology.* 2008; 135: 1899–906.
  13. Lohsiriwat V, Sujarittanakarn S, Akaraviputh T, Lertakyamanee N, Lohsiriwat D, Kachinthorn U. What are the risk factors of colonoscopic perforations? *BMC Gastroenterol.* 2009; 9: 71.
  14. Anderson ML, Pasha TM, Leighton JA. Endoscopic perforation of the colon: lessons from a 10-years study. *Am J Gastroenterol.* 2000; 95: 3418–22.
  15. Repici A, Pellicano R, Strangio G, Danese S, Fa-goonee S, Malesci A. Endoscopic mucosal resection for early colorectal neoplasia: pathologic basis, procedures, and outcomes. *Dis Colon Rectum.* 2009; 52: 1502–15.
  16. Lorenzo-Zuniga V, Vega VM, Domenech E, Manosa M, Planas R, Boix J. Endoscopist experience as a risk factor for colonic complications. *Colorectal Dis.* 2010; 12: e273–7.
  17. Saunders BP, Fukumoto M, Halligan S, Jobling C, Moussa ME, Bartram CI, et al. Why is colonoscopy more difficult in women? *Gastrointest Endosc.* 1996; 43: 124–6.
  18. Levin TR, Zhao W, Conell C, Seeff LC, Manninen DL, Shapiro JA, et al. Complications of colonoscopy in an integrated health care delivery system. *Ann Intern Med.* 2006; 145: 880–6.
  19. Waye JD. Colonoscopic polypectomy. *Diagn Ther Endosc.* 2000; 6: 111–24.
  20. Tulchinsky H, Madhala-Givon O, Wasserberg N, Lelcuk S, Niv Y. Incidence and management of colonoscopic perforations: 8 years experience. *World J Gastroenterol.* 2006; 12: 4211–3.
  21. Castellvi J, Pi F, Sueiras A, Vallet J, Bollo J, Tomas A, et al. Colonoscopic perforation: useful parameters for early diagnosis and conservative treatment. *Int J Colorectal Dis.* 2011; 26: 1183–90.
  22. Avgerinos DV, Llaguna OH, Lo AY, Leitman IM. Evolving management of colonoscopic perforations. *J Gastrointest Surg.* 2008; 12(10): 1783–9.
  23. Yoshikane H, Hidano H, Sakakibara A, Ayakawa T, Mori S, Kawashima H, et al. Endoscopic repair by clipping of iatrogenic colonic perforation. *Gastrointest Endosc.* 1997; 46: 464–6.
  24. Magdeburg R, Collet P, Post S, Kaehler G. Endo-clipping of iatrogenic colonic perforation to avoid surgery. *Surg Endosc.* 2008; 62(5): 791–5.
  25. Jovanovic I, Zimmermann L, Fry LC, Mönkemüller K. Feasibility of endoscopic closure of an iatrogenic colon perforation occurring during colonoscopy. *Gastrointest Endosc.* 2011; 73(3): 550–5.
  26. Alfonso-Ballester R, Lo Pez-Mozos F. Laparoscopic treatment of endoscopy sigmoid colon perforation: a case report and literature review. *Surg Laparosc Endosc Percutan Tech.* 2006; 16: 44–6.
  27. Rumstadt B, Schilling D, Sturm J. The role of laparoscopy in the treatment of complications after colonoscopy. *Surg Laparosc Endosc Percutan Tech.* 2008; 18(6): 561–4.
  28. Bleier JI, Moon V, Feingold D, Whelan RL, Arnell T, Sonoda T, et al. Initial repair of iatrogenic colon perforation using laparoscopic methods. *Surg Endosc.* 2008; 22: 646–9.
  29. Hansen AJ, Tesier DJ, Anderson ML, Schlinkert RT. Laparoscopic repair of colonoscopic perforations: indications and guidelines. *J Gastrointest Surg.* 2007; 11: 655–9.
  30. Iqbal CW, Chun YS, Farley DR. Colonoscopic perforations: a retrospective review. *J Gastrointest Surg.* 2005; 9: 1229–35.

Darius Kazanavičius,  
Narimantas Evaldas Samalavičius

### KOLONOSKOPINĖS STOROSIOS ŽARNOS PERFORACIJOS: 8158 PACIENTŲ APŽVALGA

#### *Santrauka*

**Tikslas.** Nustatyti kolonoskopinių storosios žarnos perforacijų (KP) dažnį, įvertinti pacientų būklę, komplikacijos klinikinę išraišką, diagnozės nustatymo ypatumus, gydymą, operacinius radinius bei išeitį.

**Metodika.** Retrospektyviai peržiūrėti duomenis pacientų, kuriems atlikta diagnostinė ar gydomoji kolonoskopija Vilniaus universiteto Onkologijos institute nuo 2005 m. sausio 1 d. iki 2011 m. gruodžio 31 d. Atrinkti pacientai, kuriems procedūra sukėlė KP. Analizuotas perforacijų dažnis, pacientų būklė, klinika, diagnozės nustatymo ypatumai, gydymas, operaciniai radiniai, išeitys.

**Rezultatai.** Nuo 2005 m. sausio iki 2011 m. gruodžio Institute atliktos 8158 kolonoskopijos (7467 diagnostinės, 691 gydomoji). Penkiems pacientams procedūra

sukėlė KP (bendras dažnis 0,061 %): dviem pacientams perforacija nustatyta po diagnostinės kolonoskopijos (dažnis 0,027 %), trimis – po gydomosios (0,43 %). Dviem pacientams (40 %) KP angą diagnostinės procedūros metu pastebėjo gydytojas, kitos (60 %) diagnozuotos po procedūros. Dažniausi KP simptomai: pilvo skausmas, tachikardija, pilvaplėvės dirginimas, raumenų tempimas, leukocitozė. Daugiau kaip pusei (60 %, n = 4) pacientų defektas aptiktas riestinėje žarnoje. Visiems pacientams taikytas chirurginis KP gydymas – užsiūtas defektas. Pooperacinės komplikacijos – 40 %, mirštamumas – 0 %.

**Išvados.** KP yra reta, tačiau pavojinga kolonoskopijos komplikacija. Nustatytas 0,061 % perforacijos dažnis. Didesnė perforacijos rizika yra atliekant gydomąją nei diagnostinę kolonoskopiją. Dažniausiai pažeidžiama riestinė žarna. Šiuo metu tinkamiausia KP gydymo strategija – skubus chirurginis gydymas.

**Raktažodžiai:** kolonoskopija, kolonoskopinės perforacijos, komplikacija, dažnis