

Hand-assisted laparoscopic colorectal surgery for colorectal polyps: single institution experience

Ranka asistuojamoji laparoskopinė chirurgija gydant endoskopiškai nepašalinamus storosios žarnos polipus

Audrius Dulskas¹, Narimantas Evaldas Samalavicius², Rakesh Kuma Gupta³

¹ *Center of Oncosurgery, Institute of Oncology, Vilnius University, 1 Santariskiu Street, LT-08406, Vilnius, Lithuania*
E-mail: audrius.dulskas@gmail.com

² *Center of Oncosurgery, Institute of Oncology, Clinic of Internal Diseases, Family Medicine and Oncology of Medical Faculty, Vilnius University, 1 Santariskiu Street, LT-08406, Vilnius, Lithuania*

³ *Department of Surgery, B.P. Koirala Institute of Health Sciences, Dharan, Nepal*

Objective

To assess outcomes of a hand-assisted laparoscopic approach (HALS) for the management of difficult colorectal polyps.

Methods

In 2007–2013 at the Institute of Oncology, Vilnius University, 25 HALS colorectal procedures for polyps which could not be treated by endoscopy were performed. Demographic data, histology of the biopsy, type of surgery, length of postoperative stay, complications and final pathology were reviewed prospectively.

Results

25 patients with a mean age of 65.88 ± 13.3 years underwent HALS polypectomy. Preoperative morphology was: 20 (80%) patients with adenomas and 5 (20%) – Ca in situ. Laparoscopic mobilization of colonic segment, and colotomy with removal of polyp was performed for 5 (20%) polyps. Laparoscopic segmental bowel resection was performed in 20 (80%): anterior rectal resection with partial total mesorectal excision – 10 (40%), left hemicolectomy – 6 (24%), sigmoid resection – 3 (12%) and resection of transverse colon in 1 (4%).

Mean postoperative hospital stay was 6.4 ± 2.5 days. Two patients (8%) had complications – urinary tract infection. Both recovered after conservative treatment. Mean polyp size was 3.8 ± 2.2 cm. Final pathology revealed polyp ($n = 1$), tubular adenoma ($n = 3$), tubulovillous adenoma ($n = 12$), Carcinoma in situ ($n = 7$) and invasive cancer ($n = 2$). Both patients underwent laparoscopic left hemicolectomies (HALS) in 14 and 10 days after laparoscopic colotomy and polypectomy.

Conclusions

For the management of endoscopically unresectable polyps, laparoscopic polypectomy is currently the technique of choice.

Key words: colotomy, colorectal polyp, polyp, HALS.

Tikslas

Išnagrinėti ranka asistuojamosios laparoskopinės chirurgijos (HALS) vaidmenį gydant endoskopiškai nepašalinamus storo-
sios žarnos polipus.

Metodai

2007–2013 metais Vilniaus universiteto Onkologijos institute buvo atliktos 25 polipų šalinimo HALS operacijos. Prospektyviai buvo išanalizuoti demografiniai rodikliai, histologijos duomenys, atliktų operacijų pobūdis, pooperacinio periodo trukmė, komplikacijos ir galutinė patologijos diagnozė.

Rezultatai

Operuoti 25 pacientai, kurių amžiaus vidurkis buvo $65,88 \pm 13,3$ metai. Priešoperacinė diagnozė: 20 (80 %) atvejų adenoma ir 5 (20 %) – *Ca in situ*. Žarnos segmento mobilizacija su kolotomija ir polipo pašalinimu buvo atlikta 5 (20 %) pacientams. Žarnos segmento rezekcija HALS atlikta – 20 (80 %) atvejų: tiesiosios žarnos rezekcija su visiška mezorektaline ekscizija (TME) – 10 (40 %), kairioji hemikolektomija – 6 (24 %), riestinės žarnos rezekcija – 3 (12 %) ir skersinės žarnos rezekcija – 1 (4 %). Vidutinė pooperacinio periodo trukmė buvo 6.4 ± 2.5 dienos. Dviem pacientams pasireiškė dizurijos reiškiniai (8 %). Abu pacientai pasveiko po taikyto konservatyvaus gydymo. Vidutinis polipo dydis $3,8 \pm 2,2$ cm. Gauta galutinė patologijos diagnozė: polipas (n = 1), tubulinė adenoma (n = 3), tubuloviliozinė adenoma (n = 12), *Carcinoma in situ* (n = 7), invazyvus tumoras (n = 2). Abiem pacientams atlikta HALS kairė hemikolektomija praėjus 14 ir 10 dienų po kolotomijos su polipektomija.

Išvada

HALS galima kaip saugi alternatyva endoskopiškai nepašalinamiems polipams gydyti.

Reikšminiai žodžiai: kolotomija, kolorektalinis polipas, polipas, HALS.

Introduction

Colorectal cancer (CRC) is a leading cause of cancer-related death in the western world [1]. Adenomatous colorectal polyps have a malignant potential well described in Vogelstein's adenoma-carcinoma sequence [2, 3]. Removal of colon adenomas is associated with a reduction in the incidence of CRC. Thus, CRC largely could be prevented by the detection and removal of adenomatous polyps. There are several methods to remove polyps by using either endoscopic or surgical methods [4]. Patients who have known adenomas and refuse removal develop colon cancer at the rate of 4% after 5 years and 14% after 10 years, which is higher than that of the general population [5]. Endoscopic removal of polyps has been shown to arrest subsequent development of carcinoma [6].

Because of their difficult location or size some polyps are impossible to remove by flexible colonoscopy and must be surgically removed. The laparoscopic approach has introduced two technical challenges; firstly the localization of the polyp and secondly its proper surgical extirpation. First problem is overcome with HALS technique. Depending on the shape of the polyp, its size and location, proper extirpation can be performed through a colotomy (pedunculated or small sessile pol-

yps) or a limited colectomy (large sessile polyps) or an oncological resection in case of suspicion of carcinoma. The potential advantages of laparoscopic surgery are faster recovery, a low rate of incisional hernia, and the reduction of peritoneal adhesions [7].

There have been a number of small reports on laparoscopic removal of colorectal polyp [7, 8]. In this current study, we report our experience of removal of 25 'benign' colonic polyps using HALS. Based on this patient experience, we more fully describe the broad utility and expected outcomes for laparoscopic removal of colorectal polyp.

Patients and methods

A prospectively maintained database was used to identify all patients who underwent HALS polypectomy at the Institute of Oncology, Vilnius University, from November 2007 to January 2013. All consented patients aged 18 years or older with histologically confirmed adenoma included in this study. Invasive carcinoma was criteria for exclusion. During the period a total of 273 laparoscopic colorectal operations were performed. Twenty five of them were HALS procedures for polyps which could not be treated by endoscopy due to size, lo-

cation, and/or risk of complications. Exact reasons why the referring endoscopist could not achieve endoscopic polypectomy were not available. All patients underwent HALS by one surgeon (NES). Demographic data, past surgical history, preoperative polyp morphology and histology of the biopsy, type of surgery, length of postoperative stay, complications, final pathology and stage of cancer (if present) were analyzed prospectively.

Surgical technique

All HALS procedures were performed by one surgeon in the department.

Pre-operative bowel preparation the day before surgery, and intravenous broad-spectrum antibiotics on induction were routine. Under general anesthesia, a 6 cm umbilical incision was made for the hand-port. Trocars were placed according to the type of procedure. If bowel resection was performed the vascular pedicles were initially isolated by a medial to lateral approach, the ureters identified, and a ligation of the vessels performed. Bowel mobilization was then completed. The specimens were retrieved through transumbilical incision and colotomy, and polypectomy (if the polyp was not circular and possible for removal) or resection and anastomosis performed extra-corporeally. Contraindications for colotomy and polyp removal were: circular polyp and risk for bowel stenosis. For anterior resections intra-corporeal anastomosis with an endoanal circular stapler was done. HALS was performed for polyps localized in descending colon, sigmoid and rectum which was possible for specimen retrieval through transumbilical incision.

Follow up was performed under our institutional guidelines: colonoscopy annually.

Statistical methods

All statistical analyses were performed using software (Statistical Package for the Social Sciences, SPSS Inc., Chicago, IL, USA).

All data are presented as mean \pm standard deviation for parametric and median for nonparametric data.

Results

Twenty five patients (12 male and 13 female) with a mean age of 65.88 ± 13.3 years (range: 50 to 82 years),

body mass index (BMI) 27.3 ± 5.8 kg/m² (range: 22–36) underwent elective HALS polypectomy. Twenty (80%) patients were operated for adenoma and 5 (20%) – for Ca in situ. Eight (32%) patients had multiple polyps (two or more) and 2 (8%) patients had previous abdominal surgery. Eight (32%) patients had comorbidities: 6 of them (24%) – cardiac, 2 (8%) – diabetes (Table 1). Laparoscopic mobilization of colonic segment and colotomy and removal of polyp was performed for 5 (20%) polyps (Table 2). Laparoscopic segmental bowel resection was performed in 20 (80%) patients: anterior rectal resection with partial TME – 10 (40%), left hemicolectomy – 6 (24%), sigmoid resection – 3 (12%), and resection of transverse colon in 1 (4%) (Tables 2, 3).

Table 1. Demographic data

Sex	Number (25)
Male	12 (48%)
Female	13 (52%)
Mean age	65.88 \pm 13.3 years (range: 50 to 82 years)
BMI	27.3 \pm 5.8kg/m ² (range: 22–36)
Previous abdominal surgery	2 (8%)
Preoperative pathology	
Adenoma	20 (80%)
Ca in situ	5 (20%)
Mean postoperative hospital stay	6.4 \pm 2.5 days (range: 4 to 14 days)
Conversion rate	0
Mortality rate	0

Table 2. Laparoscopic surgical procedure (n=25)

Transverse colon	n
Colotomy	1
Colon resection	1
Descending colon	n
Colotomy	1
Sigmoid and rectum	n
Colotomy	3
Anterior resection	10
Left hemicolectomy	6
Sigmoid resection	3

Table 3. Procedures performed

Procedure	n (%)
Colotomy and removal of polyp	5 (20%)
Laparoscopic bowel resection	20 (80%)
Rectal resection	10 (40%)
Left hemicolectomy	6 (24%)
Sigmoid resection	3 (12%)
Resection of transverse colon	1 (4%)

Table 4. Final pathology

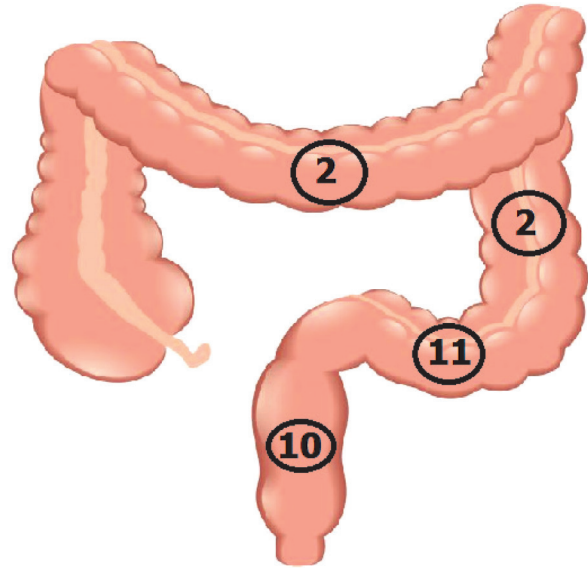
Pathology	n
Tubular adenoma	3
Tubulovillous adenoma	12
Hyperplastic/juvenile polyp	1
Ca in situ	7
Invasive cancer (pT1)	2

Table 5. Cancer risk according to polyp size

Size	Number of polyps (n25)	Incidence of cancer (%)
≤1 cm	1	0
>1 cm, <2 cm	3	0
≥2 cm	21	2(9.5%)

Ten polyps (40%) were in the rectum, 11 – sigmoid (44%), 2 – descending colon (8%) and transverse colon (8%) (Figure 1).

Mean postoperative hospital stay was 6.4 ± 2.5 days (range: 4 to 14 days). All patients but two recovered well and had an uneventful postoperative course. Two postoperative complications were encountered (perioperative morbidity – 8%) – urinary tract infection. Both patients recovered after conservative treatment. There were no deaths or conversions in our group. Mean polyp size was 3.8 ± 2.2 cm (range: 1 to 10 cm). Final pathology revealed polyp (juvenile = 1), tubular adenoma (n = 3), tubulovillous adenoma (n = 12), Carcinoma in situ (n = 7) and pT1 invasive cancer (n = 2) (Table 4). Invasive carcinoma not identified at colonoscopy and biopsy was found in two polyps (8%) – both in tubular adenomas. Both patients underwent laparoscopic left

**Figure 1.** Localization of the polyps

hemicolectomies HALS in 14 and 10 days after laparoscopic colotomy and polypectomy.

All the patients were followed with colonoscopy for 12 months postoperatively, then yearly thereafter. The mean follow up was 2 year (ranging from 6 month to 5 years). There was no incidence of recurrence or any late complications.

Discussion

In the concept of the adenoma–carcinoma sequence, adenomatous polyps are considered to be precursor lesions of colorectal cancer [2, 3]. The rate of adenomas containing invasive cancer has been estimated between 2.6% and 9.4% [7]. Especially, large colonic polyps unresectable at colonoscopy are associated with a high rate of unsuspected cancer. In a study by *Pokala et al.*, postoperative histopathology reports after laparoscopic resection for endoscopically not resectable polyps revealed adenocarcinomas with an initial benign histology in up to 20% [8].

Large, sessile polyps or the inaccessibility for the colonoscopic resection such as the hepatic flexure or the cecum set limits to endoscopy. The size criterion for the definition of ‘large’ adenomas has varied in the literature. Some authors polyps of size >15 mm called

large [6], others - >20-30 mm [9]. *Waye* suggested the definition of difficult polyp – polyp that occupies more than one-third of bowel circumference or 2 haustral folds [10]. The most common minimum size for an adenoma to be considered ‘large’ is 20 mm [9].

In case of endoscopy failure or when malignancy is suspected, a surgical excision should be performed. Surgical options include colotomy in case of pedunculated polyps and small colectomy in case of large, broad-base polyps. Polyps that have established or even possible development of malignant transformation require a formal oncologic resection with truncular ligation and lymphadenectomy [7, 11, 12]. In our study we performed 5 (20%) colotomies with mobilization of colon and polypectomy and 20 (80%) bowel resections. Some author advice not to use colotomy because of the high possibility of exposing the abdominal cavity to cancer cells [13].

Besides, a higher risk of complications, a polyp size of larger than 2.5 cm in diameter, was shown to be significantly correlated with malignant transformation in 51% of the cases in the rectum and 34% in the colon. Furthermore, a published study showed that in only 67–75% of the cases, polyps larger than 3 cm could be completely excised, thus questioning the endoscopic approach [5].

In our study, large polyp size is the commonest cause, after malignant indications, for colorectal polyps being not amenable to endoscopic treatment alone. The median size of these large polyps was 3.8 ± 2.2 cm (range from 1 to 10 cm).

It is difficult to reliably predict which patients would have invasive cancer verified in their final pathology. Association between increasing polyp size and the possibility of harboring cancer is well known.

However, the size of a polyp in patients referred for surgery cannot reliably predict or negate the risk for

cancer. In our series, 2 of 27 (9.5%), had polyp size 2cm or more (2 and 5 cm).

Until recently in our hospital, small resection or anatomical bowel resections were performed by laparotomy, which is associated with a prolonged hospital length of stay, a prolonged postoperative ileus [6]. Laparoscopic colorectal resection HALS has been proven to have faster recovery, decreased morbidity and equivalent long-term oncological safety compared to open procedures [11, 13]. Our study results, post-operative stay, mortality, conversion rate, complications are comparable to the literature [6, 7, 9, 12].

There are various combinations of laparoscopic–endoscopic “rendezvous” procedures including laparoscopically assisted endoscopic transluminal resection, endoscopically assisted wedge or anatomical resections, and finally an intraoperative tumor location by colonoscopy for achieving oncological resection margins in laparoscopic curative resections. All of these combinations allow a minimal invasive approach for lesions that would otherwise necessitate a laparotomy [7, 8, 14–17].

This study is hindered by lack of control of endoscopists’ criteria for unresectability, small patient number.

The role of HALS colectomy for cancer has been confirmed to be as oncologically appropriate as open colectomy if anatomic principles for oncologic resection are followed [12, 13].

Conclusion

Large colonic polyps unresectable at colonoscopy are associated with a high rate of unsuspected cancer and these polyps require a formal oncologic colectomy rather than transcolonic polypectomy. HALS colectomy offers a safe and effective means of eradicating these polyps with the benefits of early postoperative recovery.

REFERENCES

1. Xu K, Liang X, Cui D, Wu Y, Shi W, Liu J. miR-1915 inhibits Bcl-2 to modulate multidrug resistance by increasing drug-sensitivity in human colorectal carcinoma cells. *Mol Carcinog* 2013; 52:70-78. doi: 10.1002/mc.21832.
2. Vogelstein B, Fearon ER, Hamilton SR, Kern SE, Preisinger AC, Leppert M, Smiths AMM, Bos JL. Genetic alterations during colorectal-tumor development. *N Engl J Med* 1988; 319:525–532. doi:10.1056/NEJM198809013190901.
3. Cho KR, Vogelstein B. Genetic alterations in the adenoma-carcinoma sequence. *Cancer* 1992; 70:1727–1731. doi:10.1002/1097-0142(19920915)70:4+<1727::AID-CNCR2820701613>3.0.CO;2-P.

4. Monkemuller K, Neumann H, Malfertheiner P, Fry LC. Advanced colon polypectomy. *Clin Gastroenterol H* 2009; 7:641–652 doi:10.1016/j.cgh.2009.02.032.
5. Wasif N, Etzioni D, Maggard MA, Tomlinson JS, Ko CY. Trends, Patterns, and Outcomes in the management of malignant colonic polyps in the general population of the United States. *Cancer* 2011; 117:931–937. doi:10.1002/cncr.25657.
6. Winter H, Lang RA, Spelsberg FW, Jauch KW, Huttl TP. Laparoscopic colonoscopic rendezvous procedures for the treatment of polyps and early stage carcinomas of the colon. *Int J Colorectal Dis* 2007; 22:1377–1381. doi:10.1007/s00384-007-0345-4.
7. Hauenschild L, Bader FG, Laubert T, Czymek R, Hildebrand P, Roblick UJ, Bruch HP, Mirow L. Laparoscopic colorectal resection for benign polyps not suitable for endoscopic polypectomy. *Int J Colorectal Dis* 2009; 24:755–759 doi:10.1007/s00384-009-0688-0.
8. Pokala N, Delaney CP, Kiran RP, Brady K, Senagore AJ. Outcome of laparoscopic colectomy for polyps not suitable for endoscopic resection. *Surg Endosc* 2007; 21:400–403. doi:10.1007/s00464-006-9069-8.
9. Lai JH, Ng KH, Ooi BS, Ho KS, Lim JF, Tang CL, Eu KW. Laparoscopic resection for colorectal polyps: a single institution experience. *ANZ J Surg* 2011; 81:275–280 doi:10.1111/j.1445-2197.2010.05580.x
10. Waye JD. How big is too big? *Gastrointest Endosc* 1996; 43:256–257. [http://dx.doi.org/10.1016/S0016-5107\(96\)70329-2](http://dx.doi.org/10.1016/S0016-5107(96)70329-2).
11. Nassiopoulos K, Pavlidis TE, Menenakos E, Chanson C, Zografos G, Petropoulos P. Laparoscopic colectomy in the management of large, sessile, transformed colorectal polyps. *JSLS* 2005; 9:58–62.
12. Jang JH, Balik E, Kirchoff D, Tromp W, Kumar A, Grieco M, Feingold DL, Cekic V, Njoh L, Whelan RL. Oncologic colorectal resection, not advanced endoscopic polypectomy, is the best treatment for large dysplastic adenomas. *J Gastrointest Surg* 2012; 16:165–172. doi:10.1007/s11605-011-1746-9.
13. Loungnarath R, Mutch MG, Birnbaum EH, Read TE, Fleshman JW. Laparoscopic colectomy using cancer principles is appropriate for colonoscopically unresectable adenomas of the colon. *Dis Colon Rectum* 2010; 53:1017–1022 doi:10.1007/DCR.0b013e3181df0b8f.
14. Wilhelm D, von Delius S, Weber L, Meining A, Schneider A, Friess H, Schmid RM, Frimberger E, Feussner H. Combined laparoscopic–endoscopic resections of colorectal polyps: 10-year experience and follow-up. *Surg Endosc* 2009; 23:688–693. doi:10.1007/s00464-008-0282-5.
15. Itah R, Greenberg R, Nir S, Karin E, Skornick Y, Avital S. Laparoscopic surgery for colorectal polyps. *JSLS* 2009; 13:555–559. doi:10.4293/108680809X12589998404407.
16. Franklin Jr. ME, Leyva-Alvizo A, Abrego-Medina D, Glass JL, Trevino J, Arellano PP, Portillo G. Laparoscopically monitored colonoscopic polypectomy: an established form of endoluminal therapy for colorectal polyps. *Surg Endosc* 2007; 21:1650–1653. doi:10.1007/s00464-007-9237-5.
17. Cruz RA, Ragupathi M, Pedraza R, Pickron TB, Le AT, Haas EM. Minimally invasive approaches for the management of “difficult” colonic polyps. *Diagn Ther Endosc*. doi:10.1155/2011/682793.