

Fibro-osseous lesions of craniofacial bones in children: case reports

Rasa Aurelija Vankevičiūtė¹,

Arijanda Neverauskienė²,

Evaldas Lukoševičius³

¹Medical Faculty of Vilnius University

²Department of Radiology,
Children's Hospital,
Affiliate of Vilnius University
Hospital Santariskiu Clinics

³Department of Surgery,
Children's Hospital,
Affiliate of Vilnius University
Hospital Santariskiu Clinics

Background. The aim of this article is to present rare clinical cases of craniofacial fibro-osseous lesions in pediatric patients.

Materials and methods. In this report we present 3 cases of fibro-osseous craniofacial lesions in pediatric patients. Lesions of bones resembled fibrous dysplasia, dysplastic fibroma and chronic osteomyelitis which were confirmed or suspected by clinical signs, radiographic visualization methods and histopathological investigations for these patients. The diagnostic workup, treatment, follow-up procedures and a literature review are presented.

Results and conclusions. Fibro-osseous lesions of the jaws and skull manifest in a similar pattern. Conditions are easily revealed upon examination and with the help of conventional diagnostics, however, differential diagnosis using only radiological imaging is impossible. Histological findings remain a tool of choice determining the treatment strategy and outcome of the patients but it is not always available due to anatomical and functional considerations. Treatment of fibro-osseous lesions of the face and skull is highly individualized and depends on various qualities of the lesion and the patient himself. All patients received palliative symptomatic treatment to alleviate their conditions and in all cases obtaining a histology specimen and surgical intervention for treatment of the lesion was considered as a treatment option only if it was seen being safe and as least traumatic as possible because of the functional and psychological importance of the craniofacial region.

Key words: craniofacial fibro-osseous lesions, fibrous dysplasia, chronic osteomyelitis

INTRODUCTION

A diverse group of osseous disorders including hereditary or developmental lesions, reactive or

dysplastic diseases and neoplasms have been described as benign fibro-osseous lesions. Being listed as rare diseases, they pose a challenge to clinicians when making right diagnosis and choosing treatment methods for their patients.

Pathognomonic symptoms do not exist and their occurrence is mostly insidious. The main clinical symptoms are swelling and enlargement

Correspondence to: Arijanda Neverauskienė, Department of Radiology, Children's Hospital, Affiliate of Vilnius University Hospital Santariskiu Clinics, Santariškių 7, LT-08406 Vilnius, Lithuania. E-mail: arijandaneverauskiene@yahoo.com

of the affected area due to deformation of the involved bone, which leads to impaired function psychological and cosmetic problems.

Radiologic findings are unspecific and are only a suggestion what group of bone affecting diseases a clinician has encountered.

The aim of our publication is to present three cases of rare craniofacial lesions that we encountered in our practice.

Case No. 1

A 9-year old Caucasian male patient arrived with complaints of a painless tumor in the retroauricular area. Upon examination a bony tumor measuring $5.0 \times 6.0 \times 2.0$ cm was diagnosed arising from the

temporal bone. CT revealed a tumor involving the left temporal-parietal-occipital area and spreading to the pyramid (Fig. 1). Density of the tumor resembled one of the fibrous tissue. No intracranial changes were found. The patient was observed for 4 years. Growth of the tumor was very slow. Biopsy showed the fibrous tissue with few bone trabecules and active osteoblasts at their margins. Diagnosis of fibrous dysplasia was confirmed (Fig. 2).

Conservative treatment was suggested because of high risk of surgical intervention. As the tumor increased in size, the patient was eventually operated. Partial extirpation of the tumor together with the temporal squama and a part of the pyramid was performed to achieve optimal tumor mass

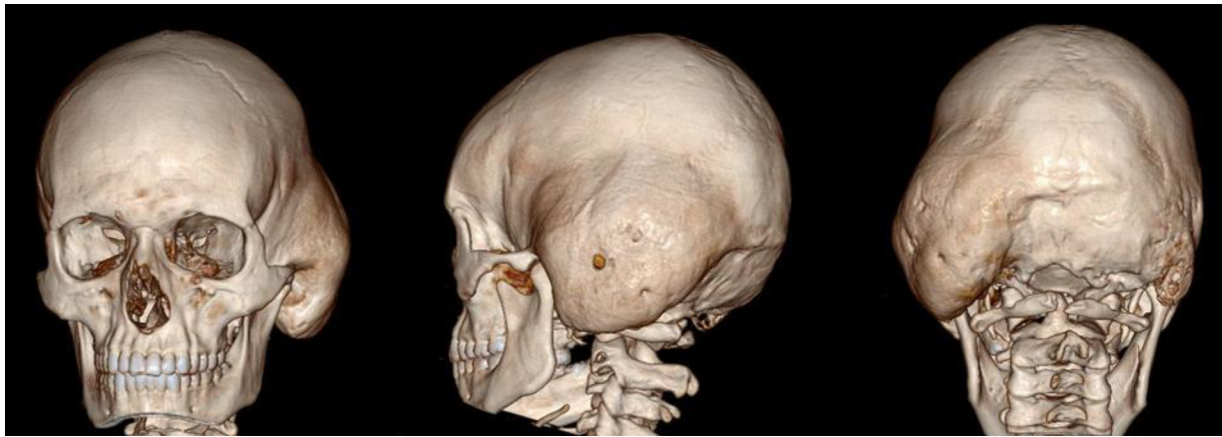

Fig. 1. CT 3D reconstructions demonstrate enlargement of the left temporal-parieto-occipital region

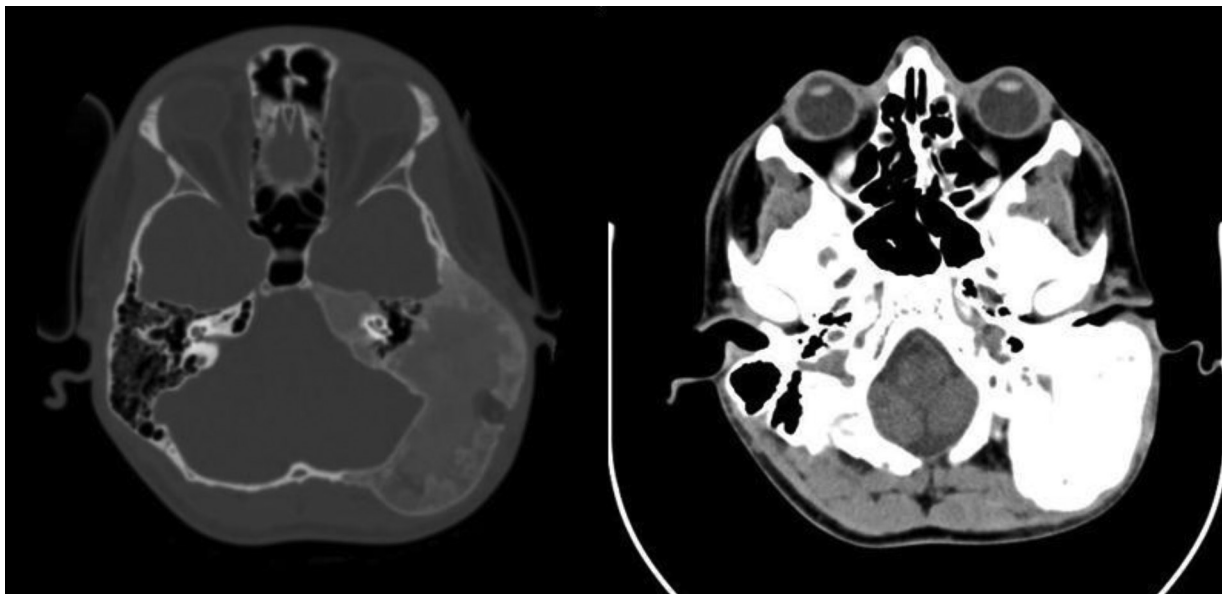


Fig. 2. CT axial images demonstrate fibrous dysplasia involment of the left cranial base. The pathognomonic appearance is the homogenous “ground-glass”, increased density of involved bones

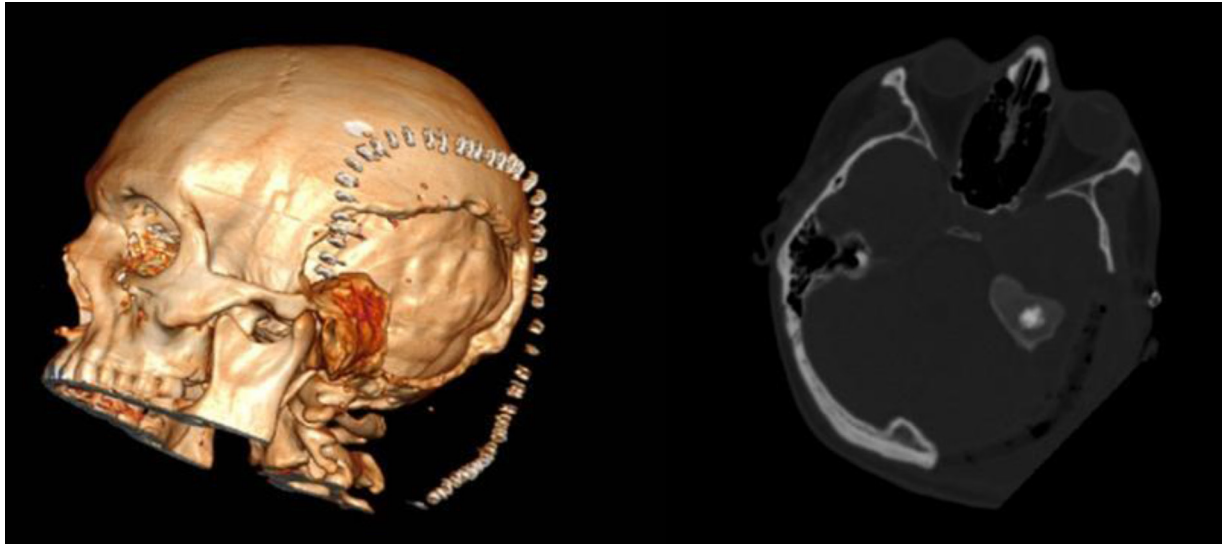


Fig. 3. 3D reconstruction and axial images after the operation

reduction and avoid damage to nearby structures. The defect was filled with acrylic bone cement. Postsurgical hearing disturbances (humming in the left ear) were noted. The patient is continued to be followed (Fig. 3).

Case No. 2

A 12-year old Caucasian female patient arrived with complaints of swelling in the right eyebrow area and persisting headache for about 4 months. Detailed examination revealed an osseous lesion in the frontal bone, approximately 6.3×3.2 cm. After histological examination, Langerhans histiocytosis was diagnosed and adequate treatment with vinblastine and corticosteroids was administered. Full remission was achieved.

After 5 months the patient started complaining of sharp pain in the right parotidomasseteric region with episodes of swelling, limited mouth opening and subfebrile temperature. She received treatment with ampicillin and cefuroxim. Swelling subsided but pain remained. The patient was hospitalized for detailed examination to the Department of Oncohematology. Local painful swelling was observed in the right m. masseter region. Skin showed no signs of inflammation. Regional lymphatic nodes were normal. Spiral CT scan showed a deformed and enlarged right ramus of the mandible with local areas of radiolucency and uneven osteosclerosis resembling chronic osteomyelitis (Figs. 4, 5). Incisional biopsy was taken from the bone destruction lesion on the lateral

side of the ramus through intraoral approach. The fibrous tissue with focal reactive osteogenesis was found. Histiocytosis was excluded. Microbiological swab test showed growth of *Str. oralis*. During the inpatient treatment period a combination of antibiotics ceftazidim, amikacin, metronidazole and vancomycin was administered together with NSAID. At the end of the treatment course pain subsided. The patient was discharged from hospital and only a slight swelling and subfebrile temperature remained.

During the next nine months, episodes of exacerbated pain, swelling and subfebrile fever occurred. The patient used nonsteroidal anti-inflammatory drugs during these exacerbation periods.

After another nine months, follow-up examination was performed. Spiral CT showed that deformation in the right ramus remained without any change in volume (Fig. 6). In axial CT and MIP reconstructions there were no destruction alterations like in the first CT examination. The cortex of the affected ramus was well defined, the structure of the bone was more sclerotic. Histopathological analysis of the second biopsy tissue described fibrous structural changes of the bone with reactive osteogenesis. The tumor and histiocytosis were excluded.

Antimicrobial, anti-inflammatory and steroid treatment was prescribed. Symptomatic treatment alleviated the condition but full remission was not achieved.

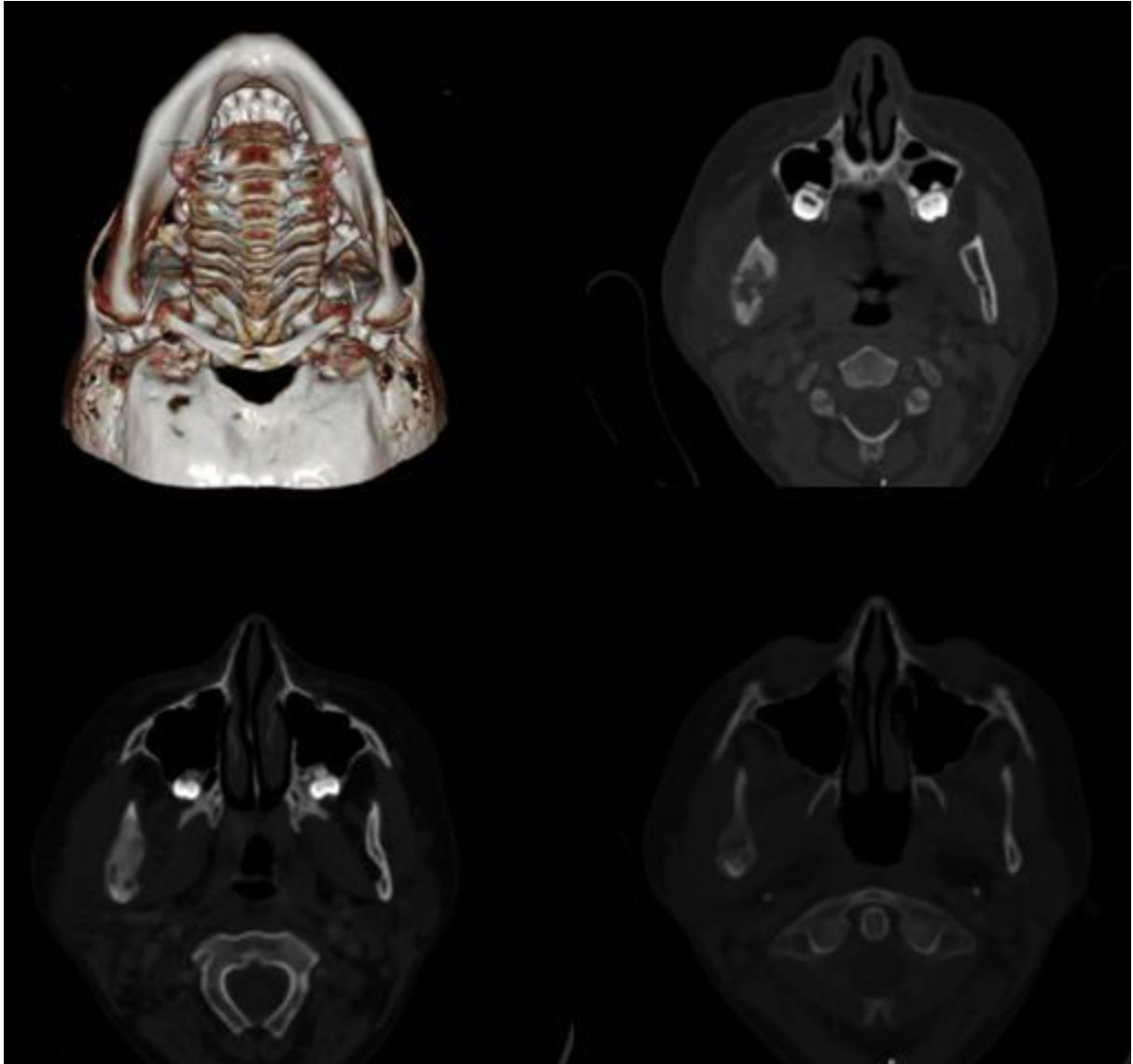


Fig. 4. 3D reconstruction shows enlargement of the right angle, ramus, and condylar process of the mandible. Axial cranial CT sections show mixed lesions described as “ground-glass”, “cystic”, “pagetoid” or “lytic” and involving the right ramus of the mandible together with the condyle and coronoid process

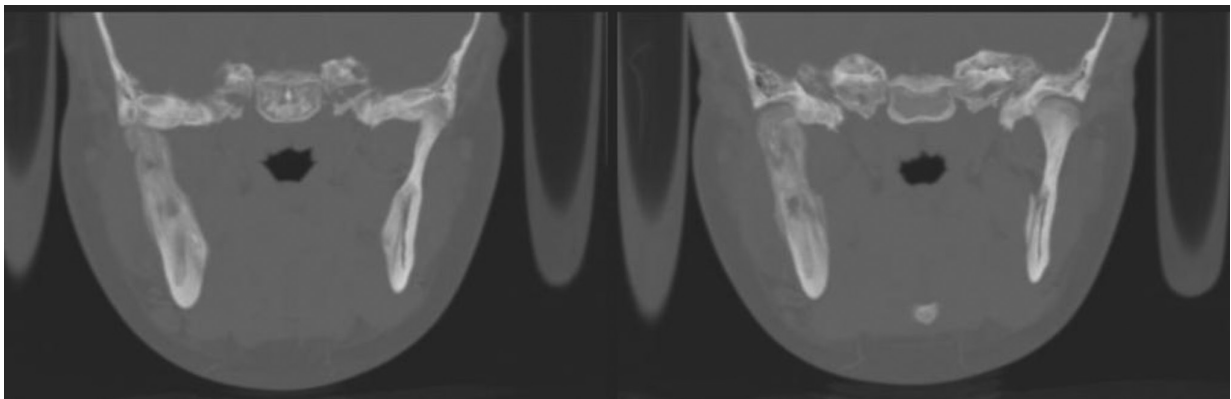


Fig. 5. Coronal MIP reconstructions show mixed lesions described as “ground-glass”, “cystic”, “pagetoid” or “lytic” and involving the right ramus of the mandible together with the condyle and coronoid process

Additionally, scintigraphy and MRI scans showed inflammatory changes in the right mandible angle and ramus. Because of that conservative treatment was continued with diclofenac, ranitidine, depakine and prednisolone.

The patient is being followed, and conservative therapy is chosen for managing her symptoms.

Case No. 3

A 9-year old Caucasian female patient arrived with complaints of pain in her right foot. Detailed examination and x-ray imaging diagnosed a tumor in the 5th finger of the right foot. The tumor was removed. The pathology result was desmoplastic fibroma.

After few months the patient arrived to the Maxillofacial Surgery Department with complaints

of swelling and pain in the right angle of the mandible.

Face asymmetry due to the deformed mandible and swelling of the surrounding tissue was observed (Fig. 7). Intraorally painless deformation of the right side of the mandible body was palpated. In panoramic x-ray signs of osteolysis and reduced density were observed.

Surgical treatment was chosen. The softened bone was removed and curettage of remaining walls was performed in the area from teeth 46 to 42. The alveolar nerve was released from its bone canal and lateralized. Histological analysis described tumor like tissue in fragments of the removed bone comprising of spindle like cells, with oval monomorphic nuclei and collagen fibers, together with bone trabecules surrounded by osteoblasts.

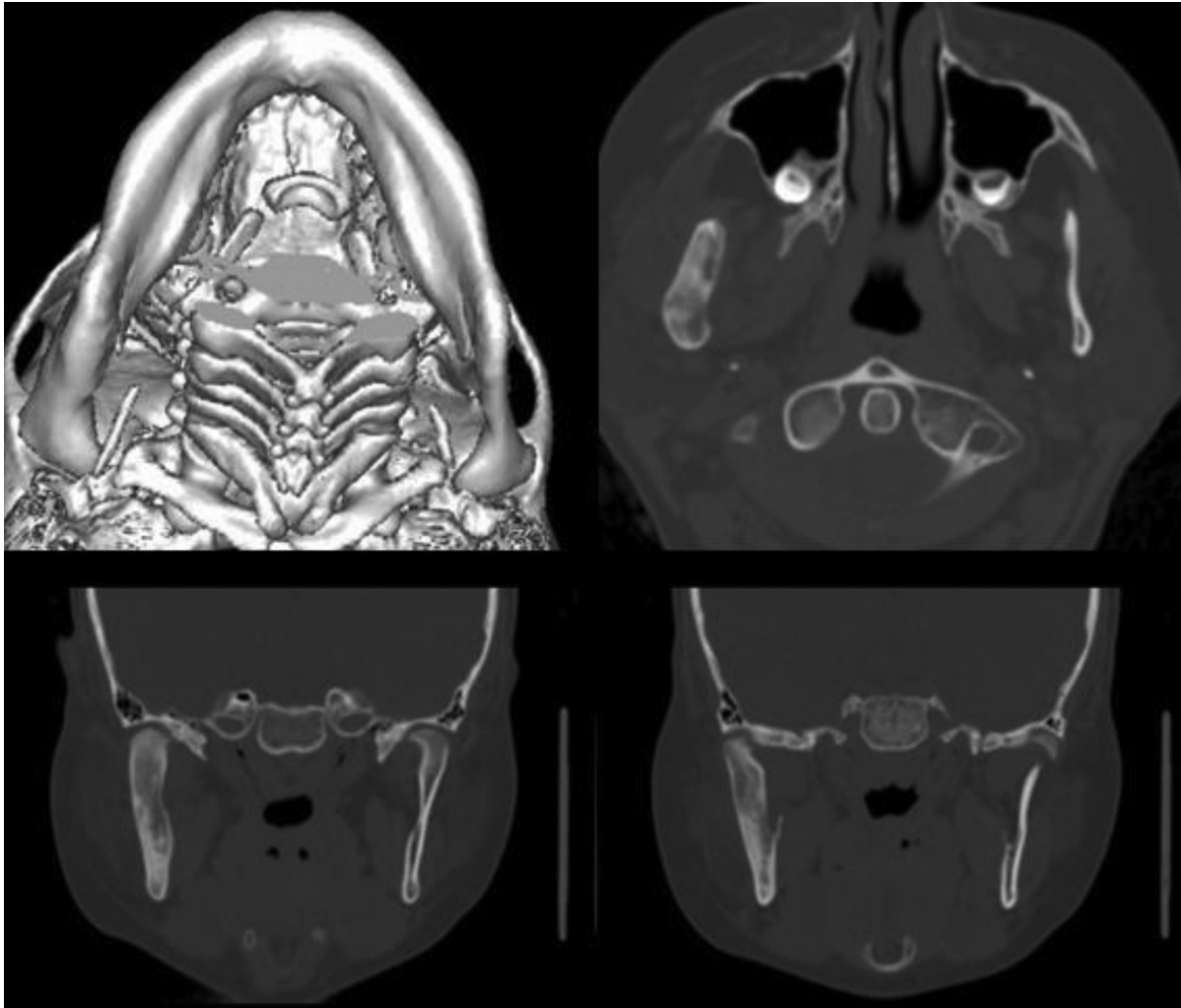


Fig. 6. 3D reconstruction of the affected right ramus shows stable deformation with no additional increase in volume. CT axial images and coronal MIP reconstructions demonstrate a more homogenous appearance of the “ground-glass” view with sclerotic surroundings, less “lytic” lesions

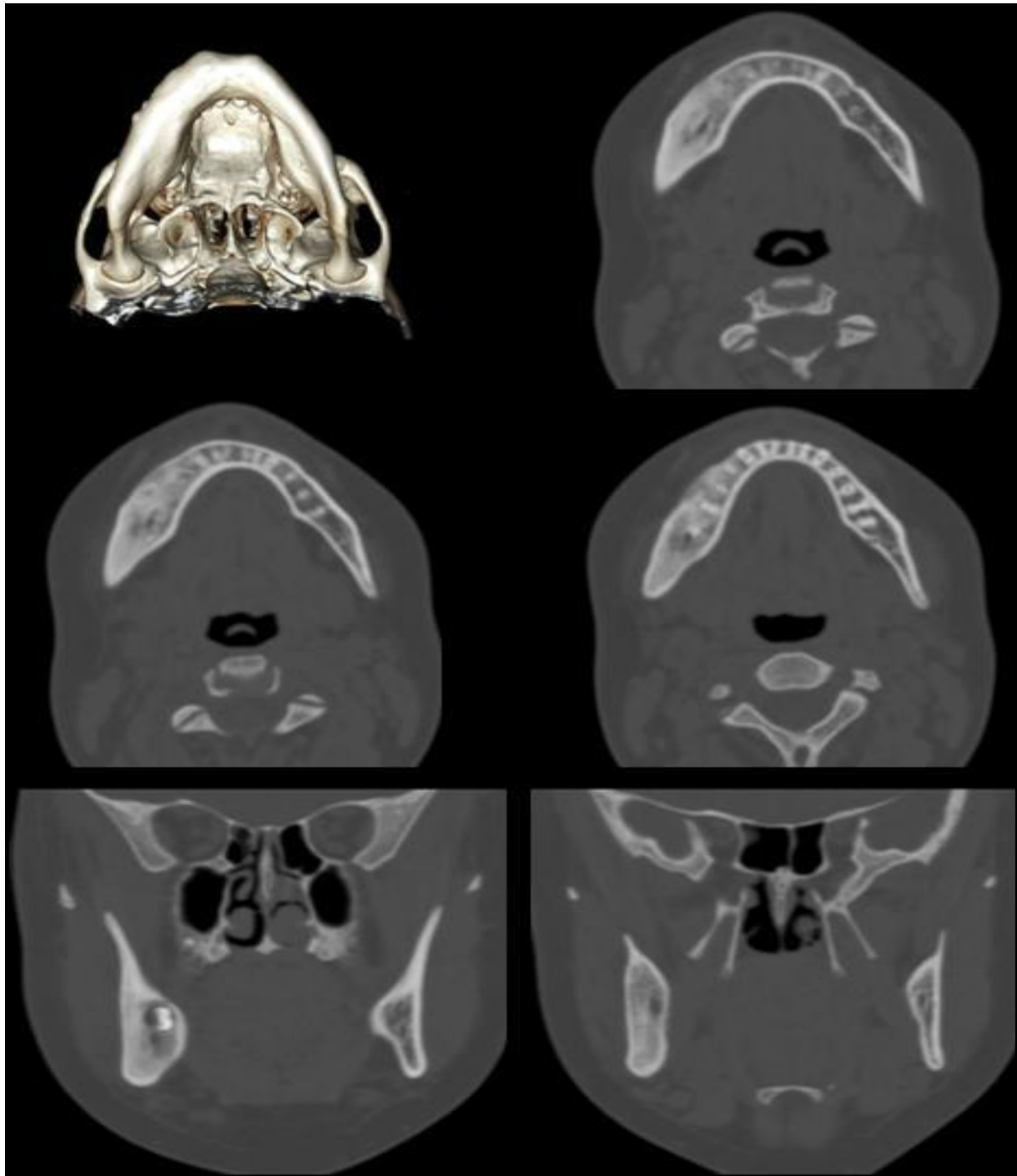


Fig. 7. 3D model reconstruction shows asymmetry due to the expanded right ramus and the body of the mandible. CT axial views and coronal MIP reconstructions demonstrate lesions typical neither for FD nor chronic osteomyelitis. The mixed appearance is like “ground-glass” with proliferative periostitis and small “lytic” lesions

Intratrabecular spaces filled with low cell tumor tissue. Diagnosis of the desmoplastic fibroma of the mandible was established.

Postoperative antibiotics and analgesics were administered. Healing was uneventful and the patient was discharged from hospital.

After 2 months recurrence of the tumor was noticed. The patient was observed for 3 more months. As deformation due to the bone expansion increased, the second surgery was performed. The area of excision and curettage remained in boundaries of the previous lesion. The mental nerve was

sacrificed. Histological analysis of the removed tissue showed residual reactive inflammatory changes.

The third biopsy was taken in Germany 10 months after the second operation due to recurrent inflammatory reactions in the mandible area. No microbial growth was found. Histological and clinical signs suggested a diagnosis of chronic recurrent multifocal osteomyelitis. Naproxen was prescribed, but only with very slight improvement in patient's condition. Additionally, prednisolone was prescribed.

Up to this moment the patient experiences episodes of pain and swelling. Treatment attempt with bisphosphonates (pomedronate) gave adverse reactions and was discontinued. Continuous treatment with naproxen is maintained.

Recent follow-up CT scan revealed changes in the bone similar to FD but chronic osteomyelitis could not be excluded.

DISCUSSION

Depending on the type and location of a fibro-osseous lesion, the signs and symptoms may vary from only a slight asymmetry of the facial contour to a large deformity with impairment or complete loss of the function of the affected structure. Pain is the most common symptom. In cases of fibrous dysplasia pain is reported by 67% of population, but more prevalent and severe in adults than in children (1). Many patients are asymptomatic and diagnosis is made only when a family member, friend or health care provider who has not seen the patient for a period of time notices asymmetry, or there is an incidental abnormality noted on radiograms or CT (2).

Clinical cases presented from our hospital demonstrate diverse manifestations of fibro-osseous lesions of craniofacial bones. Though easily revealed because of specific clinical signs, they presented clinicians with a difficult task of differentiating the right diagnosis. Radiological examination and biopsy are commonly used to solve this problem but in our practice we encountered difficulties in establishing correct diagnosis as well as choosing treatment options for the patients.

As radiologic features of the lesions resembled fibrous dysplasia as well as chronic osteomyelitis, below we present a comparison of radiological signs of these conditions (3, 4, 5, 7).

Chronic osteomyelitis radiographic signs vary depending on the intensity of inflammatory processes and patient's age. Lytic lesions, sclerosis of the surrounding bone, radiopaque sequestra of dead bone are seen in the place of bone destruction. Process in contact with periosteum produces periosteal thickening (like proliferative periostitis in children). CT scans and MRI are more sensitive and specific modalities that provide more information.

Chronic osteomyelitis signs in CT are blurring of fat planes, increased density of fatty marrow, periosteal reaction, cortical erosion or destruction, sequestra, involucra and intraosseous gas.

MRI data is more sensitive for determination of stages of osteomyelitis (acute, subacute, chronic). T1 and T2 weighted images show low signal intensity areas of devascularised, fibrotic scarring in the marrow.

Fibrous dysplasia in conventional radiograms is seen as radiolucent, smoky, cloudy, "ground glass", finger print forms or diffuse sclerosis of variable size that are gradually becoming opaque especially with the age of the patient.

Fibrous dysplasia findings in CT are lesions with poorly defined borders, an irregular bony trabeculae of woven bone like "ground glass", increased density of the involved bone, displacement of the adjacent structures, complete obliteration of facial sinuses, cortical thinning of the involved bone.

Fibrous dysplasia in MRI T1 weighted images is isointense to the skeletal muscle. In T2 weighted images lesions are heterogeneously hyperintense with hypo-, iso- or hyper- areas due to calcifications, cysts, septations of fatty tissue. MRI features are not the same as those characteristic of real fibrous tissue, which is hypointense to the skeletal muscle in T1 and T2 weighted images. The benefit of MRI is better visualization of lesions location and it complements other radiographic images.

Conventional X-ray is mostly the first diagnostic tool: not expensive, reiterative, available in all clinics. Cross-sectional modalities (CT) and magnetic resonance imaging (MRI) are more sensitive and specific modalities that provide more information (6).

Histology samples revealed that there is a subjective interpretation factor. A pathologist examining biopsy material may give inaccurate evaluation (7). In addition to this, fibro-osseous

lesions in children may have various deviations in radiological signs and clinical behavior because of the pubescence hence making differential diagnostics and treatment planning even more complicated.

When choosing the treatment method for any fibro-osseous lesion in the craniofacial area it is important to know that each patient may present with variable symptoms and clinical findings, thus the care of these patients must be customized to their needs and sites of involvement (2). Some authors suggest that early surgical resection of scalp and skull masses for pediatric patients may lead to a more friendly prognosis (8). Others advocate more conservative treatment. In some cases of fibrous dysplasia treatment with bifosfonates was considered (9). Surgical intervention should be a method of choice if desmoplastic fibroma is diagnosed as it is an aggressively acting tumor. Resection is suggested if the tumor is operable and radiotherapy is recommended as an alternative for an inoperable desmoplastic fibroma (10). Cases of primary chronic osteomyelitis of the jaws present both diagnostic and therapeutic challenge, especially in young patients. Surgical treatment in conjunction with antibiotics and non-steroid anti-inflammatory drugs proved to be beneficial, considerably improving patient's quality of life. Nevertheless, exacerbation of symptoms may appear and regular follow-up of the patients is required (11).

In light of such variable conditions treatment of craniofacial fibro-osseous lesions remains highly individualized and is based on features of the lesion and patient's qualities.

CONCLUSIONS

Fibro-osseous lesions of the jaws and skull manifest in a similar pattern. Conditions are easily revealed upon examination and with the help of conventional diagnostics, however, differential diagnosis using only radiological imaging is impossible. Histological findings remain a tool of choice determining the treatment strategy and outcome of the patients but it is not always available due to anatomical and functional considerations. Treatment of fibro-osseous lesions of the face and skull is highly individualized and depends on various qualities of the lesion and the

patient himself. All patients received palliative symptomatic treatment to alleviate their conditions and in all cases obtaining a histology specimen and surgical intervention for treatment of the lesion was considered as a treatment option only if it was seen being safe and as least traumatic as possible because of the functional and psychological importance of the craniofacial region.

Received 26 May 2013

Accepted 27 June 2013

References

1. Kelly MH, Brillante B, Collins MT. Pain in fibrous dysplasia of bone: age-related changes and the anatomical distribution of skeletal lesions. *Osteoporos Int.* 2008; 19(1): 57–63.
2. Lee JS, FitzGibbon EJ, Chen YR, Kim HJ, Lustig LR, Akintoye SO, et al. Clinical guidelines for the management of craniofacial fibrous dysplasia. *Orphanet J Rare Dis.* 2012; 7 Suppl 1: S2.
3. Sontakke SA, Karjodkar FR, Umarji HR. Computed tomographic features of fibrous dysplasia of maxillofacial region. *Imaging Sci Dent.* 2011; 41(1): 23–8.
4. Whaites EC, Cawson RA. *Essentials of Dental Radiography and Radiology.* 4th ed. Churchill Livingstone; 2007. p. 434–5.
5. Pineda C, Espinosa R, Pena A. Radiographic imaging in osteomyelitis: the role of plain radiography, computed tomography, ultrasonography, magnetic resonance imaging, and scintigraphy. *Semin Plast Surg.* 2009; 23(2): 80–9.
6. Shah ZK, Peh WC, Koh WL, Shek TW. Magnetic resonance imaging appearances of fibrous dysplasia. *Br J Radiol.* 2005; 78(936): 1104–15.
7. McCarthy EF. Fibro-osseous lesions of the maxillofacial bones. *Head Neck Pathol.* 2013; 7(1): 5–10.
8. Yoon SH, Park SH. A study of 77 cases of surgically excised scalp and skull masses in pediatric patients. *Childs Nerv Syst.* 2008; 24(4): 459–65.
9. Makitie AA, Tornwall J, Makitie O. Bisphosphonate treatment in craniofacial fibrous dysplasia – a case report and review of the literature. *Clin Rheumatol.* 2008; 27(6): 809–12.
10. Sandrini FA, do Egito Vasconcelos BC, Bessa-Nogueira RV. Desmoplastic fibroma of mandible

in a child: case report. *Indian J Surg.* 2007; 69(6): 254–6.

11. Theologie-Lygidakis N, Schoinohoriti O, Iatrou I. Surgical management of primary chronic osteomyelitis of the jaws in children: a prospective analysis of five cases and review of the literature. *Oral Maxillofac Surg.* 2011; 15(1): 41–50.

Rasa Aurelija Vankevičiūtė, Arijanda Neverauskienė, Evaldas Lukoševičius

FIBROZINIAI VAIKŲ VEIDO KAULŲ PAŽEIDIMAI. KLINIKINIŲ ATVEJŲ PRISTATYMAS

Santrauka

Tikslas. Pristatyti retus vaikų veido fibroziųjų kaulų pažeidimų atvejus.

Medžiaga ir metodai. Šiame straipsnyje pateikiame tris klinikinius vaikų veido ir galvos kaulų fibroziųjų pažeidimų atvejus. Išskirti šie susirgimai: fibrozinė displazija, displastinė fibroma ir lėtinis osteomielitas. Diagnozės kryptingai tirtos remiantis klinikiniu vaizdu,

radiologiniais ir histologiniais tyrimais. Aprašyta šių pacientų ištyrimo eiga, gydymas ir gydymo rezultatai, kartu pateikta literatūros apžvalga.

Rezultatai ir išvados. Fibroziniai veido kaulų pažeidimai pasižymi labai panašia klinika. Nors pacientų būklę lengva nustatyti apžiūros metu ar įprastais tyrimo metodais, tačiau diferencinei diagnostikai nepakanka vien tik radiologinių tyrimų. Histologinis audinių ištyrimas yra pagrindinė priemonė, padedanti nustatyti diagnozę, pasirinkti gydymo metodą ir prognozuoti ligos eigą, tačiau ji ne visuomet yra tinkama dėl veido ir galvos anatominių ir funkcinių aspektų. Veido kaulų fibroziųjų pažeidimų gydymas yra labai individualus ir priklauso nuo daugelio veiksnių (pažeidimo vietos, srities funkcinių ypatumų, paciento būklės). Visi pacientai buvo gydomi simptomiškai siekiant pagerinti savijautą, o chirurginis gydymas pasirinktas tik tuomet, kai intervencija buvo maksimaliai saugi ir mažiausiai žalojanti.

Raktažodžiai: veido kaulų fibroziniai pakitimai, fibrozinė displazija, lėtinis osteomielitas

