

# Management of acquired benign tracheoesophageal fistula in adults: a twelve-year experience

## Įgytos tracheozofaginės jungties gydymas: dvylikos metų patirtis

Nerijus Šileika, Vytautas Jovaišas, Žymantas Jagelavičius, Ričardas Janilionis

*Centre of General Thoracic Surgery, Vilnius University, University Hospital "Santariskiu Klinikos", Santariskiu Str. 2, LT-8661 Vilnius, Lithuania*

*E-mail: nerijus01sil@yahoo.com*

*Tel. 00 370 625 48 430; Fax 00 370 5 2611636*

---

### Background / Objectives

Acquired nonmalignant tracheoesophageal fistula (TEF) in adult patients develops in a variety of conditions, the predominant being postintubation. Several management options have been suggested, while the optimal strategy remains controversial. The aim of this review is to present our clinical experience and to find the optimal management for TEF.

### Methods

This study is a retrospective review of all patients who underwent management for benign TEF at the Vilnius University Hospital between January 2000 and December 2012.

### Results

Seven patients (three female and four male) with a benign TEF were referred to the Department of General Thoracic Surgery of the Vilnius University Hospital from January 2000 to December 2012. Their mean age was  $48.3 \pm 11.4$  years. Postintubation TEF accounted for six fistulas (85.7%), while one patient (14.3%) suffered from injury during percutaneous dilational tracheostomy. Five patients underwent TEF closure (71.4%). Four patients underwent a simple repair of the fistula, while one patient required tracheal resection and reconstruction. Endoscopic management with tracheal dilation and T tube placement was performed to one (14.3%) and additional jejunostomy was done also to one patient (14.3%). Four patients (57.1%) had postoperative complications. Two postoperative deaths occurred (28.6%).

### Conclusions

Single-stage surgical repair with or without tracheal resection and reconstruction can be successfully performed after the weaning from mechanical ventilation in patients with acquired nonmalignant TEF.

**Key words:** tracheoesophageal fistula, surgical closure, tracheal resection, nonmalignant fistula

---

### Įvadas / tikslas

Įgytos nenavikinės kilmės tracheozofaginės jungties (TEJ) priežastys yra įvairios, dažniausia iš jų – pointubacinė. Yra pasiūlyta keletas gydymo metodų, tačiau dėl geriausios gydymo taktikos vis dar diskutuojama. Šios apžvalgos tikslas – išnagrinėti mūsų klinikinę patirtį ir rasti optimalų gydymą tų ligonių, kuriems nustatyta TEJ.

## Metodai

Retrospektyviai išanalizuoti ligoniai, kurie 2000–2012 m. buvo chirurginiu būdu gydomi Vilniaus universiteto ligoninės Krūtinės chirurgijos skyriuje.

## Rezultatai

2000–2012 m. nuo nenavikinės kilmės TEJ gydyti 7 ligoniai (3 moterys ir 4 vyrai), kurių amžiaus vidurkis buvo  $48,3 \pm 11,4$  metų. Pointubacinė TEJ nustatyta šešiams ligoniams (85,7 %), vienam ligoniui (14,3 %) TEJ atsirado po perkutaninės dilatacinės tracheostomijos. Penki ligoniai gydyti chirurginiu būdu (keturiems ligoniams trachėja atskirta nuo stemplės, o jų sienų defektai užsiūti; vienam ligoniui papildomai atlikta trachėjos rezekcija ir rekonstrukcija). Endoskopinis trachėjos spindžio plėtimas ir stentavimas T formos endoprotezu taikytas vienam ligoniui (14,3 %); maitinimui skirta jejunostoma atlikta taip pat vienam ligoniui (14,3 %). Keturiems ligoniams pasitaikė pooperacinių komplikacijų (57,1 %). Po gydymo mirė du ligoniai.

## Išvada

Vienmomentė TEJ šalinimo operacija su trachėjos rezekcija ir rekonstrukcija arba be jos gali būti sėkmingai atlikta savaime kvėpuojantiems ligoniams, kuriems yra nenavikinės kilmės TEJ.

**Reikšminiai žodžiai:** tracheozofaginė jungtis, trachėjos rezekcija, nenavikinės kilmės jungtis.

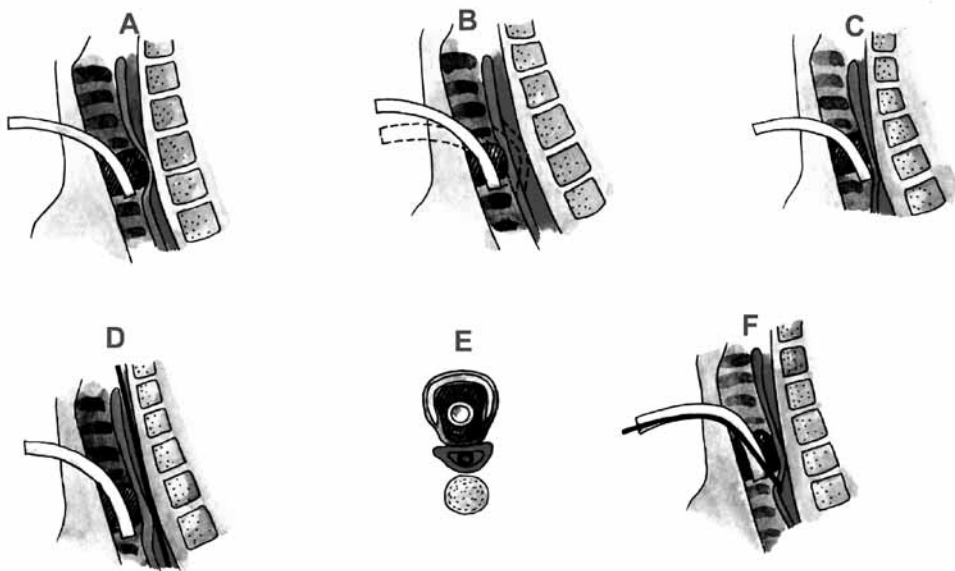
## Introduction

Tracheoesophageal fistula (TEF) can be either congenital or acquired.

A congenital fistula between the trachea and the esophagus results from a failure of tracheoesophageal separation during the early stage of embryonic development. It is usually associated with esophageal atresia and occurs in about 1 of 3.500 births. In 1953, Gross published an anatomical classification of congenital

anomalies of the esophagus and the trachea. The Gross-type E (i.e. H-type fistula), without accompanying esophageal atresia, is a rare anomaly (4.2% in congenital TEF) which is usually diagnosed in adults [1, 2].

The acquired type of TEF might be caused by either malignancy or a host of nonmalignant entities. TEF from malignancy accounts for more than 50% of acquired TEFs. The primary tumor location is usually the esophagus (78%), but it can also be the lung (16%), trachea, larynx, thyroid and lymph nodes [3, 4, 5].



**Fig 1.** Risk factors of TEF. A – overinflation of tracheostomy cuff, B – excessive motion of the tracheostomy tube, C – the tip of tracheostomy tube directly touching the posterior wall of trachea, D, E – tracheostomy cuff exerted against a firm nasogastric tube, F – repeated aspiration injuries

Etiologic factors accounting for acquired benign TEFs include postintubation injuries, blunt and penetrating trauma, granulomatous mediastinal infections, prior esophageal surgery, prior tracheal or laryngeal surgery, iatrogenic injuries, indwelling stents, and AIDS [3, 5, 6, 7, 8]. With the widespread use of cuffed tubes for ventilation, postintubation TEFs became predominant. Although the first tracheostomy tube with an inflatable cuff had been described by Trendelenburg in 1871, its widespread use first appeared after the introduction of intermittent positive pressure ventilation for the management of respiratory failure during the Copenhagen poliomyelitis epidemic of 1952 [9, 10]. In 1967, Flege was the first to report TEF caused by cuff-related injury in patients who had been mechanically ventilated [11]. A postintubation TEF results from overinflation of the ventilatory cuff, usually exerted against a firm nasogastric tube lying in the esophagus, usually for feeding purposes (Fig. 1). Laceration injuries to the posterior wall of the trachea are another problem: these lesions are caused by a poor stabilization of the guidewire and

guiding catheter during percutaneous tracheostomy [6]. The associated risk factors involved an excessive motion of the tube, infection, hypotension, and associated tissue ischemia, steroids, diabetes, and the presence of a nasogastric tube [12]. The aim of the present study was to analyse our experience in the management of TEFs over a 12-year period and to evaluate the outcomes.

## Materials and methods

### *Patient selection*

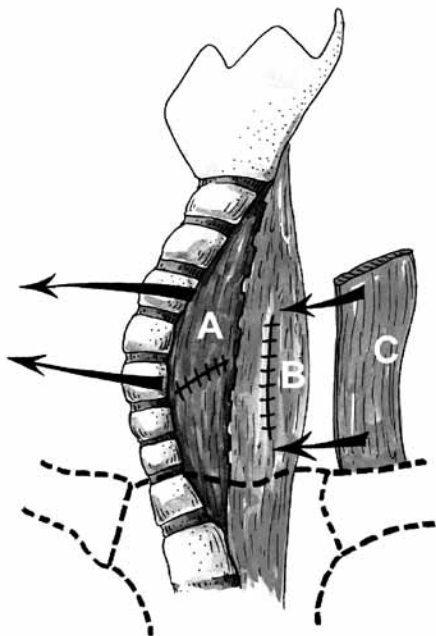
We reviewed the medical records of all patients that underwent management for benign TEF at the Department of General Thoracic Surgery of the Vilnius University Hospital between January 2000 and December 2012. There were seven patients who had been treated for a non-malignant TEF during this time span. Malignant and bronchoesophageal fistulas, including those that involved the mainstem bronchi, were excluded from the study. The medical records were reviewed for demographics, presenting symptoms, prior surgery, surgical as well as endoscopic procedures, pathology, and outcome variables. Operative mortality was defined as death that occurred during the same admission.

### *Operative or bronchoscopic management*

All the patients had been weaned from mechanical ventilation. Patient preparation entailed control of aspiration, treatment of pulmonary infection and nutrition. An inflated tracheostomy tube was positioned distal to the membranous tracheal defect. Four patients underwent a closure of the fistula without tracheal resection, while one patient underwent tracheal resection and reconstruction. In order to separate suture lines and prevent fistula recurrence, pedicled muscle flaps were always inserted between the trachea and the esophagus. Additional endoscopic management with a temporary T-tube placement was done in one case. An additional jejunostomy for feeding was performed to a patient with a poor physical condition.

### *Statistical analysis*

Descriptive statistics for categorical variables are reported as frequency and percentage while continuous variables



**Fig 2.** Main principles of TEF surgical closure. A – suture of the membranous wall of the trachea, B – suture of the esophageal defect, C – a pedicled strap muscle flap inserted between the trachea and the esophagus

are reported as mean (standard deviation) or median (range) as appropriate.

## Results

### *Patient characteristics*

There were seven patients with a benign TEF treated at the Department of General Thoracic Surgery of the Vilnius University Hospital Santariškių Klinikos during the 12-year period. Three of them were female and four were male. Their mean age was  $48.3 \pm 11.4$  years. Dysphagia on admission was found in 4, dyspnea in 4, and bronchopneumonia in 4 patients. Five patients were admitted with a tracheostomy tube. A gastrostomy tube was present in one patient and a jejunostomy tube also in one. None had a prior TEF repair at other institutions. The demographics are summarised in Table 1.

three cases (42.9%), and in one of them the trachea was stenotic at the subglottic region. The diagnosis of TEF was confirmed during bronchoscopy in all patients; esophagoscopy at our institution was applied to four patients (57.1%), and barium swallow studies had been performed in three (42.9%) cases. In one case, esophagoscopy and barium contrast studies did not reveal TEF, while bronchoscopy revealed a fistula 4 mm in length with saliva appearing in the tracheal lumen.

### *Surgical approach and operative technique*

On admission, all the patients had been weaned from mechanical ventilation. The endoscopic placement of the T tube was performed in the patient who suffered from postintubation tracheal stenosis and a tracheoesophageal fistula 4 mm in diameter. Jejunostomy was

**Table 1.** Summary of patients submitted to treatment of a tracheoesophageal fistula

Patient	Sex/age	Reason for ventilation	Tracheal stenosis	Tracheostomy	
1.	F/46	Polytrauma	No	Yes	Dyspnea / Bronchopneumonia
2.	M/34	Polytrauma	Yes	Yes	Dyspnea
3.	F/64	Myasthenia/ Peritonitis	Yes	Yes	Dyspnea / Bronchopneumonia
4.	M/50	Polytrauma	Yes	Yes	Dyspnea / Dysphagia Bronchopneumonia
5.	M/59	Peritonitis	No	No	Dysphagia
6.	F/51	Subarachnoid haemorrhage	No	No	Dysphagia
7.	F/34	Sepsis	No	Yes	Dysphagia / Bronchopneumonia

### *Etiology and anatomic characteristics of tracheoesophageal fistula*

Postintubation injury is the leading cause of TEF and is a result of a tracheal cuff inflated against a hard esophageal tube, leading to a necrosis of both membranous tracheal and esophageal walls. Postintubation TEF accounted for six fistulas (85.7%), while one patient (14.3%) suffered from esophageal injury during percutaneous dilational tracheostomy. TEF was located at the upper third of the trachea in three and in the middle part in four patients. The mean length of the fistula was 14.1 mm (range, 4–40 mm). Tracheal stenosis was diagnosed in

performed in the patient with a poor physical condition resulting from uncontrolled myasthenia gravis and multiorganic system failure. Five patients underwent a radical TEF repair. In three cases, the repair was performed using the transcervical approach. In two cases, additionally the upper partial sternotomy was performed. All the five patients underwent a single-stage repair of the fistula. Four patients (80%) underwent a simple repair, while one patient (20%) required tracheal resection and reconstruction. The esophagus was closed in two layers with interrupted 3-0 Vicryl sutures. Pedicled strap muscle flaps separated suture lines in all patients

(sternohyoid or sternothyroid muscles). Usually, the pedicle of sternohyoid muscle detached from the hyoid bone is sutured over the esophageal suture line. The membranous wall defect was closed with interrupted one-layer 3-0 Vicryl sutures. Tracheostomy was done in one patient. All the patients were extubated within 8 hours after operation.

### ***Morbidity and mortality***

Four patients (57.1%) had postoperative complications. Two postoperative deaths occurred (28.6%). One patient died after palliative surgery (a jejunostomy was performed) because of multiorgan system failure. Another death occurred after tracheoesophageal fistula repair. The postoperative period was complicated by tracheal dehiscence, mediastinitis, and finally a profuse bleeding into the tracheal lumen occurred. One patient suffered from postoperative tracheal stenosis (endoscopic tracheal dila-

tion was performed), while another had wound infection and anastomotic granulations which were successfully removed during flexible bronchoscopy. Oral intake was restored in all the patients who survived their operations. Four of 5 (80%) operative survivors breathed without a tracheal appliance, while one (20%) had a temporary T tube. The T tube was successfully removed six months after a TEF repair. The operations, complications and additional treatment are summarised in Table 2.

### **Discussion**

Over the period of 12 years, seven patients have been treated for acquired nonmalignant tracheoesophageal fistula at the Department of General Thoracic Surgery of the Vilnius University Hospital. We had five patients who underwent surgical closure of TEF in our study. Recent reports on the surgical management of TEF are shown in Table 3.

**Table 2.** Summary of patients referred to treatment of tracheoesophageal fistula

Patient	Treatment	Incision	Complications	Additional treatment
1.	Surgical repair	Cervical + upper sternotomy	Tracheal dehiscence, mediastinitis, profuse bleeding, death	
2.	Tracheal resection and reconstruction	Cervical	Wound infection, anastomotic granulations	Granulations removal during bronchoscopy
3.	Jejunostomy	Laparotomy	Multiorgan system failure, death	–
4.	T tube	2	–	–
5.	Surgical repair	Cervical + upper sternotomy	Tracheal stenosis	Tracheal recanalisation with bougies
6.	Surgical repair	Cervical	–	–
7.	Surgical repair	Cervical	–	–

**Table 3.** Recent reports on surgical management of TEF

First author	Date	Years	Patients	PITF	Redo	TRR	Pedicle flap	Recurrence	Mortality
Muniappan (9)	2013	1992–2010	36	47.0%	36.1%	61.1%	100.0%	11.1%	2.8%
Shen (10)	2010	1978–2010	21	9.5%	22.8%	8.6%	80.0%	8.6%	5.7%
Camargo (11)	2010	1992–2007	16	93.8%	18.8%	100.0%	0.0%	0.0%	0.0%
Macchiarini (8)	2000	1981–1999	32	N/A	6.3%	43.8%	N/A	3.2%	3.1%
Baisi (12)	1999	1980–1997	29	74.2%	0.0%	3.4%	92.3%	0.0%	3.4%
Mathisen (13)	1991	1975–1991	38	71.1%	21.1%	81.6%	89.5%	7.9%	10.5%

N/A = not available; pedicle flap = tracheal and esophageal repairs separated by vascularised tissue; PITF = postintubation TEF; redo = patients presenting after failed repair of TEF; TEF = tracheoesophageal fistula; TRR = repairs that required tracheal resection and reconstruction.

Postintubation TEF accounted for six fistulas (85.7%), while one patient (14.3%) suffered from injury during percutaneous dilational tracheostomy. In their study, Muniappan and colleagues [13] found the most common causes of TEFs to be postintubation injury (47%), trauma (17%), prior laryngectomy (17%), and prior esophagectomy (11%). In their study of acquired tracheoesophageal and bronchoesophageal fistulas, Shen and colleagues [14] found the most common etiologies to be prior esophageal surgery (31.4%), trauma (17.1%), granulomatous mediastinal infection (14.3%), and erosions of indwelling airway and esophageal stents (11.4%).

Most benign acquired TEFs are diagnosed while the patient is still on mechanical ventilation [3]. A sudden increase in tracheal secretions or the aspiration of gastric contents from the endotracheal tube is often the first sign of a TEF. Pulmonary infiltrates and pneumonia follow. Respiratory insufficiency may worsen. Patients who have been extubated after prolonged mechanical ventilation and develop TEF may suffer from coughing while eating and drinking (Ono's sign), dysphagia, aspiration, fever, pneumonia, hemoptysis, and chest pain. Chest X-ray commonly shows the esophagus to be dilated distal to the fistula, and the stomach may be dilated. CT can demonstrate a defect between the trachea and the esophagus. Barium swallow studies usually delineate the level and approximate size of the fistula. A swallow of water stained with methylene blue will appear in the tracheostomy. Bronchoscopy should be done promptly if a fistula is suspected. In a patient who is on a respirator, a flexible bronchoscopy may be performed through an endotracheal tube which is withdrawn just sufficiently to allow visualization of the fistula. Esophagoscopy is less likely to offer a good view, especially in cases of small fistulas. In our study, all TEFs were confirmed during bronchoscopy. In one case, esophagoscopy and barium contrast studies did not show TEF, while bronchoscopy revealed a fistula 4 mm in length.

Spontaneous healing of TEFs has not been documented, although on rare occasions a small recent traumatic fistulas may close spontaneously [5]. As most benign TEFs are diagnosed while the patient is still on mechanical ventilation, major efforts must be made to clear up a local and pulmonary infection and to improve

nutrition prior to surgical procedures. A new tracheostomy or orotracheal tube should be placed immediately, with the inflated cuff positioned below the level of the TEF in order to prevent the airway from gastric and esophageal contents. The head of the bed should be elevated to minimize gastroesophageal reflux, and suctioning from the trachea should be implemented. A gastrostomy is performed to drain the stomach and prevent reflux. At least jejunostomy is performed for feeding.

Isolated reports without a long-term follow-up advocate the initial management of nonmalignant TEF with endoluminal stents, typically in esophageal position. However, exclusion of acquired benign TEF is almost always doubtful. Eleftheriadis et Kotzampassi [15] pursued temporary esophageal stenting in 12 mechanically ventilated patients who developed TEF. Nine of their 12 patients died after stent placement, while only three were referred to surgical repair. Whether stent placement delayed definitive surgical treatment in those who died or improved the condition of those who underwent surgical repair is unclear. Unfortunately, esophageal stents have been reported in the creation of giant TEF [8, 16]. Traina and colleagues [17] presented a case report of a 74-year-old woman who had been previously ventilated and developed symptoms of TEF two months after the discharge. Tracheoesophageal fistula was confirmed and treated with the over-the-scope clip during esophagogastroduodenoscopy (EGDS). A full closure of the fistula was seen on EGDS, bronchoscopy and gastrografin esophagography carried out at 2 and 4 weeks of the follow-up. Attempts to close TEF with a cardiac septal occluder failed [18]. Tracheal stenting should be avoided because these stents lead to a significant granulation tissue and typically extend the airway injury [19]. In our study, one patient with a small TEF (4 mm in diameter) and tracheal stenosis underwent tracheal stenting with a T tube.

The question about the timing of fistula closure in ventilator-dependent patients is also under discussion. Grillo, Mathisen and colleagues [5,13,19] suggest an aggressive approach to control the effects of the fistula while stabilizing the patient (gastrostomy for decompression, feeding jejunostomy) and weaning the patient from the ventilator before definitive one-stage surgical repair. Shen and colleagues [14] performed four opera-

tions on patients who were still ventilator-dependent at the time of surgical repair. They also favour delaying the single-stage repair of the TEF until the patient is no longer dependent on mechanical ventilation if possible, but they don't consider ventilator-dependence to be a contraindication to a successful surgical repair, particularly when tracheal resection and reconstruction are not required.

Freire and colleagues [20] reported a successful treatment of a patient with TEF who was still on ventilator at the time of surgery. The esophageal lesion was repaired and additionally silicone endoprosthesis was inserted into the tracheal lumen.

According to our data, four patients underwent a simple TEF repair, while one patient required tracheal resection and reconstruction. Muniappan and colleagues [13] performed tracheal or laryngotracheal resection and reconstruction in 54% of patients, membranous tracheal repair in 41%, and repair over a tracheal T tube in 5%. Usually, tracheal or laryngotracheal resection and reconstruction was performed due to a circumferential injury and significant airway stenosis. Shen and colleagues [14] reported that the most common operations were surgical repair in 51.4% of patients, esophageal diversion in 17.1%, and tracheal closure with esophageal resection in 11.4%.

## REFERENCES

1. Gross RE. *Surgery of Infancy and Childhood*. Philadelphia: Saunders; 1953.
2. Yasuda M, Hanagiri T, Ichiki Y, Takenoyama M, Sugio K, Yasumoto K. Congenital tracheoesophageal fistula in an elderly patient with thoracic empyema. *Gen Thorac Cardiovasc Surg* 2009; 57: 622–4.
3. Reed MF, Mathisen DJ. Tracheoesophageal fistula. *Chest Surg Clin N Am* 2003; 13: 271–89.
4. Burt M, Diehl W, Martini N, Bains MS, Ginsberg RJ, McCormack PM, Rusch VW. Malignant esophagorespiratory fistula: management options and survival. *Ann Thorac Surg* 1991; 52: 1222–9.
5. Grillo HC. *Surgery of the Trachea and Bronchi. Acquired Tracheoesophageal and Bronchoesophageal Fistula*. London, BC Decker Inc. 2004; 341–56.
6. Trottier SJ, Hazard PB, Sakabu SA, Levine JH, Troop BR, Thompson JA, McNary R. Posterior tracheal wall perforation

Most of the studies suggest the use of the vascularised tissue to separate tracheal and esophageal suture lines [7, 13, 14, 19]. Vascularised muscle flaps separated suture lines in all our cases (sternohyoid or sternothyroid muscles).

Camargo and colleagues [21] presented a study of nonmalignant TEF surgical treatment with no muscle interposition between the suture lines. All the 16 patients underwent tracheal resection recorded in this study. They denied using vascularised flap interposition because of the risk to develop dysphagia and tracheal stenosis due to the interposed muscle pushing the membranous tracheal wall or the esophagus.

Despite this study with impressive postoperative results, we are in favour of using vascularised tissue to separate tracheal and esophageal suture lines as many authors [7, 10, 13, 19] suggest to use this operative technique.

## Conclusions

After the weaning from mechanical ventilation, single-stage surgical repair with or without tracheal resection and reconstruction with interposed vascularised tissue flaps can be successfully performed in the majority of patients with acquired nonmalignant TEF.

during percutaneous dilational tracheostomy: an investigation into its mechanism and prevention. *Chest* 1999; 115: 1383–9.

7. Baisi A, Bonavina L, Narne S, Peracchia A. Benign tracheoesophageal fistula: results of surgical therapy. *Dis Esophagus* 1999; 12: 209–11.

8. Ladurner R, Schulz C, Jacob P, Kuper M, Kratt T, Preyer S, Konigsrainer A. Surgical management of an esophagotracheal fistula as a severe late complication of repeated endoscopic stenting treatment. *Endoscopy* 2007; 39: E341–2.

9. Le Brigand, H, Roy, B. Fistules tracheoesophagiennes après trachéotomie. A propos de quatre observations. *Mem Acad Chir* 1966; 92: 405.

10. Hedden M, Ersoz CJ, Safar P. Tracheoesophageal fistulas following prolonged artificial ventilation via cuffed tracheostomy tubes. *Anesthesiology* 1969; 31(3): 281–9.

11. Flege Jr. JB. Tracheoesophageal fistula caused by cuffed tracheostomy tube. *Ann Surg* 1967; 166: 153–6.

12. Macchiarini P, Verhoye JP, Chapelier A, Fadel E, Dart-  
eville P. Evaluation and outcome of different surgical techniques  
for postintubation tracheoesophageal fistulas. *J Thorac Cardiovasc  
Surg* 2000; 119: 268–76 .
13. Muniappan A, Wain JC, Wright CD, Donahue DM,  
Gaissert H, Lanuti M, Mathisen DJ. Surgical treatment of non-  
malignant tracheoesophageal fistula: a thirty-five year experience.  
*Ann Thorac Surg* 2013; 95: 1141–6.
14. Shen KR, Allen MS, Cassivi SD, Nichols FC 3rd,  
Wigle DA, Harmsen WS, Deschamps C. Surgical management  
of acquired nonmalignant tracheoesophageal and bronchoesopha-  
geal fistulae. *Ann Thorac Surg* 2010; 90: 914–8.
15. Eleftheriadis E, Kotzampassi K. Temporary stenting of  
acquired benign tracheoesophageal fistulas in critically ill venti-  
lated patients. *Surg Endosc*. 2005; 19: 811–5.
16. Han Y, Liu K, Li X, Wang X, Zhou Y, Gu Z, Ma Q,  
Jiang T, Huang L, Zhang T, Cheng Q. Repair of massive stent-  
induced tracheoesophageal fistula. *J Thorac Cardiovasc Surg* 2009;  
137: 813–7.
17. Traina M, Curcio G, Tarantino I, Soresi S, Barresi L,  
Vitolo P, Gridelli B. New endoscopic over-the-scope clip system  
for closure of a chronic tracheoesophageal fistula. *Endoscopy*  
2010; 42: E54–5.
18. Coppola F, Boccuzzi G, Rossi G, Gaia S, Cosimato M,  
Recchia S. Cardiac septal umbrella for closure of a tracheoesopha-  
geal fistula. *Endoscopy* 2010; 42: E318–9.
19. Mathisen DJ, Grillo HC, Wain JC, Hilgenberg AD.  
Management of acquired nonmalignant tracheoesophageal fistula.  
*Ann Thorac Surg* 1991; 52: 759–65.
20. Freire JP, Feijo SM, Miranda L, Santos F, Castelo HB.  
Tracheo-esophageal fistula: combined surgical and endoscopic  
approach. *Diseases of the Esophagus* 2006; 19: 35–9.
21. Camargo JJ, Machuca TN, Camargo SM, Lobato VF,  
Medina CR. Surgical treatment of benign tracheo-esophageal  
fistulas with tracheal resection and esophageal primary closure: is  
the muscle flap really necessary? *Eur J Cardiothorac Surg* 2010;  
37: 576–80.