

Adult-Onset Spinal Teratoma: A Case Report and Review

K. Blank*

G. Terbetas**

L. Neverauskienė***

J. Ušinskienė****

**Vilnius University,
Faculty of Medicine*

***Vilnius University,
Faculty of Medicine;
Republican Vilnius
University Hospital,
Department of Neurosurgery*

*** *PLLC “Patologijos centras”*

**** *Vilnius University,
Faculty of Medicine;
National Cancer Institute*

Summary. Teratoma is defined as a neoplasm that is composed of a variety of parenchymal cell types derived from three germinal layers (endoderm, mesoderm and ectoderm). Teratomas of the spinal cord constitute 0.1–0.5% of all spinal tumors, and these lesions are extremely rare in adults. Intramedullary spinal teratoma is the most common type of spinal teratomas. The main spinal teratoma symptoms are pain, weakness and numbness of the legs, sphincter and/or gait dysfunction; intramedullary teratomas present early with increased reflexes and loss of vesical and rectal control. Histopathologic examination is the gold standard for definite diagnosis. Teratomas are diagnosed when remnants of all three germ layers are present. MRI is the gold standard diagnostic technique for spinal teratoma. The tumor presents as inhomogeneous intensities in both T1- and T2-weighted images due to teratoma's tissue heterogeneity. Surgical resection is the first line treatment for spinal teratoma, usually decompressive laminectomy is performed. The goal of surgery should always be the most radical removal possible with relieve of the nerve compression with the aim of preventing progressive deterioration. The authors describe the first case of intradural intramedullary teratoma in Lithuania, which did not present with typical spinal teratoma symptoms and signs, its successful diagnosis and treatment; literature review of adult-onset spinal teratomas is also presented.

Keywords: spinal teratoma, spinal tumor, adult-onset.

INTRODUCTION

Teratomas are germ cell tumors that include all three embryonic layers: endoderm, mesoderm and ectoderm. Teratoma rarely occurs in the central nervous system and in the spinal cord. Teratoma predominantly occurs in neonates and young children, therefore is an unusual finding in adults. Spinal teratomas can be located extradurally, intramedullary or extramedullary, and can be mature, immature and malignant based on histological degree of differentiation.

Address:

*Gunaras Terbetas
Respublikinė Vilniaus Universitetinė Ligoninė,
Neurochirurgijos skyrius
Šiltanamių g. 29, LT-04130 Vilnius
E-mail: terbetas@gmail.com*

We present a rare case and literature review of a mature intramedullary spinal teratoma. To our knowledge, this is the first reported case of adult-onset spinal teratoma in Lithuania.

CASE REPORT

Clinical Presentation

A 36-year-old woman presented with 8 years of progressing lower back pain. There was no history of spinal dysraphism, congenital spinal abnormalities, previous spinal surgery, or lumbar puncture. Seven months prior to hospitalization the patient experienced a two-day episode of numbness and weakening of the right thigh. Neurological examination revealed hyperesthesia at L1 dermatomes on both sides and at L2 dermatomes on the right, higher reflexes in legs than in arms, positive Babinski reflex on the right.

© Neurologijos seminarai, 2019. Open Access. This article is distributed under the terms of the Creative Commons Attribution 4.0 International License CC-BY 4.0 (<http://creativecommons.org/licenses/by/4.0/>), which permits unrestricted use, distribution, and reproduction in any medium, provided you give appropriate credit to the original author(s) and the source, provide a link to the Creative Commons license, and indicate if changes were made.

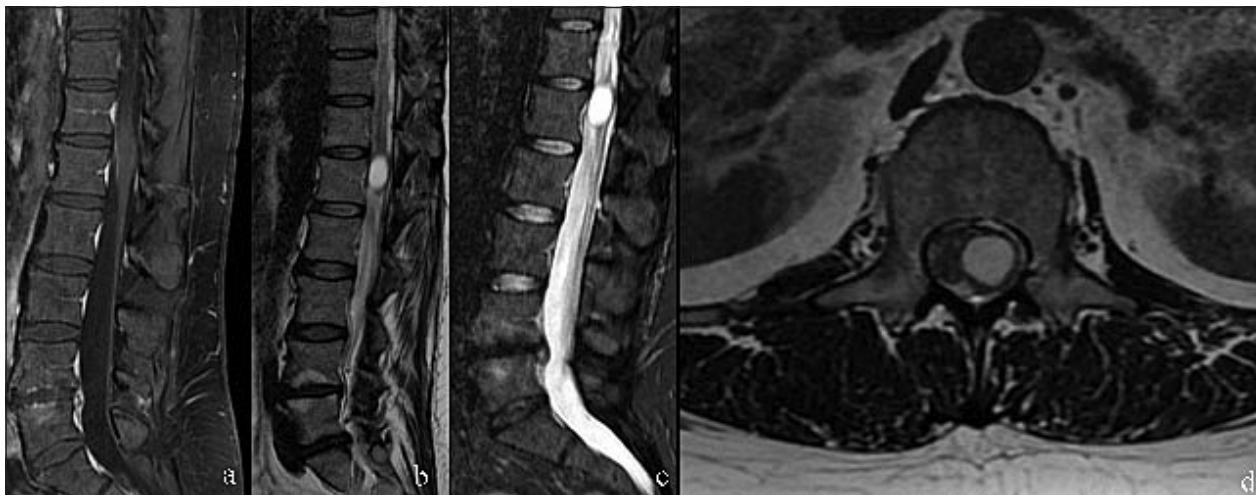

Fig. 1. Lumbar spine MRI

a, b - T2 sagittal and axial plane showed well delineated cystic lesion; c - T2 TIRM sequence showed no intralésional fat; d - T1 sequence with fat suppression after contrast admission showed no contrast enhancement in the lesion

Radiology Findings

Lumbar magnetic resonance revealed intramedullary intraconal tumor at the L1-level (13×13×19 mm), located on the left side of spinal cord conus (see Fig. 1).

Intraoperative Findings

Th12-L2 left hemilaminectomy was performed with total extirpation with use of intraoperative neuromonitoring, motor evoked potentials (MEP) and somatosensory evoked potentials (SSEP) were monitored. Medial incision of dura mater was performed. This exposed the tumor, which was bulging dorsally. During dorsal medial myelotomy, a cavity of 15×15 mm was found filled with protein-like clear viscous liquid. The cavity was evacuated, revised. Total excision of tumor was performed. MEP and SSEP responses were higher in the right leg in comparison to beginning of the surgery, in the left leg they maintained within the normal range throughout the surgery.

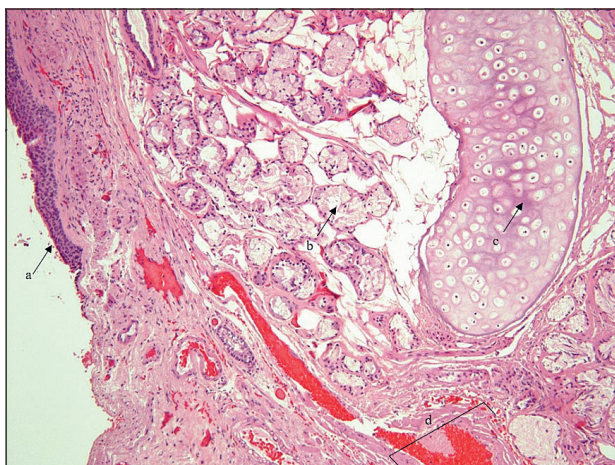


Fig. 2. Histological view (hematoxylin and eosin stain)

a - transitional and respiratory epithelium, b - acinar structures, c - hyaline cartilage, d - blood vessels with thick walls

Postoperative Recovery

Postoperatively, neurological symptoms regressed, the patient was mobilized and was able to start walking with assistance. The patient was discharged with recommendations to continue physical therapy.

Histopathology Findings

Histopathology examination (with hematoxylin and eosin stain) of the resected tumor revealed transitional and respiratory epithelium, acinar structures, hyaline cartilage, blood vessels with thick walls. There were no immature elements or malignant cells (Fig. 2).

DISCUSSION

Teratoma is defined as a neoplasm that is composed of a variety of parenchymal cell types derived from three germinal layers (ectoderm, endoderm, and mesoderm) and can occur at many locations throughout the body [1-4]. Teratoma rarely occurs in the central nervous system (only 2% of all teratomas) [5] and it constitutes only 0.1-0.5% of all spinal cord tumors [2, 4-7]. Moreover, teratoma predominantly occurs in neonates and young children; adult-onset teratoma is very rare [2, 3, 5, 8-10]. To our knowledge, under 150 cases of adult-onset spinal teratoma have been reported to this date. The first intraspinal teratoma was described by Virchow in 1863 [11] and the first confirmed case of intradural spinal teratoma was reported by Gowers et al. in 1888 [12]. Primary cranial teratomas have been reported to arise in the suprasellar region and the pineal gland [4]. Spinal teratomas can be extradural or intradural, and the latter can be located intramedullary or extramedullary [13] (intramedullary spinal teratoma is the most common type) [2]. They can be classified on their histological degree of differentiation as mature, immature, and malignant

[4]. In our reviewed literature there was no consensus between authors on the most common location of spinal teratoma: cervical [14], thoracic [2, 15–24], lumbar [1, 2, 15–24] or conus [1, 14]. No sex specific differences were found in spinal teratoma incidence [4] but there is a significant difference in mean age at the time of diagnosis between male and female: 36.4 ± 12.3 years for men and 41.3 ± 11.6 for women [4]. Spinal teratomas usually are not diagnosed preoperatively due to their rarity [1, 10].

Pathogenesis

The pathogenesis of spinal teratoma is still not clear, however several hypotheses have been proposed: the dysembryogenic theory [25, 26] and the misplaced primordial germ cell theory [2, 25, 27–30]. The former states that the lesions are not neoplastic, and they are a consequence of dysfunction of various factors involved in gene function and cellular inductive interactions, which leads to chaotically differentiated pluripotent cells in caudal cell mass or primitive streak. This theory is supported by Park et al. [26], who claim that associated dysraphic malformations show strong evidence to support dysembryogenic theory. The latter theory suggests that lesions are neoplastic. Misplaced primordial germ cell theory suggests that during their normal migration from the primitive yolk sack to the gonadal ridges, certain primordial cells of the neural tube are misplaced into the dorsal midline. Many authors support this theory and state, that significant dysraphism is absent in greater percentage of adult intradural teratomas, thus showing stronger evidence for the second theory. However, Makary et al. [24] propose an alternative idea, which suggests that there is a cause-and-effect relationship between the migration of primordial germ cells and spinal cord malformation. They state that dysfunction of genetic and cellular inductive interactions during embryogenesis leads to chaotic differentiation because of which pluripotent cells may be entrapped in an abnormal environment, which leads to teratoma formation.

Clinical Presentation

Spinal teratomas can clinically present with a wide array of neurological and/or dermatological symptoms; the course of symptoms is usually long and progressive or intermittent [19], thus a detailed physical examination is necessary [2]. Turan et al. show that symptom duration is longer for women and they had a longer symptomatic period before the surgery [4]. The main spinal teratoma symptoms are pain, weakness and numbness of the legs, sphincter and/or gait dysfunction [2, 4]. Typically, pathognomonic nerve root pain is associated with extramedullary tumors [31], while intramedullary teratomas present early with increased reflexes and loss of vesical and rectal control [4]. As stated earlier, some patients may experience remission of symptoms before surgery. This may be explained by reabsorption or leakage of the cystic content or fluctuating activity of glandular elements of the tumor [32, 33]. Recur-

rent aseptic meningitis may be caused by leakage of lipoid and keratin cholesterol. This symptom should indicate the existence of intradural teratoma [34]. In some cases, various skin markers can support suspicion of spinal teratoma. Such markers include skin stigmata, hairy patch and dimple, dermal sinus [2].

Pathological Findings

As in any tumor, histopathologic examination is the gold standard for definite diagnosis. Classically, teratomas are diagnosed when remnants of all three germ layers are present (ectoderm, mesoderm and endoderm) [1, 5, 6, 32, 35], however some authors have noted that in some cases it might be difficult to determine all three layers because of the overgrowth of 1 or 2 layers, thus it has been suggested that the spinal teratoma diagnosis cannot be demonstrated in the histological sample [5]. Spinal teratomas are classified into 3 types according to the degree of differentiation: mature, immature and malignant [1, 23, 36]. Histologically mature teratoma presents with recognizably differentiated tissues [10]. Immature teratomas are composed of primitive, undifferentiated components [10]. This type of teratoma is prone to frequent recurrence and aggressiveness [1]. Malignant teratomas are derived from endodermal sinus or yolk sack and may be associated with a poor prognosis, especially along with high levels of serum E-fetoprotein [25, 28]. All teratomas have malignant potential, including mature teratomas, in which malignization may arise from squamous components [10].

Radiological Findings

In diagnosing spinal teratoma, conventional X-rays and CT scans have very limited roles [1]. X-ray radiography often shows bony erosion of vertebral bodies, widening of interpedicular space, associated with diastematomyelia or tumors with calcifications, thinned laminae, with or without significant associated vertebral anomalies, such as vertebral body fusion, incomplete segmentation of vertebrae, spina bifida, butterfly vertebrae [1, 24, 37, 38]. X-ray radiography is often used as the first diagnostic procedure [2], however it gives very limited information. CT scans may be useful to demonstrate mixed-density lesions occupying intradural space or intralaminar calcification [2, 24]. Moreover, spinal bony structure can be assessed, although this radiological method does not visualize demarcation between tumor and spinal cord parenchyma [2]. MRI is the gold standard diagnostic technique for spinal teratoma [1]. The tumor presents as inhomogeneous intensities in both T1- and T2-weighted images due to teratoma's tissue heterogeneity, which may consist of solid and/or cystic parts, fat, mucoid secretion or less commonly calcification [10, 37–40]. Lipomatous tissue and calcification are often seen, the former presents hyperintense signal on T1 sequence and hypointense on T2 and fat suppression, and the latter presents hypointense both on T1 and T2. If both lipomatous tissue and calcification present simulta-

neously, it makes distinguishing spinal teratoma from other intradural tumors easier [2]. Contrast-enhanced MRI rarely shows any enhancement [2]. MRI is favored for the ability to determine the precise localization and morphology of the lesion, although MRI does not provide definite diagnosis [1]. The final diagnosis must be confirmed via histopathology [41].

Surgical Treatment

Surgical resection is the first line treatment for spinal teratoma, usually decompressive laminectomy is performed [1, 42]. The goal of surgery should always be the most radical removal possible with relieve of the nerve compression with the aim of preventing progressive deterioration as reported in many of the cases [2, 4, 14, 41, 43, 44]. Complete resection is also recommended for avoiding immature tissue or residual malignancy after the surgery [32]. However, complete removal may not always be possible due to the location of tumor [1], especially adult-onset intradural spinal teratoma, which occurs more frequently as intramedullary [2]. A partial resection can be undertaken as a viable treatment option when the lesion is attached to vital structures, because of the low recurrence rates reported in the literature [4]. Although one must always hold the preservation of integrity of neural function as highest priority [2]. In our literature review, only in half of the cases complete excision was accomplished, most likely because of adhesion of the lesion to the surrounding nerve roots and spinal cord [4]. Many authors note that the recurrence rate after surgical treatment is low (as low as 0.03% after a period of 10 years) [4, 10] and there is no significant difference between total and subtotal resection (9% vs. 11%) [42]. However, the mean follow-up time was 30.6±38.0 months [4], therefore it is still not clear whether it is safe to assume that there is little chance of recurrence despite the lesion's slow growing nature [42]. Bladder dysfunction was the most common residual symptom [4].

Radiotherapy and Chemotherapy

As long as malignant or immature elements are found by pathology, radiotherapy should be performed immediately in order to prevent recurrence, even though the tumor is completely resected [28, 42]. The dose of irradiation is always below the widely accepted spinal cord tolerance dose of 45–50 Gy [45]. Potential adverse effects of radiotherapy should also be evaluated [17, 42]. The more recent estimate of 57–61 Gy in conventional fractionation [46] may cause a 5% complication rate in 5 years. By far, adjuvant therapy for adult-onset intradural spinal teratomas remains controversial and obscure [42] due to the extremely low incidence and limited experience. Only two reported cases received radiotherapy [36, 47]. To the best of our knowledge, adjuvant chemotherapy has not been applied in adult-onset intradural spinal teratomas to date [17, 33, 42].

References

1. Kumar R, Chanduka A, Purohit D, Mittal RS, Kaushal R. Intramedullary mature teratoma of cervical spine in an infant: a rare case report. *Romanian Neurosur* 2014; 21(3): 357–61. <https://doi.org/10.2478/romneu-2014-0050>
2. Wan W, Yang C, Yan W, Liu T, Yang X, Song D, et al. Adult-onset intradural spinal teratoma: report of 18 consecutive cases and outcomes in a single center. *Eur Spine J* 2017; 26(7): 1917–28. <https://doi.org/10.1007/s00586-016-4939-9>
3. Sharma MC, Jain D, Sarkar C, Suri V, Garg A, Singh M, et al. Spinal teratomas: a clinico-pathological study of 27 patients. *Acta Neurochir (Wien)* 2009; 151(3): 245–52. <https://doi.org/10.1007/s00701-009-0212-x>
4. Turan N, Halani SH, Baum GR, Neill SG, Hadjipanayis CG. Adult intramedullary teratoma of the spinal cord: a case report and review of literature. *World Neurosurg* 2016; 87: 661.e23–30. <https://doi.org/10.1016/j.wneu.2015.10.053>
5. Nonomura Y, Miyamoto K, Wada E, Hosoe H, Nishimoto H, Ogura H, et al. Intramedullary teratoma of the spine: report of two adult cases. *Spinal Cord* 2002; 40(1): 40–3. <https://doi.org/10.1038/sj.sc.3101247>
6. Fernández-Cornejo VJ, Martínez-Pérez M, Polo-García LA, Martínez-Lage JF, Poza M. Cystic mature teratoma of the filum terminale in an adult. Case report and review of the literature. *Neurocir Astur* 2004; 15(3): 290–3. [https://doi.org/10.1016/S1130-1473\(04\)70486-8](https://doi.org/10.1016/S1130-1473(04)70486-8)
7. Sloof J, Kernohan J, MacCarty C. Primary intramedullary tumors of the spinal cord and filum terminale. Philadelphia: WB Saunders, 1964.
8. Smoker W, Biller J, Moore S, Beck D, Hart M. Intradural spinal teratoma: case report and review of the literature. *Am J Neuroradiol* 1986; 7(5): 905–10.
9. Garrison J, Kasdon D. Intramedullary spinal teratoma: case report and review of the literature. *Neurosurgery* 1980; 7(5): 509–12. <https://doi.org/10.1227/00006123-198011000-00018>
10. Lekgabe E, Rogers TW, Laidlaw J, Lui E, Gaillard F. A case of conus medullaris teratoma. *J Clin Neurosci* 2018; 47: 123–6. <https://doi.org/10.1016/j.jocn.2017.09.025>
11. Virchow R. Die Krankhaften Geschwulste. Vol. 1. Berlin: Hirschwald, 1863; 514.
12. Gowers WR, Horsley V. A case of tumour of the spinal cord. Removal; Recovery. *Med Chir Trans* 1888; 71: 377–430.11.
13. Schmidt RF, Casey JP, Gandhe AR, Curtis MT, Heller JE. Teratoma of the spinal cord in an adult: report of a rare case and review of the literature. *J Clin Neurosci* 2017; 36: 59–63. <https://doi.org/10.1016/j.jocn.2016.10.022>
14. Hamada H, Kurimoto M, Hayashi N, Hirashima Y, Matsumura N, Endo S. Intramedullary spinal teratoma with spina bifida. *Childs Nerv Syst* 2001; 17(1-2): 109–11. <https://doi.org/10.1007/s003810000399>
15. Arai Y, Takahashi M, Takeda K, Shitoto K. Adult-onset intradural spinal teratoma in the lumbar spine: a case report. *J Orthop Surg* 2000; 8(2): 69–74. <https://doi.org/10.1177/230949900000800213>
16. Sandeep M, Rajesh C, Rahul G, Bishan DR. Cystic, exophytic teratoma of conus medullaris presenting with chronic renal failure. *Surg Neurol* 2008; 69(1): 81–3. <https://doi.org/10.1016/j.surneu.2006.11.057>

17. Li Y, Yang B, Song L, Yan D. Mature teratoma of the spinal cord in adults: an unusual case. *Oncol Lett* 2013; 6(4): 942–6. <https://doi.org/10.3892/ol.2013.1519>
18. Mut M, Shaffrey ME, Bourne TD, Jagannathan J, Shaffrey CI. Unusual presentation of an adult intramedullary spinal teratoma with diplomyelia. *Surg Neurol* 2007; 67(2): 190–4. <https://doi.org/10.1016/j.surneu.2006.04.012>
19. Caruso R, Antonelli M, Cervoni L, Salvati M. Intramedullary teratoma: case report and review of the literature. *Tumori* 1996; 82(6): 616–20. <https://doi.org/10.1177/030089169608200622>
20. Nicoletti GF, Albanese V, Passanisi M, Lanzafame S, Platania N. Intramedullary spinal cystic teratoma of the conus medullaris with caudal exophytic development: case report. *Surg Neurol* 1994; 41(2): 106–11. [https://doi.org/10.1016/0090-3019\(94\)90106-6](https://doi.org/10.1016/0090-3019(94)90106-6)
21. Jian W, Ying W, Chao Y. Intramedullary spinal teratoma of the conus medullaris: report of two cases. *Acta Neurochir (Wien)* 2010; 152(3): 553–4. <https://doi.org/10.1007/s00701-009-0466-3>
22. Padovani R, Tognetti F, Sanpaolo P, Pozzati E, Gaist G, Kuba I. Intramedullary cystic teratoma. *Acta Neurochir (Wien)* 1982; 62(1–2): 101–8. <https://doi.org/10.1007/BF01402216>
23. Fan X, Turner JE, Turner TM, Elrod JP, Clough JA, Howell EI, et al. Carcinoid tumor development in an intramedullary spinal cord mature teratoma. *AJNR Am J Neuroradiol* 2001; 22(9): 1778–81.
24. Makary R, Wolfson D, Dasilva V, Mohammadi A, Shuja S. Intramedullary mature teratoma of the cervical spinal cord at C1-2 associated with occult spinal dysraphism in an adult. *J Neurosurg Spine* 2007; 6: 579–84. <https://doi.org/10.3171/spi.2007.6.6.12>
25. Koen JL, McLendon RE, George TM. Intradural spinal teratoma: evidence for a dysembryogenic origin. Report of four cases. *J Neurosurg* 1998; 89(5): 844–51. <https://doi.org/10.3171/jns.1998.89.5.0844>
26. Park S, Kim K, Wang K-C, Choe G, Kim H-J. Spinal epidural teratoma: review of spinal teratoma with consideration on the pathogenesis: case report. *Neurosurgery* 2010; 67(6): E1818–25. <https://doi.org/10.1227/NEU.0b013e3181f846ca>
27. Al-Sarraj ST, Parmar D, Dean AF, Phookun G, Bridges LR. Clinicopathological study of seven cases of spinal cord teratoma: a possible germ cell origin. *Histopathology* 1998; 32(1): 51–6. <https://doi.org/10.1046/j.1365-2559.1998.00324.x>
28. Ak H, Ulu MO, Sar M, Albayram S, Aydin S, Uzan M. Adult intramedullary mature teratoma of the spinal cord: review of the literature illustrated with an unusual example. *Acta Neurochir (Wien)* 2006; 148(6): 663–9. <https://doi.org/10.1007/s00701-006-0755-z>
29. Stevens Q, Kattner K, Chen Y, Rahman M. Intradural extramedullary mature cystic teratoma: not only a childhood disease. *J Spinal Disord Tech* 2006; 19(3): 213–6. <https://doi.org/10.1097/01.bsd.0000188664.54014.c4>
30. Rewcastle N, Francoeur J. Teratomatous cysts of the spinal canal: with “Sex Chromatin” studies. *Arch Neurol* 1964; 11(1): 91–9. <https://doi.org/10.1001/archneur.1964.00460190095007>
31. Rasmussen TB, Kernolan JW, Adson AW. Pathologic classification, with surgical consideration, of intraspinal tumors. *Ann Surg* 1940; 111(4): 513–30. <https://doi.org/10.1097/00000658-194004000-00001>
32. Poeze M, Herpers MJ, Tjandra B, Freling G, Beuls EA. Intramedullary spinal teratoma presenting with urinary retention: case report and review of the literature. *Neurosurgery* 1999; 45(2): 379–85. <https://doi.org/10.1097/00006123-199908000-00038>
33. Beneš V, Barsa P, Mikulášťik J, Suchomel P. Exophytic intramedullary mature teratoma of the conus medullaris: case report and review of the literature. *Cent Eur Neurosurg* 2009; 70(3): 154–60. <https://doi.org/10.1055/s-0028-1082062>
34. Larbrisseau A, Renevey F, Brochu P, Décarie M, Mathieu J. Recurrent chemical meningitis due to an intraspinal cystic teratoma: case report. *J Neurosurg* 1980; 52(5): 715–7. <https://doi.org/10.3171/jns.1980.52.5.0715>
35. Cavazzani P, Ruelle A, Michelozzi G, Andrioli G. Spinal dermoid cysts originating intracranial fat drops causing obstructive hydrocephalus: case reports. *Surg Neurol* 1995; 43(5): 466–9. [https://doi.org/10.1016/0090-3019\(95\)80091-T](https://doi.org/10.1016/0090-3019(95)80091-T)
36. Agrawal M, Uppin MS, Patibandla MR, Bhattacharjee S, Panigrahi MK, Saradhi V, et al. Teratomas in central nervous system: a clinico-morphological study with review of literature. *Neurol India* 2010; 58(6): 841–6. <https://doi.org/10.4103/0028-3886.73740>
37. Moon HJ, Shin BK, Kim JH, Kim JH, Kwon TH, Chung HS, et al. Adult cervical intramedullary teratoma: first reported immature case. *J Neurosurg Spine* 2010; 13(2): 283–7. <https://doi.org/10.3171/2010.3.SPINE09461>
38. Monajati A, Spitzer RM, Wiley JL, Heggeness L. MR imaging of a spinal teratoma. *J Comput Assist Tomogr* 1986; 10(2): 307–10. <https://doi.org/10.1097/00004728-198603000-00025>
39. Awwad EE, Backer R, Archer CR. The imaging of an intraspinal cervical dermoid tumor by MR, CT, and sonography. *Comput Radiol* 1987; 11(4): 169–73. [https://doi.org/10.1016/0730-4862\(87\)90046-1](https://doi.org/10.1016/0730-4862(87)90046-1)
40. Gu R, Liu JB, Zhang Q, Liu GY, Zhu QS. MRI diagnosis of intradural extramedullary tumors. *J Can Res Ther* 2014; 10(4): 927–31. <https://doi.org/10.4103/0973-1482.137993>
41. Ghostine S, Perry E, Vaynman S, Raghavan R, Tong KA, Samudrala S, et al. The rare case of an intramedullary cervical spinal cord teratoma in an elderly adult: case report and literature review. *Spine* 2009; 34(26): E973–8. <https://doi.org/10.1097/BRS.0b013e3181ba0fe5>
42. Allsopp G, Sgouros S, Barber P, Walsh AR. Spinal teratoma: is there a place for adjuvant treatment? Two cases and a review of the literature. *Br J Neurosurg* 2000; 14(5): 482–8. <https://doi.org/10.1080/02688690050175364>
43. Ijiri K, Hida K, Yano S, Iwasaki Y. Huge intradural ossification caused by a mature spinal teratoma. *Neurosurgery* 2009; 64(6): E1200–1. <https://doi.org/10.1227/01.NEU.0000345939.06275.9A>
44. Kalani MY, Iyer S, Coons SW, Smith KA. Spinal intradural teratomas: developmental programs gone awry? *Neurosurg Focus* 2012; 33(4): 1–4. <https://doi.org/10.3171/2012.8.FOCUS12230>
45. Emami B, Lyman J, Brown A, Coia L, Goitein M, Munzenrider JE, et al. Tolerance of normal tissue to therapeutic irradiation. *Int J Radiat Oncol Biol Phys* 1991; 21(1): 109–22. [https://doi.org/10.1016/0360-3016\(91\)90171-Y](https://doi.org/10.1016/0360-3016(91)90171-Y)
46. Schultheiss TE, Kun LE, Ang KK, Stephens LC. Radiation response of the central nervous system. *Int J Radiat Oncol Biol Phys* 1995; 31(5): 1093–112. [https://doi.org/10.1016/0360-3016\(94\)00655-5](https://doi.org/10.1016/0360-3016(94)00655-5)

47. Ironside JW, Jefferson AA, Royds JA, Taylor CB, Timperley WR. Carcinoid tumour arising in a recurrent intradural spinal teratoma. *Neuropathol Appl Neurobiol* 1984; 10(6): 479–89. <https://doi.org/10.1111/j.1365-2990.1984.tb00395.x>

K. Blank, G. Terbetas, L. Neverauskienė, J. Ušinskienė

SUAUGUSIŲJŲ SPINALINĖ TERATOMA: KLINIKINIS ATVEJIS IR LITERATŪROS APŽVALGA

Santrauka

Teratoma yra apibrėžiama kaip neoplazma, kuri susideda iš įvairių parenchiminųjų ląstelių, kilusių iš trijų germinacinių sluoksnių (ektodermos, mezodermos ir endodermos). Nugaros smegenų teratomos sudaro 0,1–0,5 % visų nugaros smegenų navikų. Taip pat šis navikas yra itin retas tarp suaugusiųjų. Intramedulinė spinalinė teratoma yra pats dažniausias šio naviko tipas. Pagrindiniai spinalinės teratomos požymiai yra skausmas, kojų silpnumas ir tirpimas, šlaplės ar išangės raukų funkcijos sutrikimas, kai

anksti pasireiškia sustiprėję refleksai ir šlapinimosi bei tuštinimosi kontrolės praradimas. Histologinis ištyrimas yra tikslios diagnozės nustatymo auksinis standartas. Teratoma diagnozuojama, stebint audinius, kilusius iš visų trijų germinacinių sluoksnių. Magnetinio rezonanso tyrimas yra auksinis diagnostikos standartas. Dėl naviko audinių įvairovės, MRT vaizduose stebimi nehomogeniško intensyvumo vaizdai T1 ir T2 sekose. Chirurginė rezekcija yra pirmo pasirinkimo gydymas šiam navikui ir dažniausiai atliekama laminektomijos metu. Operacijos tikslas daugeliu atvejų turėtų būti radikali rezekcija su nervų kompresijos sumažinimu, siekiant sumažinti neurologinės funkcijų pablogėjimą. Straipsnio autoriai pristato pirmą intradurinės intramedulinės spinalinės teratomos atvejį Lietuvoje, kuris, nors ir nepasireiškė būdingais simptomais ir požymiais, tačiau buvo sėkmingai diagnozuotas ir gydytas, taip pat suaugusiųjų spinalinės teratomos literatūros apžvalgą.

Raktažodžiai: spinalinė teratoma, nugaros smegenų navikai, suaugusiųjų navikai.

Gauta:
2019 01 18

Primta spaudai:
2019 02 04