

World Journal of *Clinical Cases*

World J Clin Cases 2021 February 6; 9(4): 764-998



MINIREVIEWS

- 764 Chiari malformations in children: An overview
Spazzapan P, Bosnjak R, Prestor B, Velnar T

ORIGINAL ARTICLE**Case Control Study**

- 774 Effect of hospital discharge plan for children with type 1 diabetes on discharge readiness, discharge education quality, and blood glucose control
Tong HJ, Qiu F, Fan L

Retrospective Study

- 784 Effect of biofeedback combined with high-quality nursing in treatment of functional constipation
Zhao X, Meng J, Dai J, Yin ZT
- 792 Radioactive ¹²⁵I seed implantation for pancreatic cancer with unexpected liver metastasis: A preliminary experience with 26 patients
Li CG, Zhou ZP, Jia YZ, Tan XL, Song YY

Clinical Trials Study

- 801 Biliary stent combined with iodine-125 seed strand implantation in malignant obstructive jaundice
Wang HW, Li XJ, Li SJ, Lu JR, He DF

Observational Study

- 812 Effects of different statins application methods on plaques in patients with coronary atherosclerosis
Wu X, Liu XB, Liu T, Tian W, Sun YJ
- 822 Usefulness of prenatal magnetic resonance imaging in differential diagnosis of fetal congenital cystic adenomatoid malformation and bronchopulmonary sequestration
Li Z, Lv YD, Fang R, Li X, Luo ZQ, Xie LH, Zhu L

CASE REPORT

- 830 Reciprocal hematogenous osteomyelitis of the femurs caused by *Anaerococcus prevotii*: A case report
Daunaraite K, Uvarovas V, Ulevicius D, Sveikata T, Petryla G, Kurtinaitis J, Satkauskas I
- 838 Gastroduodenal intussusception caused by gastric gastrointestinal stromal tumor: A case report and review of the literature
Hsieh YL, Hsu WH, Lee CC, Wu CC, Wu DC, Wu JY

- 847** Altemeier perineal rectosigmoidectomy with indocyanine green fluorescence imaging for a female adolescent with complete rectal prolapse: A case report
Yamamoto T, Hyakudomi R, Takai K, Taniura T, Uchida Y, Ishitobi K, Hirahara N, Tajima Y
- 854** Long-term survival in a patient with Hutchinson-Gilford progeria syndrome and osteosarcoma: A case report
Hayashi K, Yamamoto N, Takeuchi A, Miwa S, Igarashi K, Araki Y, Yonezawa H, Morinaga S, Asano Y, Tsuchiya H
- 864** Recurrent medullary thyroid carcinoma treated with percutaneous ultrasound-guided radiofrequency ablation: A case report
Tong MY, Li HS, Che Y
- 871** "Bull's eye" appearance of hepatocellular adenomas in patients with glycogen storage disease type I – atypical magnetic resonance imaging findings: Two case reports
Vernuccio F, Austin S, Meyer M, Guy CD, Kishnani PS, Marin D
- 878** Clinical characteristics and *ABCC2* genotype in Dubin-Johnson syndrome: A case report and review of the literature
Wu H, Zhao XK, Zhu JJ
- 886** Adult-onset Still's disease evolving with multiple organ failure and death: A case report and review of the literature
Han ZB, Wu J, Liu J, Li HM, Guo K, Sun T
- 898** Open reduction and Herbert screw fixation of Pipkin type IV femoral head fracture in an adolescent: A case report
Liu Y, Dai J, Wang XD, Guo ZX, Zhu LQ, Zhen YF
- 904** Acute pancreatitis with pulmonary embolism: A case report
Fu XL, Liu FK, Li MD, Wu CX
- 912** Apert syndrome diagnosed by prenatal ultrasound combined with magnetic resonance imaging and whole exome sequencing: A case report
Chen L, Huang FX
- 919** Application of neoadjuvant chemotherapy combined with anlotinib in occult breast cancer: A case report and review of literature
Zhang Y, Wu D, Zhao B, Tian XL, Yao TC, Li F, Liu WF, Shi AP
- 927** Atypical presentation of shoulder brucellosis misdiagnosed as subacromial bursitis: A case report
Wang FS, Shahzad K, Zhang WG, Li J, Tian K
- 935** Retroperitoneal teratoma resection assisted by 3-dimensional visualization and virtual reality: A case report
Liu T, Chen K, Xia RM, Li WG
- 943** Renal failure and hepatitis following ingestion of raw grass carp gallbladder: A case report
Zhou LN, Dong SS, Zhang SZ, Huang W

- 951** Pheochromocytoma as a cause of repeated acute myocardial infarctions, heart failure, and transient erythrocytosis: A case report and review of the literature
Shi F, Sun LX, Long S, Zhang Y
- 960** Immediate implant placement in combination with platelet rich-fibrin into extraction sites with periapical infection in the esthetic zone: A case report and review of literature
Fang J, Xin XR, Li W, Wang HC, Lv HX, Zhou YM
- 970** Acute inferior wall myocardial infarction induced by aortic dissection in a young adult with Marfan syndrome: A case report
Zhang YX, Yang H, Wang GS
- 976** Primary nonkeratinizing squamous cell carcinoma of the scapular bone: A case report
Li Y, Zuo JL, Tang JS, Shen XY, Xu SH, Xiao JL
- 983** Fertility-sparing surgeries without adjuvant therapy through term pregnancies in a patient with low-grade endometrial stromal sarcoma: A case report
Gu YZ, Duan NY, Cheng HX, Xu LQ, Meng JL
- 992** Isolated interrupted aortic arch in an adult: A case report
Dong SW, Di DD, Cheng GX

ABOUT COVER

Editorial Board Member of *World Journal of Clinical Cases*, Salim R Surani, MD, MPH, MSHM, FACP, FCCP, FAASM is Chair of Critical Care at Corpus Christi Medical Center, Adjunct Clinical Professor of Medicine, Department of Pulmonary, Critical Care and Sleep Medicine at Texas A&M University, and Program Director of the Pulmonary Fellowship Program at Bay Area Medical Center, Corpus Christi. His training and education involved fellowship in Pulmonary Medicine at Baylor College of Medicine, Master's in Public Health, & Epidemiology from Yale University, and Master's in Health Management from University of Texas, Dallas. Having authored more than 250 peer-reviewed articles and written several books and book chapters. (L-Editor: Filipodia)

AIMS AND SCOPE

The primary aim of *World Journal of Clinical Cases* (*WJCC*, *World J Clin Cases*) is to provide scholars and readers from various fields of clinical medicine with a platform to publish high-quality clinical research articles and communicate their research findings online.

WJCC mainly publishes articles reporting research results and findings obtained in the field of clinical medicine and covering a wide range of topics, including case control studies, retrospective cohort studies, retrospective studies, clinical trials studies, observational studies, prospective studies, randomized controlled trials, randomized clinical trials, systematic reviews, meta-analysis, and case reports.

INDEXING/ABSTRACTING

The *WJCC* is now indexed in Science Citation Index Expanded (also known as SciSearch®), Journal Citation Reports/Science Edition, Scopus, PubMed, and PubMed Central. The 2020 Edition of Journal Citation Reports® cites the 2019 impact factor (IF) for *WJCC* as 1.013; IF without journal self cites: 0.991; Ranking: 120 among 165 journals in medicine, general and internal; and Quartile category: Q3. The *WJCC*'s CiteScore for 2019 is 0.3 and Scopus CiteScore rank 2019: General Medicine is 394/529.

RESPONSIBLE EDITORS FOR THIS ISSUE

Production Editor: Yan-Xia Xing; Production Department Director: Yun-Xiaojian Wu; Editorial Office Director: Jin-Lai Wang.

NAME OF JOURNAL

World Journal of Clinical Cases

ISSN

ISSN 2307-8960 (online)

LAUNCH DATE

April 16, 2013

FREQUENCY

Thrice Monthly

EDITORS-IN-CHIEF

Dennis A Bloomfield, Sandro Vento, Bao-gan Peng

EDITORIAL BOARD MEMBERS

<https://www.wjgnet.com/2307-8960/editorialboard.htm>

PUBLICATION DATE

February 6, 2021

COPYRIGHT

© 2021 Baishideng Publishing Group Inc

INSTRUCTIONS TO AUTHORS

<https://www.wjgnet.com/bpg/gerinfo/204>

GUIDELINES FOR ETHICS DOCUMENTS

<https://www.wjgnet.com/bpg/GerInfo/287>

GUIDELINES FOR NON-NATIVE SPEAKERS OF ENGLISH

<https://www.wjgnet.com/bpg/gerinfo/240>

PUBLICATION ETHICS

<https://www.wjgnet.com/bpg/GerInfo/288>

PUBLICATION MISCONDUCT

<https://www.wjgnet.com/bpg/gerinfo/208>

ARTICLE PROCESSING CHARGE

<https://www.wjgnet.com/bpg/gerinfo/242>

STEPS FOR SUBMITTING MANUSCRIPTS

<https://www.wjgnet.com/bpg/GerInfo/239>

ONLINE SUBMISSION

<https://www.f6publishing.com>

Reciprocal hematogenous osteomyelitis of the femurs caused by *Anaerococcus prevotii*: A case report

Karolina Daunaraite, Valentinas Uvarovas, Donatas Ulevicius, Tomas Sveikata, Giedrius Petryla, Jaunius Kurtinaitis, Igoris Satkauskas

ORCID number: Karolina Daunaraite 0000-0002-7154-1088; Valentinas Uvarovas 0000-0002-1045-6189; Donatas Ulevicius 0000-0001-8778-4482; Tomas Sveikata 0000-0002-6548-7767; Giedrius Petryla 0000-0003-2424-5443; Jaunius Kurtinaitis 0000-0003-3075-5562; Igoris Satkauskas 0000-0001-8449-990X.

Author contributions: Uvarovas V, Daunaraite K designed the research; Ulevicius D, Sveikata T, Kurtinaitis J, Petryla G performed the research; Satkauskas I, Daunaraite K, Uvarovas V analyzed the data; Ulevicius D, Daunaraite K, Uvarovas V wrote the paper.

Informed consent statement: Informed written consent was obtained from the patient for publication of this report and any accompanying images.

Conflict-of-interest statement: The authors declare that they have no conflict of interest.

CARE Checklist (2016) statement: The authors have read the CARE Checklist (2016), and the manuscript was prepared and revised according to the CARE Checklist (2016).

Open-Access: This article is an open-access article that was

Karolina Daunaraite, Donatas Ulevicius, Vilnius University, Institute of Clinical Medicine, Faculty of Medicine, Vilnius LT-08661, Lithuania

Valentinas Uvarovas, Tomas Sveikata, Giedrius Petryla, Jaunius Kurtinaitis, Igoris Satkauskas, Department of Orthopedics and Traumatology, Institute of Clinical Medicine, Faculty of Medicine, Vilnius University, Vilnius LT-08661, Lithuania

Donatas Ulevicius, Department of Orthopedics and Traumatology, Vilnius LT-04130, Lithuania

Corresponding author: Valentinas Uvarovas, MD, PhD, Doctor, Professor, Surgeon, Department of Orthopedics and Traumatology, Vilnius University Faculty of Medicine, Republican Vilnius University Hospital, Vilnius, Lithuania, Siltnamų str. 29, Vilnius 04130, Lithuania. valiusuvarovas@gmail.com

Abstract

BACKGROUND

Haematogenous osteomyelitis is an extremely rare disease occurring in adults, especially in developed countries. It is clearly a systemic infection, because bacteraemia spreads over proximal and distal long bones or paravertebral plexuses, resulting in acute or chronic bone infection and destruction.

CASE SUMMARY

A 46-year-old Caucasian male was complaining of a left thigh pain. It is known from the anamnesis that the patient developed severe pneumonia three months ago before the onset of these symptoms. The patient was diagnosed with haematogenous osteomyelitis, which developed a turbulent course and required complex combination therapy. The primary pathogen is thought to be *Anaerococcus prevotii*, which caused pneumonia before the onset of signs of osteomyelitis. Unfortunately, due to the complexity of identifying anaerobes and contributing nosocomial infections, the primary pathogen was not extracted immediately. After the manifestation of this disease, pathological fractures occurred in both femurs, as well as purulent processes in the lungs and molars accompanied. The patient received broad-spectrum antibiotic therapy and countless amounts of orthopaedic and reconstructive surgeries, but no positive effect was observed. The patient underwent osteosynthesis using an Ilizarov's external fixation apparatus, re-fixations, external AO, debridements, intramedullary osteosynthesis with a silver-coated intramedullary nail, abscessotomies.

selected by an in-house editor and fully peer-reviewed by external reviewers. It is distributed in accordance with the Creative Commons Attribution NonCommercial (CC BY-NC 4.0) license, which permits others to distribute, remix, adapt, build upon this work non-commercially, and license their derivative works on different terms, provided the original work is properly cited and the use is non-commercial. See: <http://creativecommons.org/licenses/by-nc/4.0/>

Manuscript source: Unsolicited manuscript

Specialty type: Medicine, research and experimental

Country/Territory of origin: Lithuania

Peer-review report's scientific quality classification

Grade A (Excellent): 0
Grade B (Very good): 0
Grade C (Good): C, C
Grade D (Fair): 0
Grade E (Poor): 0

Received: April 16, 2020

Peer-review started: April 17, 2020

First decision: April 24, 2020

Revised: May 1, 2020

Accepted: December 10, 2020

Article in press: December 10, 2020

Published online: February 6, 2021

P-Reviewer: Berber I, Smolić M

S-Editor: Liu JH

L-Editor: A

P-Editor: Zhang YL



The right femur healed completely after the pathological fracture and osteomyelitis did not recur. Left femur could not be saved due to non-healing, knee contracture and bone destruction. After almost three years of struggle, it was decided to amputate the left limb, after which the signs of osteomyelitis no longer appeared.

CONCLUSION

To sum it all up, complicated or chronic osteomyelitis requires surgery to remove the infected tissue and bone. Osteomyelitis surgery prevents the infection from spreading further or getting even worse up to such condition that amputation is the only option left.

Key Words: Hematogenous; Femur osteomyelitis; Reciprocal; Pathologic fracture; *Anaerococcus prevotii*; Case report

©The Author(s) 2021. Published by Baishideng Publishing Group Inc. All rights reserved.

Core Tip: Haematogenous osteomyelitis is an extremely rare disease in adults. Even rarer are pathological fractures that occur as a result. We present a clinical case in which a 46-year-old patient developed haematogenous osteomyelitis after pneumonia. Both femurs were damaged, but the right one was preserved thanks to the preventive built-in AO external fixation. The left thigh was amputated and the signs of osteomyelitis did not recur. The pathogen that caused this insidious disease, *Anaerococcus prevotii*, has not been reported in the literature as a cause of osteomyelitis. Moreover, there are no reported cases of osteomyelitis affecting both femurs at once.

Citation: Daunaraite K, Uvarovas V, Ulevicius D, Sveikata T, Petryla G, Kurtinaitis J, Satkauskas I. Reciprocal hematogenous osteomyelitis of the femurs caused by *Anaerococcus prevotii*: A case report. *World J Clin Cases* 2021; 9(4): 830-837

URL: <https://www.wjgnet.com/2307-8960/full/v9/i4/830.htm>

DOI: <https://dx.doi.org/10.12998/wjcc.v9.i4.830>

INTRODUCTION

Haematogenous osteomyelitis is an extremely rare disease occurring in adults, especially in industrial countries. It is a heterogeneous infection regarding the etiology and treatment, and is one of the most difficult infections to cure, as no single management protocol exists^[1]. It is classified into acute, sub-acute or chronic, according to the time of evolution. Acute osteomyelitis has usually a good response to antibacterial therapy and, if necessary, to surgical treatment. On the opposite, chronic osteomyelitis represents a great therapeutic challenge, requires more effort and medical intervention, becoming surgery essential to obtain the best results^[2,3].

A single pathogenic organism is almost always extracted from the bone in haematogenous osteomyelitis. In adults, *Staphylococcus aureus* is the most common organism isolated. However, other gram-positive cocci (including coagulase-negative staphylococci and *Streptococcus* spp.), gram-negative bacilli, and anaerobic organisms (listed in descending order of incidence) are also frequently isolated, and multiple organisms are usually isolated in contiguous focus osteomyelitis. Although, there is not a single reported case of haematogenous osteomyelitis caused by *Anaerococcus prevotii*^[4].

Incompletely cured acute osteomyelitis progresses to chronic, which is much more difficult to treat. Symptoms that occur with this condition include: Pain in the affected area in the bones, swelling, redness, and tenderness. The rupture of pus from an opening into an infected bone is often the first symptom. Bone destruction and infected pieces of bone, detached from healthy bone, can occur and those bone fragments may need to be operated. In the event of severe destruction, a pathological fracture may occur^[5,6].

Pathological fractures of the femur in adults caused by osteomyelitis are rare

consequences of this disease. The most common pathological fractures of the long bones in adults are due to a malignancy that has metastasized to the bones^[7]. Haematogenous long bone osteomyelitis in adults who are not immunosuppressed is a very rare phenomenon and only few cases have ever been reported. This condition, which causes a pathological fracture, is even rarer because only a few reports have been found in the English medical literature. Cases of reciprocal femoral hematogenous osteomyelitis have not been reported, so we present a clinical case in which pathological fractures of both femurs occurred.

CASE PRESENTATION

Chief complaints

For the first time, a 46-year-old Caucasian male was referred to the hospital because of sudden pain, redness and hardening in the lateral side of the left thigh, and subfebrile fever, with no anamnesis of trauma/injury or immunosuppression. Three months after the onset of the first symptoms of osteomyelitis in the left thigh, the patient began to complain of right thigh pain.

History of present illness

Patient's symptoms started two weeks ago with recurrent episodes of lateral side of left thigh, pain and swelling, which had been worsened the last 24 h.

History of past illness

At the second hospitalization, the patient stated that he had relapsed to pneumonia three months before the onset of the first symptoms of osteomyelitis, but there are no data on the pathological agent and the treatment applied, because patient was treated in other hospital. No evidence of immunosuppression was documented.

Physical examination

Redness and hardening in the lateral side of the left thigh.

Laboratory examinations

During each hospitalization, blood analysis revealed a mild leukocytosis, significant thrombocytosis and moderately elevated C-reactive protein. The blood biochemistries, as well as urine analysis were normal. Increased partial CO₂ was observed.

Imaging examinations

First hospitalization: During the first hospitalization, the patient underwent an X-ray showing the onset of left femoral destruction. A CT scan showed an abscess in the left thigh around the bone (Figure 1).

Second hospitalization: Three months after the first hospitalization symptoms recurred and patient was examined by an orthopaedist. Moreover, similar symptoms were seen in the right femur. Radiographs, MRI and CT scans were performed: Pathologic fracture of the left femoral diaphysis with displacement, osteomyelitis of the left femur, osteomyelitis of the right femur, sequester. The fistulogram showed a contrast flow broadly around the implant, the femoral region (Figure 2-4).

Third and fourth hospitalizations: An X-ray and MRI were performed during the third and fourth hospitalizations (Figure 5).

Microbiological identification of the causative agent

A thorough microbiological culture of the surgical materials (each time) from both thighs under anaerobic conditions was used to identify the pathogen *Anaerococcus prevotii*, sensitive to ampicillin and penicillin. It is believed that this pathogen is the main cause of the whole disease. Based on the history of pneumonia, it can be tentatively stated that it was also caused by this pathogen. The patient was also diagnosed with lung infiltrates and purulent processes on the molars, the same pathogen was extracted from the pus of the lungs. A mixed microflora was found during several hospitalizations, which we associate as a contributing nosocomial infection.

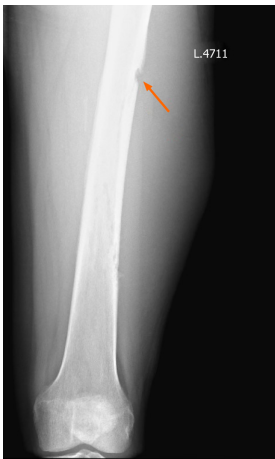

Figure 1 An X-Ray of the left thigh. Orange arrow indicates start of destruction of the femur.

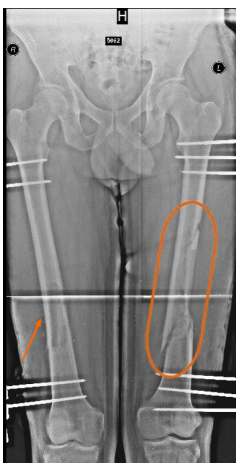


Figure 2 An X-Ray of both thighs with external AO fixation (preventive on the right). Orange arrow shows sequestrum, orange circle indicates osteosynthesis after fracture with displacement.

FINAL DIAGNOSIS

Spontaneous reciprocal haematogenous osteomyelitis of the femurs and secondary abscesses on both thighs, sepsis.

TREATMENT

First hospitalization

During first hospitalization patient underwent abscessotomy and twice (in nine days interval) - an active wash. He was treated with antibiotics, but no significant improvement was observed and debridement surgery was performed.

Second hospitalization

Three months later, symptoms recurred and patient underwent postoperative wound excision, abscessotomy, debridement, femoral trepanation, and washes were performed on a regular basis. It was decided to perform external osteosynthesis of the left femur using external AO fixation. In order to prevent a pathological fracture in the right femur, it was decided to install the external AO fixation. One month later, a pathological fracture without displacement of the right femur occurred, when the patient fell (with external AO fixation). The surgery was performed and AO was switched to external fixation with the Ilizarov's apparatus, which was left for half a year. Half a year later, the fracture completely healed, the device was removed, and the signs of osteomyelitis did not recur (Figure 5A).

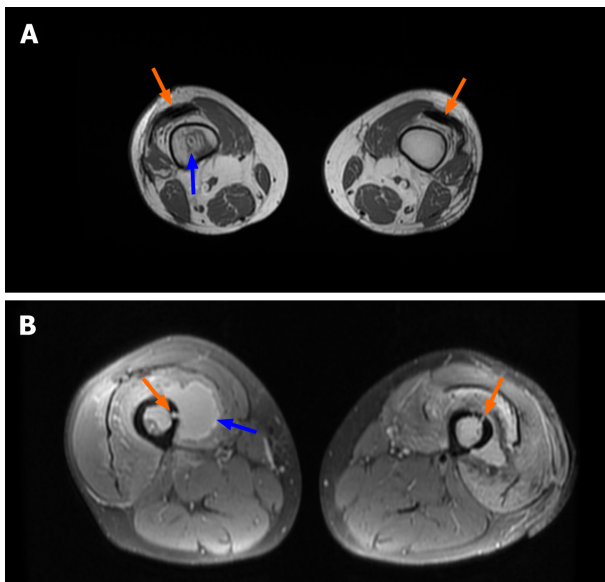


Figure 3 MRI scan of both thighs, axial section. A: Orange arrows indicate air inserts in interfascial spaces. Blue arrow indicates an abscess in the intramedullary space in the right femur. B: Fistulas are marked with orange arrows merging with the intramedullary space, present bone destruction. The blue arrow indicates a clearly visible abscess around the femur.

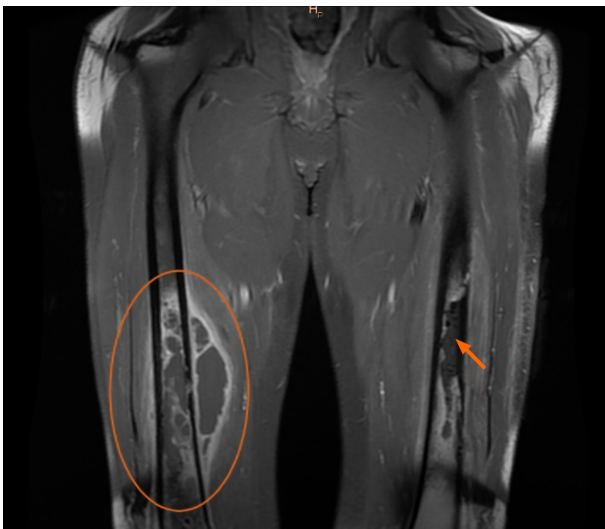

Figure 4 MRI scan of both thighs, frontal section. The orange circle shows the abscess near the femur and in intramedullary space. The orange arrow indicates the destructive processes taking place in the left femur. Also, the photo shows the longitudinal air inserts in the interfascial space.

Third and fourth hospitalizations

Five days later, the patient's condition worsened again, with secretion around the bars and severe pain of the left thigh. The patient underwent re-inoculation, debridement, and treatment with an intramedullary necklace of antibiotics. The external fixation with Ilizarov's apparatus was formed again. After about 8 mo, the patient's condition improved, he was seen by an orthopaedist on an outpatient basis, and it was decided to remove the proximal ring on the left side 9 mo after the last operation.

Fifth hospitalization

A month later, redness of the left thigh, intense pain and febrile fever occurred. Purulent discharge appeared around the bars. The patient was hospitalized in an Orthopaedic department and underwent four operations during hospitalization. Debridements, external fixation with Ilizarov's apparatus, after improvement of the condition, and intramedullary osteosynthesis with silver-plated intramedullary nail were performed in the remission of the infection. Long-term antibiotic therapy with Meropenem and Penicillin was applied.

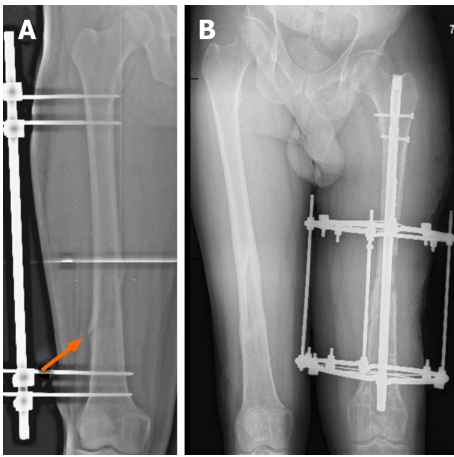


Figure 5 An X-Ray of both femurs after occurrence of pathological fractures. A: Pathological fracture occurred in the right femur, despite previous external AO fixation. Orange arrow indicates the location of the fracture B: An X-Ray of both thighs. Right femur completely healed (after 6 mo of treatment). On the left: External fixation with Ilizarov's apparatus, intramedullary osteosynthesis with silver-plated intramedullary nail. An X-Ray shows a significant shortening of the left limb.

The last operation involved a left knee remodeling, a long-lasting passive knee motion machine, with flexion up to 100 degrees. The left leg was radiographically shorter by 5 cm due to femoral resection. Once the patient's condition improved, he was discharged for outpatient treatment. At 2 mo after the last hospitalization, the patient sought emergency treatment for intense left knee and thigh pain, protrusion of a protruding propellant through the skin, and extensive wound secretion. In the radiographs performed, migration of the screws was observed. According to the patient, two days ago, at night, a screw had pierced the skin and he removed the screw himself. The patient underwent operative treatment - abscessotomy - with crop, biopsy, pathological examination. Due to the instability of the intramedullary nail, the distal femur was fixed by the external fixation with Ilizarov method with 2 rings.

The patient was discussed in the order of the consilium. He underwent removal of the intramedullary nail and external fixation apparatus and debridement on the left thigh were performed. After one month, repeated debridement and constant washing were performed, without any improvement. Debridement and external fixation with Ilizarov's apparatus of the left knee joint and left femur were performed after a few days.

During that hospitalization, the patient underwent four reconstructive/plastic surgeries of the left thigh. Transplantation of free fibula into femur was performed. The postoperative period was repeatedly complicated by infectious complication, purulent secretion from the wound and fistula. The patient was discussed on a consilium basis - as all the possibilities to restore the femoral integrity were exhausted with persistent infection, significant bone integrity damage, widespread infection of the femur, knee contracture, and negative dynamics. It was decided to perform amputation of the left femur. After the operation, the condition was complicated by sepsis and the patient was treated in the intensive care unit for several days. Two cases of stump debridement, Meropenem and Colistin, have been used for the infection of the stump.

OUTCOME AND FOLLOW-UP

The right femur healed completely and the signs of osteomyelitis did not appear. Positive clinical effects were observed on the stump of the left thigh with the combination therapy applied, and the stump healed in the primary manner. The patient was discharged in a satisfactory condition for rehabilitation treatment. The patient is seen on an outpatient basis for about a year by an orthopaedist and all signs of osteomyelitis have disappeared.

DISCUSSION

Although usually osteomyelitis is caused by many predisposing factors, including age, diabetes, peripheral vascular disease, drug abuse, various surgical implants, and immunodeficiencies, but sometimes we also have to deal with cases where patients have absolutely no risk factors. It is well known that the most common causes of osteomyelitis are bacteria^[4]. They enter the bloodstream from the source of the infection in the body (pneumonia, oral cavity infection, urinary tract infection, *etc.*), are brought into the bone with the blood, and cause hematogenous osteomyelitis^[8].

Surgical management in such cases is the cornerstone of therapy. Dead bone and foreign material must be removed, dead space must be managed with bone grafts, tissue flaps, or implanted antibiotic-impregnated material, and hardware should be removed unless absolutely necessary. When hardware is removed, antibiotic therapy should ideally be completed before new hardware is implanted. A one-stage approach with debridement alone or immediate re-implantation of hardware is less likely to achieve cure, though in specific circumstances these may be appropriate or necessary^[9].

In this case, after the patient has developed pneumonia and denied all other possible causes of osteomyelitis, it can be said that the same pathogen (*Anaerococcus prevotii*) moved to the left femur by haematogenous pathway and caused osteomyelitis. *Anaerococcus prevotii*, a Gram-positive, anaerobic, indole-negative coccus, is a common isolate of the normal flora of skin, the oral cavity and the gut and can also be isolated from human clinical specimens such as vaginal discharges and ovarian, peritoneal, sacral or lung abscesses. A review of the medical literature in English has not reported a single case in which *Anaerococcus prevotii* caused hematogenous osteomyelitis complicated by pathological fractures in both femurs^[10].

Significant thrombocytosis and increased partial CO₂ were observed each time the patient was admitted to the hospital with an exacerbation. Thrombocytosis is characteristic of an inflammatory process or infection in the body, which in this case the patient had. Elevated partial carbon dioxide indicated that there is a suitable condition for this anaerobic bacterium. In the Magnetic Resonance Imaging (MRI) air inclusions in interfascial space, which are characteristic of an anaerobic agent, were observed^[11]. In abscesses on both thighs, the purulent secretion had a particularly unpleasant odor and exuded with high pressure from medullary cavity (Figure 3).

When the patient underwent the first microbiological cultures from the punctate, a mixed microflora or individual other pathogens (*Klebsiella pneumoniae*, *Pseudomonas aeruginosa*, and others) were obtained, which could already indicate a possible contributing nosocomial infection.

Because of their fastidiousness, anaerobes are difficult to isolate and are often unrecognized. Delay in implementing appropriate therapy may lead to clinical failures. Their isolation requires proper methods of collection, transportation and cultivation of specimens. A single pathogen, the anaerobic bacterium *Anaerococcus prevotii*, which was most likely to be the cause of pneumonia, was recovered by several in-depth microbiological studies with proper transportation and the right conditions for growth. Also, it is important to mention that the patient relapsed after two years to another purulent lung infection during which surgery was performed, resected abscesses in the lungs and microbiological examinations isolated *Anaerococcus prevotii*^[12]. At the same time, the patient experienced purulent processes in the roots of the molars, which we can associate with the manifestation of the same bacterium.

The question arises as to why it was the amputation of the left limb that helped the patient to fully recover or at least not to relapse throughout the year. First of all, the left femoral fracture occurred with displacement. Although the femoral fractures were brought together, proper osteosynthesis was performed, and healing did not occur. Secondly, the manifestation of the infection, resulting in purulent processes, led to the destruction of the bone and required a large number of surgeries, after which, unfortunately, the bone was shortened by five centimeters. Finally, prolonged immobilization and shortening of the bone resulted in knee contracture, which also did not contribute to proper bone healing.

In contrast to the left thigh, the onset of signs of osteomyelitis in the right femur was followed immediately by preventive measures such as fixation by the external AO fixation to prevent pathological fracture. Although the fracture occurred, thanks to the existing apparatus, it was without displacement and remained stable. This resulted in better bone healing and full recover. In addition, a clear pathogen (*Anaerococcus prevotii*) was already present in the right femur at the onset of symptoms, which was also identified during abscessotomy from the surgical material.

CONCLUSION

To sum up, hematogenous osteomyelitis is an insidious disease that spreads throughout the body at lightning speed and usually is not typical in adults. It requires an initial source of infection to develop, which has been observed in the patient in this case. After pneumonia, the pathogen traveled haematogenously to the left femur and caused osteomyelitis. Due to the complex identification of anaerobic bacteria and lack of initial anamnesis of former pneumonia, *Anaerococcus prevotii* was not detected immediately. In addition, other nosocomial infections contributed to the underlying disease, making it difficult to identify the pathogen. Based on the fact that a pathological fracture with a displacement on the left and destructive processes as a result of infection occurred, it all prevented the femur from healing. Unfortunately, after long and unsuccessful attempts, the only solution came from limb amputation and broad-spectrum antibiotic therapy, which, for the better, completely stopped the spread of the infection. Preventive fixation was performed in the right thigh, which, even after a pathological fracture, prevented the bone from displacing and the bone healed completely. It is now known that the patient is fully recovered and no longer shows signs of osteomyelitis.

REFERENCES

- 1 **Strecker W**, Russ M, Schulte M. [Hematogenous osteomyelitis in adults]. *Orthopade* 2004; **33**: 273-286 [PMID: 15007552 DOI: 10.1007/s00132-003-0601-4]
- 2 **García Del Pozo E**, Collazos J, Cartón JA, Camporro D, Asensi V. Bacterial osteomyelitis: microbiological, clinical, therapeutic, and evolutive characteristics of 344 episodes. *Rev Esp Quimioter* 2018; **31**: 217-225 [PMID: 29756429]
- 3 **Arias Arias C**, Tamayo Betancur MC, Pinzón MA, Cardona Arango D, Capataz Taffur CA, Correa Prada E. Differences in the Clinical Outcome of Osteomyelitis by Treating Specialty: Orthopedics or Infectology. *PLoS One* 2015; **10**: e0144736 [PMID: 26678551 DOI: 10.1371/journal.pone.0144736]
- 4 **Calhoun JH**, Manring MM, Shirliff M. Osteomyelitis of the long bones. *Semin Plast Surg* 2009; **23**: 59-72 [PMID: 20567728 DOI: 10.1055/s-0029-1214158]
- 5 Osteomyelitis, NORD (National Organization for Rare Disorders). Accessed Apr. 01, 2020. Available from: <https://rarediseases.org/rare-diseases/osteomyelitis/>
- 6 **Raff MJ**, Melo JC. Anaerobic osteomyelitis. *Medicine (Baltimore)* 1978; **57**: 83-103 [PMID: 618443 DOI: 10.1097/00005792-197801000-00006]
- 7 **Weber KL**. Evaluation of the adult patient (aged >40 years) with a destructive bone lesion. *J Am Acad Orthop Surg* 2010; **18**: 169-179 [PMID: 20190107 DOI: 10.5435/00124635-201003000-00006]
- 8 Osteomyelitis, Infectious Disease Advisor, Feb. 15, 2019. Accessed Apr. 03, 2020. Available from: <https://www.infectiousdiseaseadvisor.com/home/decision-support-in-medicine/infectious-diseases/osteomyelitis-4/>
- 9 **Fritz JM**, McDonald JR. Osteomyelitis: approach to diagnosis and treatment. *Phys Sportsmed* 2008; **36**: nihpa116823 [PMID: 19652694 DOI: 10.3810/psm.2008.12.11]
- 10 Anaerococcus - an overview | ScienceDirect Topics. Accessed Apr. 01, 2020. Available from: <https://www.sciencedirect.com/topics/medicine-and-dentistry/anaerococcus>
- 11 Thrombocytosis - Symptoms and causes, Mayo Clinic. Accessed Apr. 03, 2020 Available from: <https://www.mayoclinic.org/diseases-conditions/thrombocytosis/symptoms-causes/syc-20378315>
- 12 **Murphy EC**, Frick IM. Gram-positive anaerobic cocci--commensals and opportunistic pathogens. *FEMS Microbiol Rev* 2013; **37**: 520-553 [PMID: 23030831 DOI: 10.1111/1574-6976.12005]



Published by **Baishideng Publishing Group Inc**
7041 Koll Center Parkway, Suite 160, Pleasanton, CA 94566, USA

Telephone: +1-925-3991568

E-mail: bpgoffice@wjgnet.com

Help Desk: <https://www.f6publishing.com/helpdesk>

<https://www.wjgnet.com>

