

# Mummy Stories

## Dario Piombino-Mascali

Department of Anatomy, Histology and Anthropology,  
Institute of Biomedical Sciences, Faculty of Medicine,  
Vilnius University, 21 M. K. Čiurlionio St., LT-03101 Vilnius  
&

Wolfson College, University of Oxford,  
Linton Road, Oxford, OX2 6UD United Kingdom  
[dario.piombino@mf.vu.lt](mailto:dario.piombino@mf.vu.lt)

**Abstract.** This article represents a summary of the author's past 12 years of research on several mummy sets. As mummy studies expand as a sub-specialty of biological anthropology, it is important to highlight the significant contribution that the study of preserved remains can provide to both archaeology and history.

**Keywords:** death, mummification, bioarchaeology, paleopathology, taphonomy.

## Mumijų istorijos

**Anotacija.** Šiuo straipsniu autorius apibendrina savo pastarųjų 12 metų įvairių mumijų rinkinių tyrimus. Kadangi mumijų tyrimai plečiasi kaip biologinės antropologijos pagalbinė specialybė, svarbu išryškinti išlikusių palaikų tyrimų reikšmę tiek archeologijai, tiek istorijai.

**Raktažodžiai:** mirtis, mumifikacija, bioarcheologija, paleopatologija, tafonomija.

## Introduction

During my career in the field of paleopathology I have focused almost exclusively on the scientific study of human mummies, which represents an intriguing sub-discipline involving several specialists such as physicians, archaeologists, and of course, biological anthropologists (Aufderheide, 2003). Therefore, this brief overview is intended to summarize some of the most interesting mummy projects carried out by my research group and our closest collaborators.

But first of all, what is a mummy? The term derives from the Arabic word meaning bitumen, or peach, and that is due to the fact that such remains originating from Egypt show a peculiar dark color (Clark et al., 2016). As bitumen was believed to have some medical properties, this was one of the reasons why many mummies were ultimately destroyed in the past (Dannenfeldt, 1985). Nevertheless, the term mummy should commonly refer to a body with an overall preservation of soft tissue, and perhaps still with internal organs (Lynnerup, 2007). These kinds of remains are quite frequent in both an archaeological and forensic context, and in the latter case, are generally considered an indicator of social isolation (Campobasso et al., 2009).

Mummies can be broadly distinguished into two categories, those being natural (spontaneous) and artificial (anthropogenic) (Aufderheide, 2003; Nystrom, 2019). The first is generally the result of appropriate environmental conditions such as the cold or heat, lack of humidity, or the presence of heavy metals in the soil where bodies are buried. The second is determined by human activity, which may include the removal of internal organs (the parts that are most prone to decomposition) and the drying out of the body cavities (Lynnerup, 2007; Roberts, 2009).

**Received:** 18/09/2019. **Accepted:** 21/10/2019

Copyright © 2019 Dario Piombino-Mascali. Published by Vilnius University Press

This is an Open Access article distributed under the terms of the Creative Commons Attribution Licence, which permits unrestricted use, distribution, and reproduction in any medium, provided the original author and source are credited.



**Fig. 1.** Conrado Rodríguez-Maffiotte Martín, Arthur Aufderheide and Mary Aufderheide, some of the founding figures of the World Congress of Mummy Studies, at an exhibition in Bolzano, Italy.

*1 pav.* Conrado Rodríguez-Maffiotte Martín, Arthur Aufderheide ir Mary Aufderheide, vieni iš Pasaulinio mumijų tyrimų kongreso įkūrėjų, Bolzano parodoje, Italija

## Back to the roots

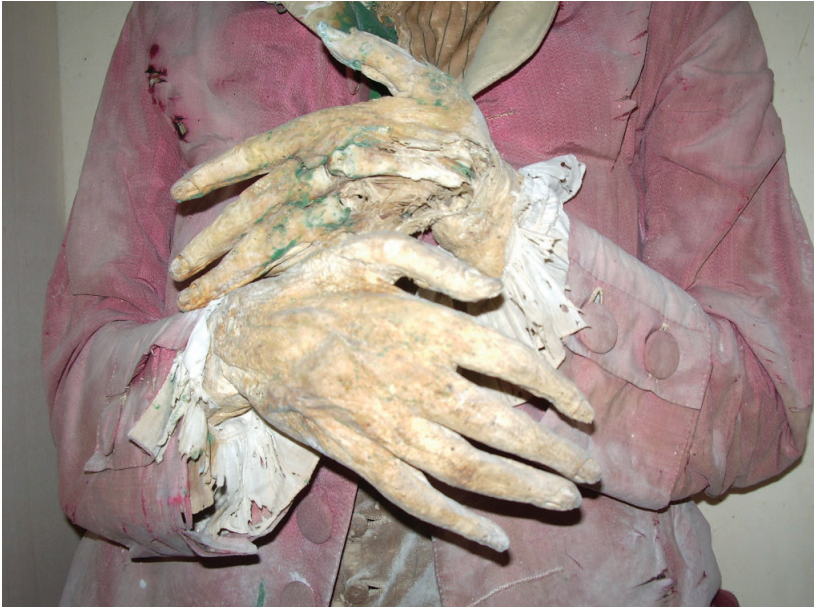The study of mummies is nothing new, but has a long and colorful history dating back to Napoleon's campaign in Egypt, when a number of scientists and specialists travelled with the army to document and study the enormous heritage of that country (Cardin, 2015). This also initiated the modern Western "Egyptomania", and many collectors started purchasing archaeological artefacts as well as, of course, mummies (Baber, 2016). Some of the earliest scholars devoted to mummy unrollings included Johann Blumenbach, Agostino Bozzi Granville, and Thomas Pettigrew, a medical doctor who autopsied several bodies and described the results in his landmark book *A History of Egyptian Mummies* (Moshenska, 2014). Later on, a Cairo-based British trio formed by Grafton Elliot Smith, Marc Armand Ruffer, and Alfred Lucas carried out important studies on ancient mummified remains, including the Royal mummies (Aufderheide, 2003). Around that time, Margaret Murray, while being the curator of Egyptology at the Manchester Museum, carried out the first interdisciplinary research of this kind, leading the way to other similar projects (Sheppard, 2012). New impetus to these studies was finally given by the creation of a mummy congress, active since 1992 and currently in its 10<sup>th</sup> iteration (Fig. 1).

As we will see, the study of mummies is enormously important and can yield a substantial amount of information on past lifestyle, behavior, mortuary practices, health and disease (Nystrom, 2019; Fernández et al., 2019). However, non-invasiveness is imperative, as past autopsies have irreparably compromised bodies that had been preserved for centuries or millennia, depriving them of their right to body integrity, or, in other words, the inviolability of the physical body (Kreissl Lonfat et al., 2015). Therefore, many of the techniques that were applied during the projects where I was involved are non-destructive or minimally destructive, including X-rays, CT-scans, and minimal sampling for further biomedical investigations. Let us now describe some of the mummy activities performed by my research group on such type of remains.

## Working in the heart of the Mediterranean Sea

The Sicily Mummy Project was created in 2007 to document and study the enormous quantity of mummified remains present in the sunny Mediterranean island of Sicily, which acts as an autonomous part of Italy. This project included not only biological anthropology, but also history, botany, chemistry, and even medicine to investigate a large sample of these bodies (Piombino-Mascali et al., 2011).

The Sicily mummies are scattered all around the island with a large concentration of sites in the north-east corner. There, some of the most popular touristic locations are also present, such as Savoca and Piraino (Fig. 2).



**Figure 2.** The beautifully preserved hands of one of the Savoca mummies that were investigated within the framework of the Sicily Mummy Project, Italy.

*2 pav. Vienos iš Savokos mumijų, tirtų įgyvendinant Sicilijos mumijų projektą, puikiai išlikusios rankos, Italija*

However, the largest site is that of the Capuchin Catacombs of Palermo, where over 1800 bodies are either located along the walls or stored in coffins (Fig. 3). The site was created in 1599 and was shut down in 1880, although some remains were located there for the following 70 years (Piombino-Mascali, 2017). It is probably the largest collection of mummies. In addition to the remains, there are many other artefacts that indicate the attitudes of Sicilian people toward death, including textiles, gravestones, and elaborate coffins (Cardin, 2015).

In many cases, preservation was so remarkable that it was impossible to think of those remains as the result of nature. Therefore, in 2008, we selected 10 such mummies and submitted them to conventional X-ray analysis. This technique was adopted in the field of mummy studies since the late 19<sup>th</sup> century, having been for almost 80 years the only method to “look inside” the specimens (Lynnerup, 2007; Panzer et al., 2010).

In one case, for instance, we found proof that a mummy was chemically treated by seeing the presence of a dense, crumbly material located in the subclavian artery, as well as evidence of a tampon in the anus and foreign objects in the eyes. This specific individual was also of paleopathological relevance, because he had suffered from Marfan syndrome during life (Panzer et al., 2018).

We were also able to assess a sort of “arterial angiography” of almost 200 years ago, illustrating the aorta and other vessels. In this specific case, the presence of a lesion in the thigh indicated that the artery that was risen to inject the cadaver was the femoral one. Additionally, there was a presence of foreign objects in the mouth, the nose and the eyes, as well as other ornaments from clothes. Again, in this assemblage, we could appreciate the preservation of some internal organs, such as the liver and brain, and the presence of a tampon in the anus (Panzer et al., 2010).

The mummy of a child was especially striking because we managed to assess, beyond the evidence of embalming, the presence of a form of dwarfism, first described in 1969 and called Robinow syndrome, which is also known as “fetal face syndrome” (Panzer et al., 2010).

Finally, the case of Rosalia Lombardo, which is probably the most known in the Catacombs, revealed the presence of internal organs, which appeared well-preserved, but the metal lining of the coffin did not allow for further information (Panzer et al., 2010).

Therefore, two years later, we submitted this child to a CT-scan, and realized that the organs were preserved and almost comparable to those of a living person (Fig. 4). The formula used to preserve her was also of interest because it was one of the earliest examples of the use of formalin for embalming purposes (Panzer et al., 2013a).

However, the mummies in Palermo are by no means the only ones that were investigated.



**Fig. 3.** One of the Palermo mummies during a CT investigation carried out *in situ* via a portable unit, Italy.

**3 pav.** Viena iš Palermo mumijų kompiuterinės tomografijos tyrimo, atlikto vietoje kilnojamo prietaisu, metu, Italija

In the town of Savoca, cases were found of DISH and gout. The former is a “dripping candle wax” ossification of the spine that has been related to a “monastic” or high status way of life, which may have led to diabetes and obesity (Waldron, 2009). A rich diet was the likely cause for the presence of gout (including meat, alcohol, and sugar). This appears to be confirmed by the historical documents that we were able to inspect, indicating that nutritional factors may have caused the onset of these conditions (Piombino-Mascali et al., 2015a).

In Piraino, another medieval town, we studied another 23 mummies revealing again cases of DISH and other pathological conditions, including a subject showing a form of cancer (Piombino-Mascali et al., 2017).

In this specific case, we also found a coprolite that was analyzed and revealed remnants of food, the presence of a large quantity of parasites, as well as pollen of polygala, a plant traditionally used to cure bone pain and also expectorate (Figs. 5–7) (Kumm et al., 2010). In all likelihood, this indicates that the subject enjoyed a sophisticated access to care (Nystrom and Piombino-Mascali, 2017).



**Fig. 4.** Some members of the team of the Sicily Mummy Project during the investigation of little Rosalia Lombardo. These included Dr Albert Zink and Dr Steffi Panzer, Italy.

*4 pav. Sicilijos mumijų projekto komandos nariai, tyrę mažąją Rosalia Lombardo. Tarp jų dr. Albert Zink ir dr. Steffi Panzer, Italija*




**Fig. 5.** Analyses of a coprolite associated with a mummy at Piraino revealed the presence of what appears to be a fragment of animal intestine, USA.

*5 pav. Koprolitų analizė leido nustatyti gyvūno žarnos fragmentą Piraino mumijoje, JAV*

## Bodies of stone and medical mummies

Another category of mummies that we investigated are the so-called medical mummies: bodies that were artificially produced for medical education, anatomical collection, as well as artistic practice. We know of several examples of such mummies, including those prepared by Girolamo Segato, a scientist who travelled to Egypt and then dedicated himself to anatomical preparations. Some of his specimens were so hardened that his process was compared to real petrification, a nickname still used today to describe these items. A table, probably his most famous achievement, has the surface made up of petrified slices of internal organs. Despite his celebrity, Segato died prematurely and took his secret with him to the grave (Lippi and Weber, 2014).

Shortly after his death, many other scientists tried to emulate him, among whom was Giovan Battista Rini, a doctor from Salò (Lake Garda). In 2010 we were able to inspect eight of his specimens via CT-scan, and were also able to apply the Hounsfield unit scale (Fig. 8). This scale measures the density of objects through the different scales of grey and gives clues about what materials they are made of (Piombino-Mascali, 2018). In this case, we managed to differentiate the items into “dry preparations” and “corrosion preparations” (the latter having being deprived of the cutis and subcutis to show the underlying structures). We learned that the brain could be removed, and in one such case this was obtained via trepanation and the inclusion of a cord soaked in



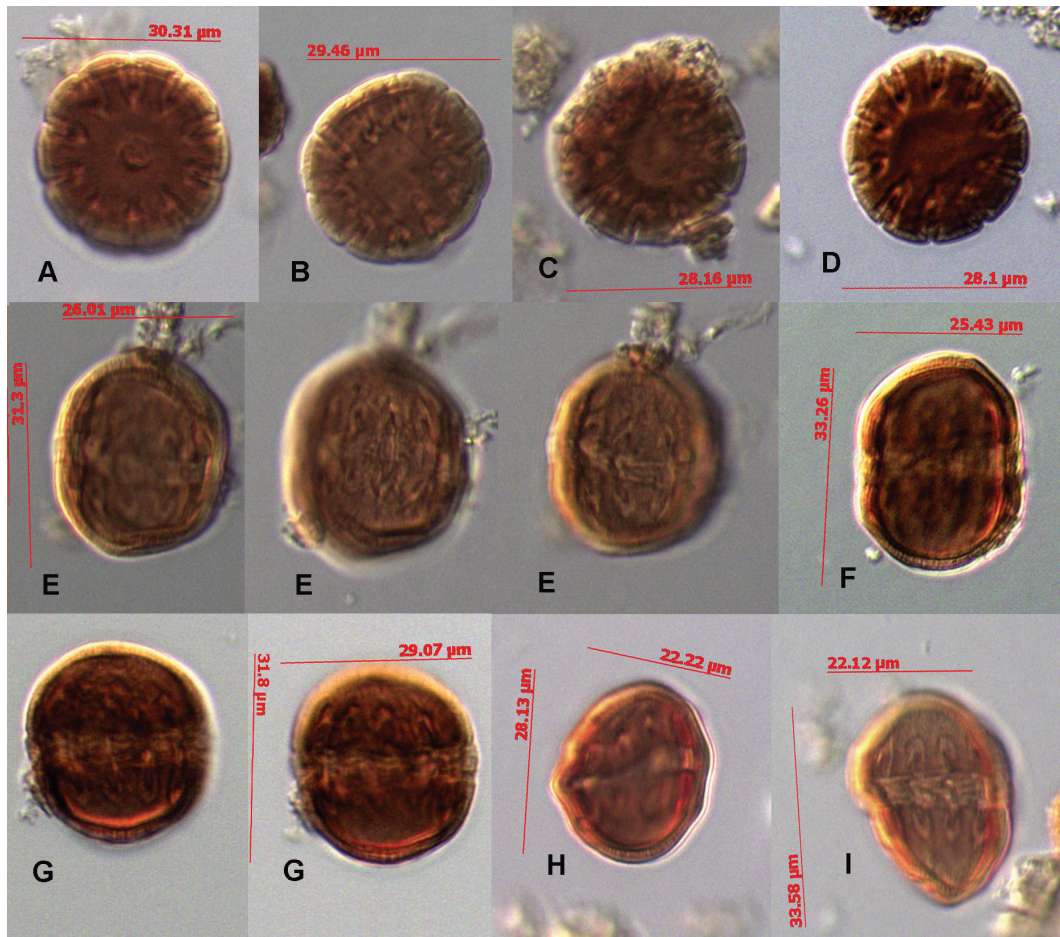
**Fig. 6.** Studies headed by Dr Karl Reinhard revealed a large quantity of human whipworm eggs, USA  
**6 pav.** Tyrimų, atliktų vadovaujant dr. Karlui Reinhardui, metu rastas didelis žmoginio plaukagalvio kiaušinėlių kiekis, JAV

chemicals. We also learned that arteries could be filled with wax, and that based on the density, the specimens were similar to renal stones; hence, the name “petrification” was justified. However, the only stone-like object was the heart, as all other specimens felt like wood (Piombino-Mascali, 2018).

Another anatomical collection that we recently investigated was that of the mental asylum of Milan in Mombello, where during the early 20<sup>th</sup> century Dr Giuseppe Paravicini dissected bodies of dead patients. Paravicini was a pathologist who claimed to have discovered a novel method for preparing anatomical specimens (Quigley, 1998). Currently, his collection consists of two entire bodies, several busts, brains, and two small animals. As many such mummies showed beautifully preserved hair, we decided to take samples in order to carry out a toxicological study. Results of LC-MS analyses showed that the hair contained caffeine, nicotine, and even cocaine, which was in all likelihood used as a form of therapy within that hospital. Historical evidence also corroborated our findings (Musshoff et al., 2017).

## A Baltic experience

Since 2011, the Anthropology Lab of Vilnius University has been conducting research on the mummies held in the city of Vilnius, Lithuania, including those from the crypt of the Dominican Church of the Holy Spirit. Those mummies, who belong to the middle-upper society of the 18<sup>th</sup> and 19<sup>th</sup> century Vilnius, were first inspected during the Polish occupation of Lithuania in the 1930s. Sadly, much of the information gathered at this time was lost. In the 1960s, during the Soviet times, a local forensic scientist, Juozas Markulis, inspected the bodies. However, the decision to sequester most of the remains in a single room and close them in a wall made of bricks and a glass window resulted in the complete loss of those mummies (Cardin, 2015).



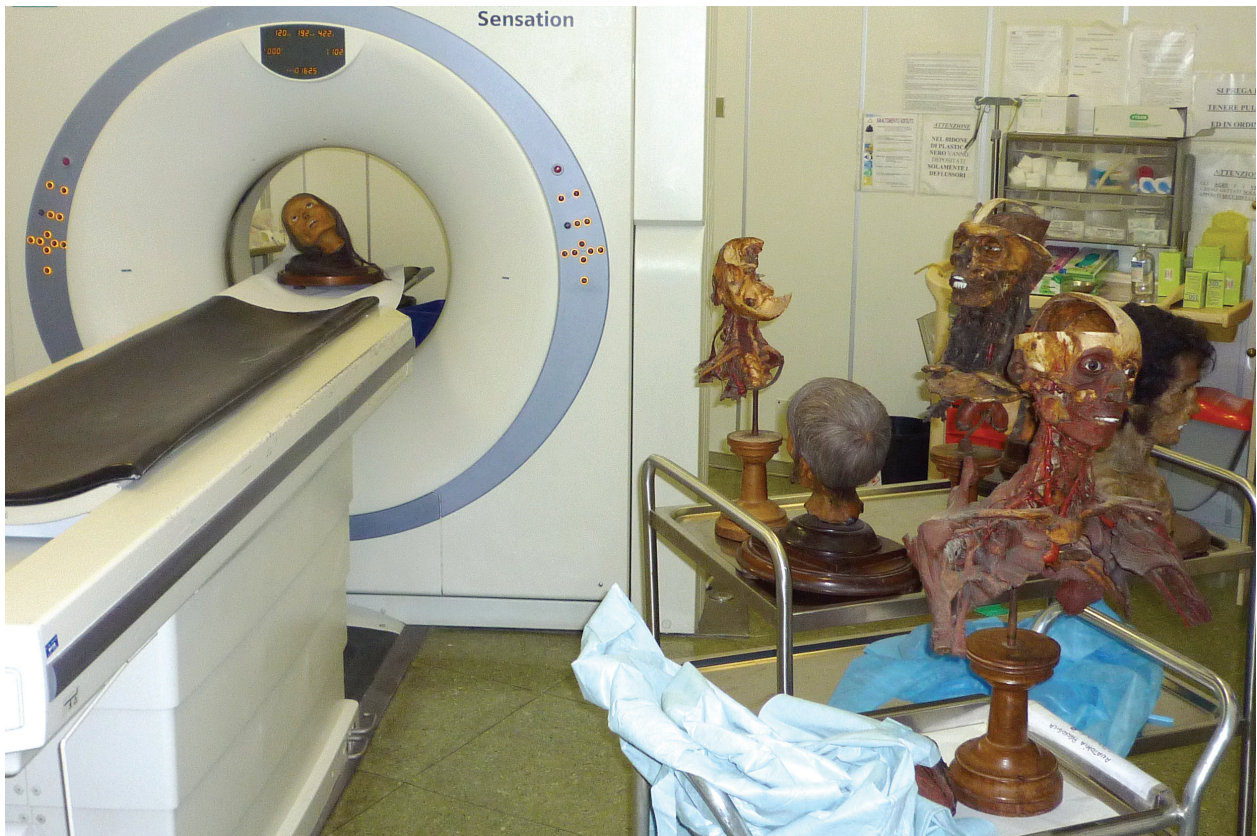**Fig. 7.** The investigation of this mummy also revealed consumption of pollen of polygala, which was probably ingested as a form of infusion, USA.

*7 pav. Tiriant šią mumiją taip pat rasta putokšlės žiedadulkių, kurios galėjo būti vartojamos kaip užpilas, JAV*

Some years ago, we were given the opportunity to inspect and study the remaining 23 bodies spared from decomposition, a task which continues today (Fig. 9). Therefore, together with a number of colleagues of different backgrounds, we CT-scanned the seven best-preserved mummies and were able to sample the others due to a lack of outer tissue, which enabled the sampling of internal organs. At the end of the study, the mummies were brought back to the crypt, where they still rest today (Cardin, 2015).

One of the main results of the imaging study was the assessment of tuberculosis, which did not affect the bones, but was visible on the soft tissue in the form of calcifications of the lungs and pleural adhesions indicating a healed inflammatory process. The most likely explanation for this evidence was lung tuberculosis, which is historically documented in Lithuania for the period concerned (Piombino-Mascali et al., 2015b).

Additionally, three of the mummies showed evidence of atherosclerosis, an accumulation of fat along the walls of the arteries, at times very severe. This condition has generally been reappraised as a consequence of the normal ageing process, but indeed the Vilnius mummies demonstrate that in some cases diet and behavior played a significant role (Thompson et al., 2013). In order to have a better clue, we used the letters of Georg Foster, a German professor of natural history at Vilnius University. Foster was complaining about the lack of vegetables, fruit and greens, how the food was mainly formed by meat and prepared with animal fat, and that the locals were drunk at least once a week (Foster, 1988).



**Fig. 8.** The medical mummies produced by Giovan Battista Rini during the CT investigation at the Desenzano-Lonato Hospital, Italy.

**8 pav.** *Giovano Battistos Rini medicininės mumijos kompiuterinės tomografijos tyrimo metu Italijos Desenzano-Lonato ligoninėje, Italija*

Bone conditions were also found, among which a case of hydrocephalus associated with rickets stands out (Panzer et al., 2013b). The child with these conditions may have been prohibited to go out of home due to her disorder, which may have led to the lack of sun exposure and the consequent onset of rickets, which is a defect of ossification due to a lack of vitamin D. Other abnormalities included arthritis, neoformations, variants such as a hole in the sternum, or some occupational condition such as the *os acromiale*. Scoliosis and *hallux valgus* were also found (Piombino-Mascoli et al., 2014).

More recently, we started to investigate the samples by extracting and amplifying ancient DNA; one of the children was found to be positive for variola virus. A comparison with more recent DNA of variola samples showed that our sample is basal to all other data, indicating that the story of this condition may be more recent than previously thought (Wertheim, 2017).

### An exotic Egyptian chapter

Within the Lithuanian collection were several Egyptian mummies which were CT-scanned and included in the project. The results were surprising. Two mummies, thought to be children from the Greco-Roman period, were studied. One contained no human remains whatsoever, while the other contained only one adult hand. However, the most interesting discovery was the presence of tin foil located beneath the paint on the bundle. As tin was industrially produced only during the Modern Age, it is believed that these mummies are fakes, manufactured to be sold to tourists as a souvenir around the period of 1700–1800 (Piombino-Mascoli et al., 2013–2014).





**Fig. 9.** One of the 23 mummies recovered from the crypt of the Dominican Church at Vilnius, Lithuania.

*9 pav. Viena iš 23 mumijų, rastų Vilniaus Dominikonų bažnyčios rūsiuose, Lietuva*



**Fig. 10.** The Kaunas mummy during conservation works at Vilnius. Once believed to be those of a woman, the remains actually belonged to a man of lower social status, Lithuania.

*10 pav. Kauno mumijos konservavimo darbai Vilniuje. Palaikai, iš pradžių traktuoti kaip moters, iš tiesų priklausė žemesnio socialinio statuso vyrui, Lietuva*

Another interesting mummy was one belonging to the King of Poland in the 17<sup>th</sup> century, which was finally relinquished to the Vilnius Museum of Antiquities at the end of the 19<sup>th</sup> century. Interestingly, while the coffin is dated to the 21<sup>st</sup> dynasty of Egypt, the mummy undoubtedly dates to the Roman period as evidenced by the wrapping, although it is impossible to guess at what point in time the coffin had been reused (Piombino-Mascoli et al., 2016).

Striking is also the case of the Kaunas mummy, purchased by the first Lithuanian Egyptologist, Marija Rudzinskaitė-Arcimavičienė, who brought the item to Lithuania. Until the late 20<sup>th</sup> century, the mummy was believed to belong to a princess called Shemait (Fig. 10). However, the CT investigation revealed a different story. First of all, bundles with a palm mat underneath are associated with poor status burials; second, the mummy belongs to a man, who was probably skeletonized and then wrapped in the bundle. Additional elements were found within the bundle, suggesting there may be more than just the individual wrapped inside. A small bottle of lavender oil, sourced from Crimea, Ukraine, was found during the CT-scanning process. It was likely placed there by Rudzinskaitė-Arcimavičienė, with the intent of creating a mystifying environment, which is supported by recent biographical research (Piombino-Mascoli et al., 2015c).

## Conclusions

Although mummy studies continues to intrigue researchers, students, and the general public, its academic position as a discipline is still unclear. This specialty should rightfully be nested within the wider field of biological anthropology, and so has been incorporated more into this and other curricula since the beginning of the new millennium (Nystrom, 2019). Modules and courses on the subject have started to be offered in several universities, including those of Manchester, York, Camerino, Pisa, Tartu, Quinnipiac, and the University of Western Ontario.

Furthermore, the unique experience of receiving intensive training in soft tissue paleopathology was provided by the first Mummy Studies Field School, active in the years 2016–2018 in the Sicilian town of Santa Lucia del Mela, and organized in collaboration with the University of Nebraska-Lincoln. The participants were able to apply their knowledge of osteology to real mummy subjects, and learn paleopathology based on actual subjects exhibiting distinctive pathologies of the region. They also investigated other aspects of the mummy environment through palynology and parasitology, while having meaningful conversations concerning the ethics behind human remains display and conservation. Guest speakers gave talks on different aspects of mummy studies, and hands-on modules, such as facial reconstruction, helped make a well-rounded educational experience. This program was offered to students from several American universities as well as to visiting scholars from different countries and backgrounds.

In summary, all of these activities bode well for a shift toward improved professionalism, and it is hoped that this brief overview of some of our projects has stressed the importance of studying preserved remains, which, if properly conducted, can provide relevant and valuable information.

## Acknowledgements

The title of this short overview was inspired by the website of my friend Dr Angela Stienne, a young and passionate mummy scholar. I am also grateful to my former student Haley Carr, MSc, for language editing. Images belong to the author's personal archive.

## Bibliography

- Aufderheide A. C. 2003. *The Scientific Study of Mummies*. Cambridge: Cambridge University Press.
- Baber T. T. 2016. Ancient corpses as curiosities: Mummymania in the age of early travel. *Journal of Ancient Egyptian Interconnections*, 8, p. 60–93.
- Campobasso C. P., Falamingo R., Grattalano I., Vinci F. 2009. The mummified corpse in a forensic setting. *American Journal of Forensic Medicine and Pathology*, 30, p. 307–310. DOI: <https://doi.org/10.1097/paf.0b013e318187df4b>.
- Cardin M. 2015. *Mummies around the World*. Santa Barbara: ABC Clío.
- Clark K. A., Ikram S., Evershed R. P. 2016. The significance of petroleum bitumen in ancient Egyptian mummies. *Philosophical Transactions A*, 374, 20160229. DOI: <https://doi.org/10.1098/rsta.2016.0229>.
- Dannenfeldt K. H. 1985. Egyptian mummy: The sixteenth century experience and debate. *The Sixteenth Century Journal*, 16 (2), p. 163–180. DOI: <https://doi.org/10.2307/2540910>.
- Fernández P. L., Esteban J., Franco A. 2019. Paleopathology of soft tissues: What mummies can reveal. *Polish Journal of Pathology*, 70 (1), p. 44–48. DOI: <https://doi.org/10.5114/pjp.2019.84462>.
- Forster G. 1988. *Laiškai iš Vilniaus*. Vilnius: Mokslas.
- Kreissl Lonfat B. M., Kaufmann I. M., Rühli F. J. 2015. A code of ethics for evidence-based research with ancient human remains. *The Anatomical Record*, 298, p. 1175–1181. DOI: <https://doi.org/10.1002/ar.23126>.
- Kumm K., Reinhard K. J., Piombino-Mascali D., Araújo A. 2010. Archaeoparasitological investigation of a mummy from Sicily (18<sup>th</sup>–19<sup>th</sup> century AD). *Anthropologie*, 48, p. 177–184.
- Lippi D., Weber D. 2014. Between horror and science. Girolamo Segato's strange anatomy (1792–1836). *Journal of Morphological Sciences*, 31 (1), p. 51–53. DOI: <https://doi.org/10.4322/jms.cc056213>.
- Lynnerup N. 2007. Mummies. *Yearbook of Physical Anthropology*, 50, p. 162–190. DOI: <https://doi.org/10.1002/ajpa.20728>.
- Moshenska G. 2014. Unrolling Egyptian mummies in nineteenth century Britain. *British Journal for the History of Science*, 47 (3), p. 451–477. DOI: <https://doi.org/10.1017/s0007087413000423>.
- Musshoff F., Fels H., Carli A., Piombino-Mascali D. 2017. The anatomical mummies of Mombello: Detection of cocaine, nicotine and caffeine in the air of psychiatric patients of the early 20<sup>th</sup> century. *Forensic Science International*, 270, p. 20–24. DOI: <https://doi.org/10.1016/j.forsciint.2016.11.011>.
- Nystrom K. C. 2019. *The Bioarchaeology of Mummies*. New York: Routledge.
- Nystrom K. C., Piombino-Mascali D. 2017. Mummy studies and the soft tissue evidence of care. L. Tilley and A. Schrenk (eds.) *New Developments in the Bioarchaeology of Care*. Springer, Cham, p. 199–218. DOI: [https://doi.org/10.1007/978-3-319-39901-0\\_10](https://doi.org/10.1007/978-3-319-39901-0_10).
- Panzer S., Zink A. R., Piombino-Mascali D. 2010. Radiologic evidence of anthropogenic mummification in the capuchin catacombs of Palermo, Sicily. *Radiographics*, 30 (4), p. 1123–1132. DOI: <https://doi.org/10.1148/rg.304095174>.
- Panzer S., Gill-Frerking H., Rosendahl W., Zink A., Piombino-Mascali D. 2013a. CT investigation of the mummy of Rosalia Lombardo (1918–1920). *Annals of Anatomy*, 195, p. 401–408. DOI: <https://doi.org/10.1016/j.aanat.2013.03.009>.
- Panzer S., Tamošiūnas A., Valančius R., Jankauskas R., Piombino-Mascali D. 2013b. Radiological evidence of rickets in a Lithuanian child mummy. *Röfo*, 185 (7), p. 670–672. DOI: <https://doi.org/10.1016/j.ijpp.2018.05.002>.
- Panzer S., Thompson R. C., Hergan K., Zink A. R., Piombino-Mascali D. 2018. Evidence of aortic dissection and Marfan syndrome in a mummy from the capuchin catacombs of Palermo, Sicily. *International Journal of Paleopathology*, 22, p. 78–85. DOI: <https://doi.org/10.1016/j.ijpp.2018.05.002>.
- Piombino-Mascali D. 2017. The lovely bones: Capuchin catacombs of Palermo. C. Rodríguez-Maffiotte Martín (editor), *Athanatos. Inmortal. Muerte e inmortalidad en poblaciones del pasado*. Tenerife: Cabildo de Tenerife, p. 127–131.
- Piombino-Mascali D. 2018. A comparison between Giovan Battista Rini and Paolo Gorini. *Acta Medico-Historica Adriatica*, 16 (1), p. 145–156. DOI: <https://doi.org/10.31952/amha.16.1.7>.
- Piombino-Mascali D., Panzer S., Marvelli S., Lösch S., Aufderheide A. C., Zink A. R. 2011. The “Sicily Mummy Project”: First results of the scientific campaigns (2007–2010). *Kasseler Studien zur Sepulkralkultur*, 18, p. 25–31.
- Piombino-Mascali D., Jankauskas R., Snitkuvienė A., McKnight L., Longo M., Longo S. 2013–2014. Radiological assessment of two pseudo-mummies from the National Museum of Lithuania. *Journal of the Society for the Study of Egyptian Antiquities*, 40, p. 69–77. DOI: <https://doi.org/10.1127/anthranz/2016/0593>.
- Piombino-Mascali D., Kozakaitė J., Tamošiūnas A., Valančius R., Panzer S., Jankauskas R. 2014. Skeletal pathological conditions of Lithuanian mummies. *Papers on Anthropology*, 23 (1), p. 118–126. DOI: <https://doi.org/10.12697/poa.2014.23.1.10>.
- Piombino-Mascali D., Jankauskas R., Zink A. R., Todesco M. S., Aufderheide A. C., Panzer S. 2015a. Paleoradiology of the Savoca mummies, Sicily, Italy (18<sup>th</sup>–19<sup>th</sup> centuries AD). *The Anatomical Record*, 298 (6), p. 988–1000. DOI: <https://doi.org/10.1002/ar.23132>.

- Piombino-Masali D., Jankauskas R., Tamošiūnas A., Valančius R., Gill-Frerking H., Spigelman M., Panzer S. 2015b. Evidence of probable tuberculosis in Lithuanian mummies. *Homo*, 66 (5), p. 420–431. DOI: <https://doi.org/10.1016/j.jchb.2015.01.004>.
- Piombino-Masali D., McKnight L., Snitkuvienė A., Tamošiūnas A., Valančius R., Rosendahl W., Panzer S. 2015c. From Egypt to Lithuania: Marija Rudzinskaitė-Arcimavičienė's mummy and its radiological investigation. S. Ikram, J. Kaiser and R. Walker (eds.) *Egyptian Bioarchaeology*. Leiden: Sidestone Press, p. 95–104.
- Piombino-Masali D., Jankauskas R., Snitkuvienė A., Rutkauskas T., Sutherland L. M. 2016. Radiological and archaeological investigation of a mummy from Roman Egypt curated in the National Museum of Lithuania. *Anthropologischer Anzeiger*, 73 (1), p. 69–79. DOI: <https://doi.org/10.1127/anthranz/2016/0593>.
- Piombino-Masali D., Zink A. R., Panzer S., 2017. Paleopathology in the Piraino mummies as illustrated by X-rays. *Anthropological Science*, 125 (1), p. 25–33. DOI: <https://doi.org/10.1537/ase.160916>.
- Quigley C. 1998. *Modern Mummies*. McFarland & Company, Jefferson.
- Roberts C. A. 2009. *Human Remains in Archaeology*. York: Council for British Archaeology.
- Sheppard K. L. 2012. Between spectacle and science: Margaret Murray and the tomb of the Two Brothers. *Science in Context*, 25 (4), p. 525–549. DOI: <https://doi.org/10.1017/s0269889712000221>.
- Thompson R. C., Allam A. H., Lombardi G. P. et al. 2013. Atherosclerosis across 4000 years of human history: The Horus study of four ancient populations. *The Lancet*, 381, p. 1211–1222. DOI: <https://doi.org/10.1016/j.jvs.2013.06.006>.
- Waldron T. 2009. *Palaeopathology*. Cambridge: Cambridge University Press.
- Wertheim J. O. 2017. Viral evolution: Mummy virus challenged presumed history of smallpox. *Current Biology*, 27 (3), p. R119–R120. DOI: <https://doi.org/10.1016/j.cub.2016.12.008>.

## Mumijų istorijos

### Dario Piombino-Masali

#### Santrauka

Mumijos yra žmonių palaikai su išlikusiais minkštaisiais audiniais. Dėl gamtinių veiksnių sukeltos mumifikacijos atsiranda vadinamosios natūralios mumijos, o žmogui įsikišus į mumifikacijos procesą, atsiranda vadinamosios dirbtinės mumijos. Būdamos ypač gerai išlikusios, mumijos gali suteikti daug įžvalgų apie laidojimo praktikas ir papročius. Būtent, minkštųjų audinių buvimas gali išplėsti paleopatologinių tyrimų aprėptį. Daugelis naujų mumijų tyrimų sutelkti į neardančių metodų, kaip antai radiografija, kompiuterinė tomografija, endoskopijos technologijos, plėtojimą ir taikymą, taip pat į minimaliai ardančius analitinius metodus. Šis straipsnis pateikia trumpą mumijų tyrimų istoriją, jame aptariami skirtingi mumijų projektai, skirti palaikams iš Sicilijos, Šiaurės Italijos, Lietuvos ir Egipto; apžvelgiami pagrindiniai atradimai, pasiekti tiriant mumijas. Be to, parodoma, kaip mumijų tyrimai prisidėjo prie žinių apie praeities populiacijų gyvenimą ir mirtį gausėjimo.

Vertė *Agnius Urbanavičius*