

Successful extracorporeal membrane oxygenation assisted revascularisation in a high-risk elderly patient refused surgical treatment

Robertas Samalavičius¹,

Lina Puodžiukaitė^{2*},

Vytautas Abraitis³,

Ieva Norkienė²,

Nadežda Ščupakova¹,

Justina Pekarskienė¹,

Aleksejus Zorinas³,

Kęstutis Ručinskas³,

Pranas Šerpytis³

¹ 2nd Department of Anaesthesiology,
Centre of Anaesthesiology,
Intensive Care and Pain Management,
Vilnius University
Hospital Santaros Klinikos,
Vilnius, Lithuania

² Clinic of Anaesthesiology
and Intensive Care,
Faculty of Medicine,
Vilnius University,
Vilnius, Lithuania

³ Clinic of Cardiac and Vascular Diseases,
Faculty of Medicine,
Vilnius University,
Vilnius, Lithuania

Management of high-risk elderly patients requiring revascularisation remains a clinical challenge. We report a case of extracorporeal membrane oxygenation (ECMO) assisted complex percutaneous coronary intervention in a high-risk octogenarian. An 83-year-old female with signs of worsening heart failure was admitted to the emergency department of a tertiary care facility. Transthoracic echocardiography revealed a decreased left ventricular ejection fraction of 20% with severe mitral regurgitation and mild aortic and tricuspid valve insufficiency. Three-vessel disease was found during coronary angiography. Due to the patient's frailty, a high-risk surgery decision to proceed with ECMO assisted percutaneous coronary intervention was made during a heart team meeting. Following initiation of mechanical support, coronary lesions were treated with three drug-eluting stents. After the procedure, the patient was transferred to the ICU on ECMO support, where she was successfully weaned from the device 9 h later. Her ICU stay was four days. She was successfully discharged from the hospital after uneventful recovery. At one-year's follow-up, the patient was clinically stable in an overall state of general well-being and with complete participation in routine activities; she had good exercise tolerance and no signs of ischemia. This report highlights the possibility of use of ECMO during PCI in high-risk elderly patients.

Keywords: ECMO, percutaneous coronary intervention, coronary artery disease, elderly patient

* Correspondence to: Lina Puodžiukaitė, Clinic of Anaesthesiology and Intensive Care, Vilnius University, Faculty of Medicine, Užupio St. 8-8, Vilnius 01200, Lithuania. Email: l.puodziukaite@gmail.com

INTRODUCTION

The management of high-risk elderly patients with multiple comorbidities is challenging. The guidelines of the European Society of Cardiology and the European Association for Cardio-Thoracic Surgery on myocardial revascularization indicate the need for concomitant repair of severe mitral regurgitation at the time of coronary artery bypass grafting surgery (1). Although physical and psychological recovery of elderly surgery survivors and their quality of life are encouraging, the individual choice of optimal treatment for high-risk fragile elderly patient remains controversial. The use of extracorporeal life support in adult patients has increased dramatically during recent years (2). It is becoming more utilised for the treatment of cardiogenic shock related to an acute myocardial infarction (3). We herein report a case of an octogenarian patient with severely decreased left ventricular ejection fraction, severe mitral regurgitation, mild aortic and tricuspid valve insufficiency, and three-vessel disease. She successfully underwent extracorporeal membrane oxygenation (ECMO) assisted complex percutaneous coronary intervention.

CASE PRESENTATION

An 83-year-old female patient with Canadian Cardiovascular Society grade III angina and worsening symptoms of heart failure was admitted to a tertiary referral hospital for cardiac evaluation. She had a history of myocardial infarction and reported a deterioration of her health status for about two months prior to this admission. She was in functional NYHA class IV. Laboratory workup revealed haemoglobin of 94 g/l, creatinine clearance of 55 ml/min, and BNP of 1213 ng/l. Transthoracic echocardiographic examination performed on admission showed a decreased left ventricle function with an ejection fraction of 20%, severe mitral regurgitation, and mild aortic and tricuspid valve regurgitation (Fig. 1A). Coronary angiography revealed 75% stenosis of the proximal right coronary artery (RCA) segment, occlusion of the mid-RCA, 75% stenosis of the left main (LM) coronary artery, and stenoses of the proximal left anterior descending (LAD) artery (75%), first diagonal branch (D1) (75%), proximal circumflex

artery (50%), and first obtuse marginal branch (50%) (Fig. 1B and 1C).

Treatment options were evaluated at a multidisciplinary team meeting. Due to the patient's advanced age and high risk of corrective surgery (the predicted EuroSCORE II for combined mitral valve replacement and myocardial revascularization of 17%), the decision was made to perform a palliative procedure: extracorporeal membrane oxygenation (ECMO) supported percutaneous coronary intervention (PCI). The patient was transferred to the catheterisation laboratory. Following intubation under fluoroscopy-guided conditions, the size of the femoral artery was evaluated and percutaneous femoral implantation of 16 Fr arterial and 22 Fr venous cannulas were performed. Venous-arterial ECMO was initiated at a flow of 2.5–3.1 l/min. Angiography confirmed adequate blood flow distal to arterial cannula placement; no additional limb perfusion cannula to prevent limb ischemia was used. Low dose dobutamine infusion (5 mcg/kg/min) was initiated to facilitate left ventricle unloading. Trans-femoral access was used for PCI. Stenoses of LAD and D1 were treated by implanting two drug-eluting stents (DES) (cullote technique), and stenoses of LM and proximal LAD were treated by implanting an additional DES (Fig. 1D). At the end of the procedure, the retrograde RCA CTO PCI was not attempted in the view of the accumulated procedural time of the LM and LAD bifurcational PCIs. After the procedure, ECMO support could not be discontinued immediately due to systemic anticoagulation, which would interfere with successful cannula removal. According to the preliminary plan of the management of the patient and trying to shorten her stay in the busy catheterisation laboratory, the patient was transferred to the cardiac intensive care unit (ICU) with ongoing mechanical support. Standard monitoring included ECG, pulse oximetry, radial arterial pressure monitoring, and a oropharyngeal temperature probe. Additionally, near-infrared spectroscopy (NIRS) with sensors placed on both legs was used to monitor for signs of lower limb ischemia. The same evening, the patient was gradually weaned from ECMO support. Venous and arterial cannulas were removed and bleeding controlled by applying topical manual pressure for 1 h followed by mechanical compression. The duration

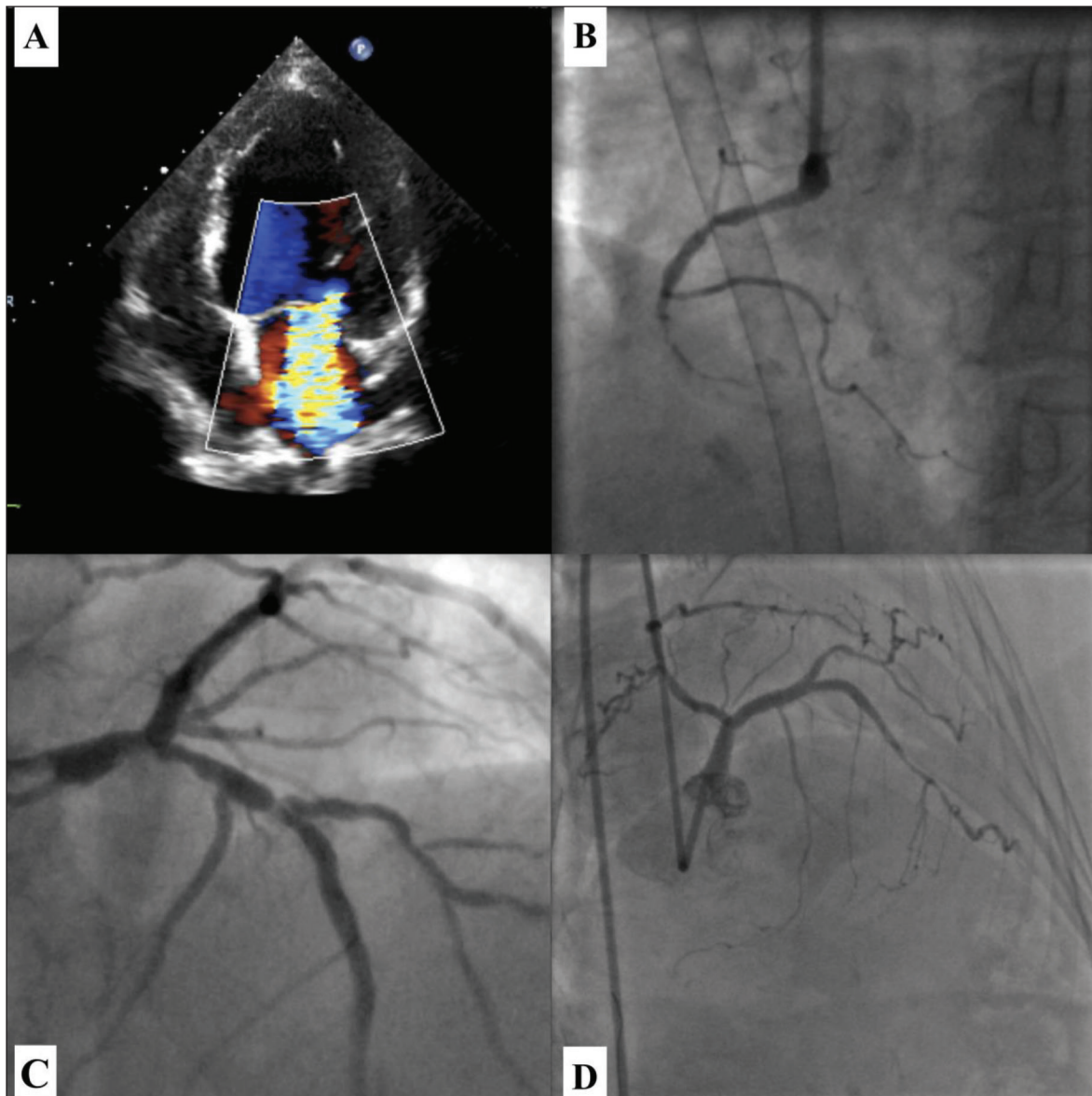


Figure. (A) Transthoracic echocardiography (TTE) showing severe mitral regurgitation. (B) Coronary angiography showing chronic total occlusion (CTO) of the right coronary artery (RCA). (C) Coronary angiography showing severe left main (LM) and left anterior descending artery (LAD) bifurcation (Medina Class: 1, 1, 0) stenosis prior to percutaneous coronary intervention. (D) Left main (LM) and left anterior descending artery (LAD) after successful implantation of drug-eluting stents (DES), the result of restored flow and final percutaneous coronary intervention (PCI). The spasm in the mid-LAD is visible

of ECMO was 9 h. She was weaned from mechanical lung ventilation and extubated 48 hours following the procedure. The ICU stay was four days. She had an uneventful recovery, was successfully discharged from the hospital, and was doing well with no symptoms of angina at a six-months' follow-up. Transthoracic echocardiographic evaluation performed on a follow-up showed slightly improved left ventricle function with an ejection fraction of 30%. At one-year follow-up, the pa-

tient was clinically stable, in an overall state of general well-being, and with complete participation in routine home activities; she had good exercise tolerance and no signs of ischemia.

DISCUSSION

Despite the advances in cardiac surgery, the outcome of combined mitral valve replacement and coronary artery bypass-grafting procedure

(MVR+CABG) remains unchanged during recent years according to the data presented by the Society of Thoracic Surgeons. The mortality is almost 10% (4). Without improvement, MVR+CABG also has the highest incidence of major morbidity among elective cardiac surgical procedures performed in the USA (4). The correction of ischemic mitral regurgitation is associated with an even more substantial risk of death, and an operative mortality of up to 17% has been recently reported (5). The trend for lower mortality in octogenarians was found in recent studies, however, it might be associated not only with medical and technological innovations but with patient selection as well (6). Non-elective cardiac surgery in the elderly is still related to high in-hospital mortality (7). The ischemic origin of mitral regurgitation of our patient, her advanced age, renal insufficiency, and critically decreased left ventricle ejection fraction dramatically lowered the chance to survive this high-risk corrective surgery. For selected octogenarians, the MitraClip device (Abbott Vascular, Inc., Santa Clara, CA), a tool for percutaneous transcatheter repair of mitral regurgitation, might be a good therapeutic option (8). However, this device is not available for use in our country. On the other hand, the use of extracorporeal life support in adult patients has grown exponentially during recent years (9). Although the main indication for the use of veno-arterial ECMO is cardiogenic shock refractory to medical treatment, it is becoming more utilised for complex high-risk elective coronary interventions (10, 11). The use of this technology could potentially help to improve outcomes providing haemodynamic stability and allowing complete revascularisation and optimal lesion treatment in these very sick patients.

For many years, intra-aortic balloon counterpulsation (IABP) was the preferred mechanical support device for high-risk coronary interventions. However, some multicentre randomised trials showed that elective IABP during high-risk percutaneous coronary interventions failed to reduce major adverse cardiac and cardiovascular events (12). Recent meta-analysis of the use of percutaneous mechanical assist devices found that IABP compared with other devices such as Impella or ECMO was less effective in decreasing the repeat revascularization rates (13).

Use of mechanical assist devices is associated with some additional risk for the patients. Poten-

tially devastating vascular complications occur in association with the use of percutaneous mechanical circulatory support (MCS). The rate of acute limb ischemia was reported to be up to 20% in some recent studies (14, 15). Development of limb ischemia is associated with decreased survival rates [16]. Some patients need surgical revision for bleeding following percutaneous decannulation due to persistent bleeding. However, compared to the surgical approach, percutaneous cannulation for MCS was associated with fewer local infections, similar rates of ischemia, and improved 30-day survival (17). Use of smaller cannulas if possible, appropriate access site selection, monitoring for the signs of limb ischemia, and use of vascular closure devices might reduce the rate of potential vascular complications in the future (18).

This case confirms that ECMO-assisted complex PCI in a high-risk patient can be safely performed, leading to a good outcome even in fragile patients of advanced age. Less invasive options for palliative procedures might be suitable for improving the functional status of high-risk elderly patients compared with more surgically aggressive approaches, which, despite their advantages, carry much higher procedural risks.

CONFLICTS OF INTEREST

The authors declare that there is no conflict of interest regarding the publication of this article.

CONSENT

A written informed consent form was obtained from the patient.

AUTHORS' CONTRIBUTIONS

All authors had full access to data and a role in the preparation of this manuscript.

Received 9 August 2019
Accepted 4 September 2019

References

1. Neumann F, Sousa-Uva M, Ahlsson A, Alfonso F, Banning A, Benedetto U, et al. 2018 ESC/EACTS

- guidelines on myocardial revascularization. *Eur Heart J*. 2019; 40: 87–165. doi: 10.1093/eurheartj/ehy394.
2. Karagiannidis C, Brodie D, Strassman S, Stoelben E, Philipp A, Bein T, et al. Extracorporeal membrane oxygenation: evolving epidemiology and mortality. *Intensive Care Med*. 2016; 42: 889–896. doi: 10.1007/s00134-016-4273-z.
 3. Mourad M, Gaudar P, De La Arena P, Eliet J, Zerrour N, Rouviere P, et al. Circulatory support with extracorporeal membrane oxygenation and/or impella for cardiogenic shock during myocardial infarction. *ASAIO J*. 2018; 64(6): 708–14. doi: 10.1097/MAT.0000000000000704.
 4. D'Agostino R, Jacobs J, Badhwar B, Fernandez FG, Paone G, Wormuth DW, et al. The Society of Thoracic Surgeons Adult Cardiac Surgery database: 2018 update on outcomes and quality. *Ann Thorac Surg*. 2018; 105: 15–23. doi: 10.1016/j.athoracsur.2017.10.035.
 5. Acker M, Parides M, Perrault L, Moskowitz AJ, Gelijns AC, Voisine P, et al. Mitral valve repair versus replacement for severe ischemic mitral regurgitation. *N Engl J Med*. 2014; 370: 23–32. doi: 10.1056/NEJMoa1312808.
 6. Scandroglio A, Finco G, Pieri M, Ascari R, Calabro M, Taddeo D, et al. Cardiac surgery in 260 octogenarians: a case series. *BMC Anesthesiol*. 2015; 15:15. doi: 10.1186/1471-2253-15-15.
 7. Deschka H, Muller D, DellAquila A, Mathaus M, Erler S, Wimmer-Greinecker G, et al. Non-elective cardiac surgery in octogenarians: do these patients benefit in terms of clinical outcomes and quality of life? *Geriatr Gerontol Int*. 2016; 16(4): 416–23. doi: 10.1111/ggi.12484.
 8. Geis N, Raake P, Mereles D, Chorianopoulos E, Szabo G, Katus HA, et al. Percutaneous repair of severe mitral valve regurgitation secondary to chordae rupture in octogenarians using MitraClip. *J Interv Cardiol*. 2018; 31(1): 76–82. doi: 10.1111/joic.12455.
 9. Makdisi G, Weng I. Extra corporeal membrane oxygenation (ECMO) review of a lifesaving technology. *J Thorac Dis*. 2015; 7: 166–76. doi: 10.3978/j.issn.2072-1439.2015.07.17
 10. Tomasello S, Boukhris M, Ganyukov V, Galassi AR, Shukevich D, Haes B, et al. Outcome of extracorporeal membrane oxygenation support for complex high-risk elective percutaneous coronary interventions: a single centre experience. *Heart Lung*. 2015; 44: 309–13. doi: 10.1016/j.hrtlng.2015.03.005.
 11. Kass M, Moon M, Vo M, Singal R, Ravandi A. Awake extracorporeal membrane oxygenation for very high-risk coronary angioplasty. *Can J Cardiol*. 2015; 31(2): 227.e11-3. doi: 10.1016/j.cjca.2014.11.004.
 12. Perera D, Stables R, Thomas M, Booth J, Pitt M, Blackman D, et al. Elective intra-aortic balloon counterpulsation during high-risk percutaneous coronary interventions: a randomized controlled trial. *JAMA*. 2010; 304(8): 867–74. doi: 10.1001/jama.2010.1190
 13. Shi W, Wang W, Wang K, Huang K. Percutaneous mechanical circulatory support devices in high-risk patients undergoing coronary interventions: A meta-analysis of randomized trials. *Medicine (Baltimore)*. 2019; 98(37): e17107. doi: 10.1097/MD.00000000000017107.
 14. Mohite P, Fatulayev J, Mounz O, Kaul S, Sabashnikov A, Weymann A, et al. Distal limb perfusion: Achilles heel in peripheral venoarterial extracorporeal membrane oxygenation. *Artific. Organs*. 2014; 38(11): 940–4. doi: 10.1111/aor.12314.
 15. Cheng R, Hachamovitch R, Kittleson M, Patel J, Arabia F, Moriguchi J, et al. Complications of extracorporeal membrane oxygenation for treatment of cardiogenic shock and cardiac arrest: a meta-analysis of 1866 adult patients. *Ann Thorac Surg*. 2014; 97: 610–6. doi: 10.1016/j.athoracsur.2013.09.008.
 16. Abounza M, Kobbani L, Nypaver T, Greenbaum A, Balraj P, Qureshi S, et al. Incidence and prognosis of vascular complications after percutaneous placement of left ventricular assist device. *J Vasc Surg*. 2015; 62: 417–23. doi: 10.1016/j.jvs.2015.03.040.
 17. Danial P, Hajage D, Nguyen L, Mastroianni C, Demondion P, Schmidt M, et al. Percutaneous versus surgical femoro-femoral veno-arterial ECMO: a propensity score matched study. *Intensive Care Med*. 2018; 44(12): 2153–61. doi: 10.1007/s00134-018-5442-z.
 18. Montero Cabezas JM, van der Meer R, van der Kley F, Elzo Kramer CV, Lopez Matta JE, Schalijs MJ, et al. Percutaneous decannulation of femoral veno-arterial ECMO cannulas using MANTA vascular closing device. *Can J Card*. 2019; 35(6): 796.e9–11. doi: 10.1016/j.cjca.2019.02.010.

**Robertas Samalavičius, Lina Puodžiukaitė,
Vytautas Abraitis, Ieva Norkienė,
Nadežda Ščupakova, Justina Pekarskienė,
Aleksejus Zorinas, Kęstutis Ručinskas,
Pranas Šerpytis**

**SĖKMINGA PERKUTANINĖ KORONARINĖ
INTERVENCIJA DIDELĖS RIZIKOS
SENYVO AMŽIAUS PACIENTEI TAIKANT
EKSTRAKORPORINĘ MEMBRANINĘ
OKSIGENACIJĄ**

Santrauka

Vyresnio amžiaus didelės rizikos pacientų grupėje miokardo revaskuliarizacija išlieka klinikiniu iššūkiu. Pristatomas klinikinis atvejis, kai kompleksinė perkutaninė koronarinė intervencija buvo įmanoma tik naudojant ekstrakorporinę membraninę oksigenaciją (EKMO). 83 metų pacientė hospitalizuota į tretinio lygio ligoninę dėl progresuojančio širdies nepakankamumo. Atlikus širdies ultragarso tyrimą nustatyta itin sumažėjusi kairiojo skilvelio išstūmimo frakcija (20 %) ir didelis mitralinio vožtuvo nesandarumas, vidutiniai aortos ir triburio vožtuvų nepakankamumai. Atlikus koronarografiją nustatyta trijų vainikinių arterijų liga. Dėl labai didelės operacinio gydymo rizikos buvo nuspręsta atlikti perkutaninę koronarinę intervenciją taikant EKMO. Pasitelkus pagalbinę mechaninę kraujotaką buvo atliktas trijų vainikinių arterijų stentavimas. Po procedūros pacientė buvo pervežta į intensyviosios terapijos skyrių taikant EKMO, po devynių valandų pagalbinę kraujotaką buvo sėkmingai atjungta. Intensyviosios terapijos skyriuje pacientė buvo gydoma keturias paras. Praėjus vieneriems metams ji jautėsi gerai, toleravo vidutinio sunkumo fizinį krūvį ir kasdienės veiklos apribojimų nejuto.

Šis klinikinis atvejis parodo veiksmingą EKMO taikymą atliekant sudėtingas perkutanines koronarines intervencijas.

Raktažodžiai: EKMO, perkutaninė koronarinė intervencija, koronarinė širdies liga, vyresnio amžiaus pacientas