

# Successful Thrombolysis for Acute Ischemic Stroke in the Presence of Hyposphagma: A Clinical Case Report

G. Ulianskaitė\*  
A. Timinskaitė\*  
J. Valaikienė\*\*

\*Vilnius University,  
Faculty of Medicine

\*\*Vilnius University,  
Centre of Neurology

**Summary.** *Background.* In cases with standard indications and contraindications for the treatment of acute stroke, urgent thrombolysis with intravenous tissue plasminogen activator provides undoubted benefit. However, atypical situations not described in standard treatment guidelines may occur in daily clinical practice. Hence, a clinical case of a patient with an acute ischemic stroke and concomitant ocular bleeding is presented. The medical team needed to urgently evaluate the additional risk of ocular bleeding and make the most appropriate decision on using thrombolytic stroke therapy.

*Case presentation.* A 70-year-old female with acute right-sided weakness was admitted to the emergency department within 2.5 hours. Cerebral computed tomography revealed hyperacute ischemia in the left frontal-parietal area. The neurologist diagnosed an acute ischemic stroke in the left middle cerebral artery with mild right-sided hemiparesis, and the ophthalmologist diagnosed subconjunctival haemorrhage (i.e. hyposphagma). In the absence of absolute contraindications, intravenous thrombolysis with tissue plasminogen activator was performed. The neurological symptoms regressed within one day and the hyposphagma was significantly reabsorbed within three days. The patient was discharged without residual deficits.

*Conclusions.* The presented clinical case contributes to the positive evidence that systemic thrombolysis is a safe and effective method for the treatment of an acute ischemic stroke in the presence of hyposphagma.

**Keywords:** acute ischemic stroke, subconjunctival haemorrhage, hyposphagma, thrombolysis, tissue plasminogen activator, case report.

## BACKGROUND

In the case of acute ischemic stroke (AIS), systemic thrombolysis with intravenous (IV) tissue plasminogen activator (tPA) within the first 4.5 hours is a first-choice treatment when there are no contraindications [1]. The most common known side effect of IV tPA is bleeding. According to the Actilyse Summary of Product Characteristics by Boehringer Ingelheim Limited (Online resource 1), intracerebral haemorrhage and bleeding from damaged

blood vessels have been reported to be a very common adverse reaction of IV tPA (1/10), whereas ocular haemorrhage is rare (1/10,000 to 1/1,000). An intraocular (i.e. retinal/choroidal/vitreous) haemorrhage following the administration of IV tPA for the treatment of stroke may impair visual function [2] or cause blindness [3]. Recommendations for AIS treatment in the case of acute ocular bleeding are not clearly stated in the guidelines. Therefore, a dilemma arises when examining a patient with acute cerebral ischemia and signs of bleeding in the eye. The authors describe a solution to this complex clinical situation that led to the patient's recovery.

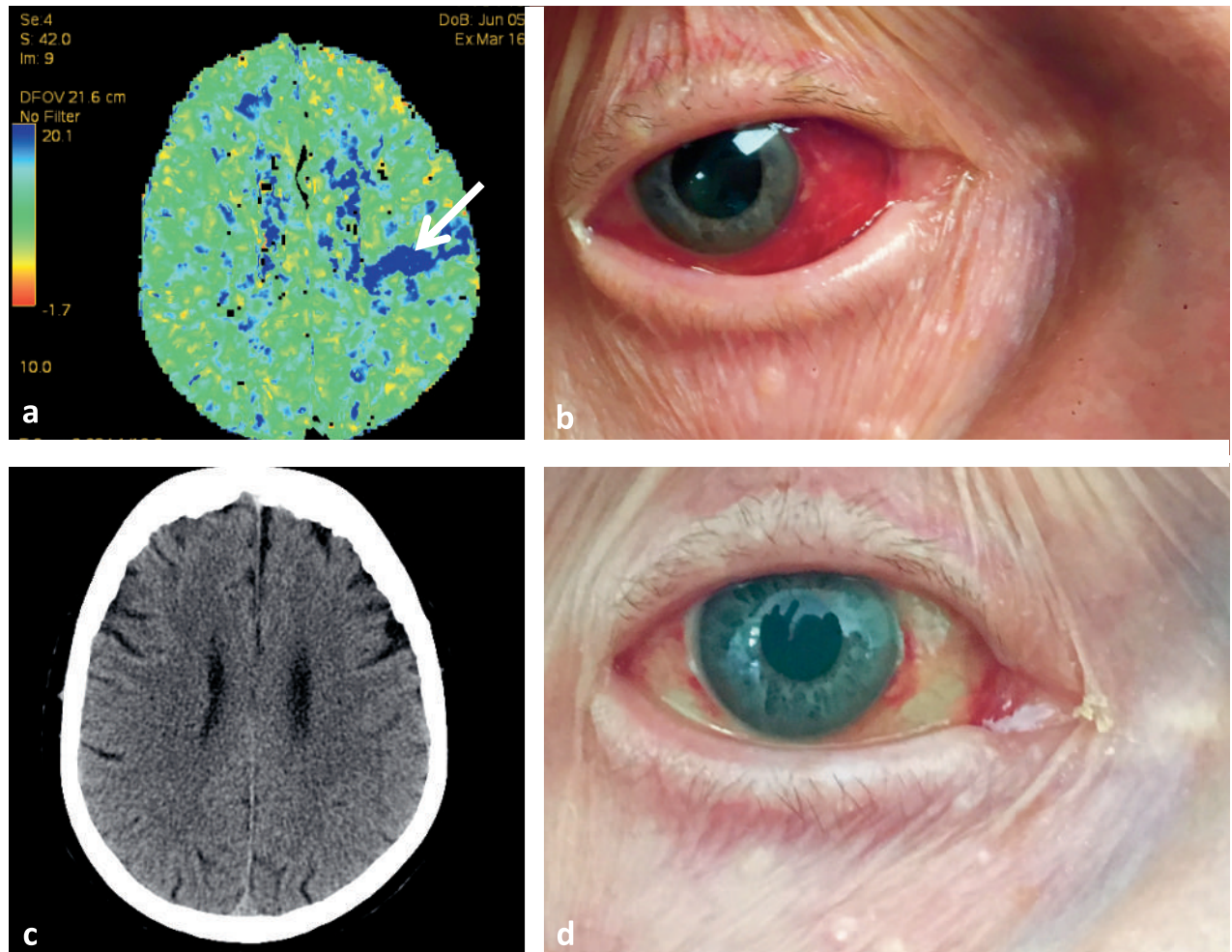
### Address:

Gintarė Ulianskaitė  
Vilnius University, Faculty of Medicine  
M. K. Čiurlionio st. 21, LT-03101 Vilnius  
E-mail: g.ulianskaite@gmail.com

## CASE PRESENTATION

A 70-year-old female was admitted to the emergency department 2.5 hours after the onset of right-sided weak-

© Neurologijos seminarai, 2020. Open Access. This article is distributed under the terms of the Creative Commons Attribution 4.0 International License CC-BY 4.0 (<http://creativecommons.org/licenses/by/4.0/>), which permits unrestricted use, distribution, and reproduction in any medium, provided you give appropriate credit to the original author(s) and the source, provide a link to the Creative Commons license, and indicate if changes were made.



**Fig. (a)** Computed tomography perfusion imaging on the day of admission showing hyper-acute ischemia in the left frontal-parietal area (arrow) without a formed core. **(b)** The right eye hyposphagma before receiving intravenous tissue plasminogen activator. **(c)** Computed tomography taken 24 hours after receiving intravenous tissue plasminogen activator shows no pathological changes. **(d)** Significant absorption of the right eye hyposphagma three days after receiving intravenous tissue plasminogen activator.

ness. Her past medical history included hypertension, dyslipidemia, and painless ocular bleeding one year ago, the last complaint reoccurring one day before the AIS. Anticoagulants were not used. On clinical examination, the patient was conscious and responsive. Neurological examination revealed mild right-sided hemiparesis (grade 4 according to the Medical Research Council Scale (MRCS)), hemihypesthesia, and a flattened (right) nasolabial fold. The National Institutes of Health Stroke Scale score (NIHSS) was 4 upon arrival at the emergency department, blood pressure 148/74 mmHg. No significant changes were observed. Urgent cerebral computed tomography (CT) revealed no acute focal lesions. CT perfusion showed hyperacute ischemia in the left frontal-parietal area without a formed core (Fig., a), CT angiography showed no occlusion of the major cerebral arteries. The Alberta Stroke Program Early CT score (ASPECTS) was 10. After the evaluation of the stroke's onset time and severity, the laboratory tests, and the brain CT, no contraindications for thrombolysis were found. Since a haemorrhage in the right eye was observed during

the physical examination (Fig., b), the ophthalmologist on duty was urgently called. He excluded intraocular bleeding and diagnosed extraocular subconjunctival haemorrhage (i.e., hyposphagma) with no risk of visual impairment. Before the thrombolysis with IV tPA was initiated, 3.5 hours after the onset of the symptoms, the patient's condition suddenly deteriorated to 6 scores on the NIHSS in conjunction with a partial motor aphasia and increased right-sided weakness (MRCS grade 3). Alteplase was immediately injected IV 0.9 mg/kg body weight: 7 mg bolus followed by 66 mg/hour. Following the treatment, no change in the size or extent of the hyposphagma was observed. A repeat head CT after 24 hours showed no pathological changes (Fig., c). The neurological symptoms regressed totally within one day; the hyposphagma was alleviated rapidly. Three days later, significant reabsorption of the hyposphagma was observed (Fig., d). The patient was discharged on antihypertensive therapy, statins, and antiplatelet agents daily. No more cerebrovascular events occurred during two years of follow-up.

## DISCUSSION AND CONCLUSIONS

We described an uncommon clinical situation where a patient with AIS presented with an acute hyposphagma. Evaluation of the patient's clinical status, stroke's onset, laboratory tests, and CT images yielded no contraindications for thrombolysis. Nevertheless, the acute ocular bleeding raised doubts. In view of the latest AIS guidelines, it is reasonable to recommend IV tPA treatment (Class IIa; Level of Evidence B-Nonrandomised) for patients with a history of diabetic haemorrhagic retinopathy or other haemorrhagic ophthalmic conditions. The potential increased risk of visual loss should be weighed against the anticipated benefits of a reduced stroke-related neurological deficit [1]. However, no specific recommendations for IV tPA treatment in the case of acute hyposphagma and stroke are presented in the current AIS guidelines. Therefore, the team of clinicians had to make a rapid decision whether or not to use thrombolytic treatment. In order to make an extra decision, the ophthalmologist on duty was called. He diagnosed subconjunctival bleeding without visual impairment. While re-evaluating the patient, a sudden worsening of the mild right-sided hemiparesis and partial motor aphasia occurred, so IV tPA treatment was begun immediately. The desired outcomes were observed: the neurological symptoms regressed and the condition of the eye remained stable. Moreover, the hyposphagma was significantly absorbed within 3 days. To our knowledge, only one clinical case with a decision to apply IV thrombolysis for AIS in the presence of acute hyposphagma has been published [4]. Afterwards, the patient developed left-sided proptosis and a worsening of the hyposphagma without visual impairment. According to the authors of that report, a diagnosis of acute hyposphagma should not deprive the patient of accessing thrombolytic treatment. The results of our case are in line with the opinion of these authors. In addition, it has previously been reported that subconjunctival injections of tPA may be useful in the treatment of severe hyposphagmus [5].

According to the data of a population-based three-year follow-up study, patients with hyposphagma had a statistically higher risk of stroke compared to the control group and the major cause of hyposphagma among the elderly was arterial hypertension [6]. According to the follow-up data of the presented case, no more cerebrovascular events occurred during the next two years with regular treatment with antihypertensive therapy, statins, and antiplatelet agents.

In summary, the presented case adds positive evidence that IV thrombolysis in the presence of AIS and concomitant hyposphagma is a safe and effective method of treatment. However, urgent consultation by an ophthalmologist before the thrombolysis is meaningful in assessing eye damage and visual disturbance, informing the patient and/or the relatives about the risk and expected prognosis, and involving them in the decision-making process.

## References

1. Powers WJ, Rabinstein AA, Ackerson T, Adeoye OM, Bambakidis NC, Becker K, et al. 2018 guidelines for the early management of patients with acute ischemic stroke: a guideline for healthcare professionals from the American Heart Association/American Stroke Association. *Stroke* 2018; 49(3): e46–99. <https://doi.org/10.1161/STR.000000000000163>
2. Lee S, Gjerde H, Gubitz G. Retinal and choroidal haemorrhage after tissue plasminogen activator administration. *Can J Neurol Sci* 2017; 44(4): 461–2. <https://doi.org/10.1017/cjn.2017.35>
3. Hormese M, Wichter M. Vitreo-retinal hemorrhage after thrombolysis in a patient with acute ischemic stroke: a case report. *Front Neurol* 2012; 3: 71. <https://doi.org/10.3389/fneur.2012.00071>
4. Newey CR, Cueva W, Vellipuram A, Hornik A. Medical decision making: hyposphagma prior to intravenous tissue plasminogen activator in acute ischemic stroke. *J Stroke Cerebrovasc Dis* 2016; 25(10): e181–2. <https://doi.org/10.1016/j.jstrokecerebrovasdis.2016.07.018>
5. Mimura T, Yamagami S, Funatsu H, et al. Management of subconjunctival haematoma by tissue plasminogen activator. *Clin Experiment Ophthalmol* 2015; 33(5): 541–2. <https://doi.org/10.1111/j.1442-9071.2005.01080.x>
6. Wang TJ, Keller JJ, Sheu JJ, Lin HC. A 3-year follow-up study on the risk of stroke among patients with conjunctival haemorrhage. *Acta Ophthalmol* 2013; 91(3): 226–30. <https://doi.org/10.1111/j.1755-3768.2011.02359.x>

G. Ulianskaitė, A. Timinskaitė, J. Valaikienė

## SĖKMINGAS TROMBOLIZĖS PRITAIKYMAS LIGONIUI SU ŪMIU IŠEMINIŲ INSULTU IR ŪMIA SUBKONJUNKTYVINE HEMORAGIJA: ATVEJO PRISTATYMAS

### Santrauka

*Ivadas.* Insulto atveju skubi trombolizė intraveniniu audinių plazminogeno aktyvatoriumi, taikoma pagal standartines indikacijas, teikia neabejotiną naudą. Klinikinėje praktikoje tenka susidurti su situacijomis, neaprašytomis standartinėse gydymo schemose. Aprašomas klinikinis atvejis, kai ligonei įvyko ūmus išeminis insultas, o prieš dieną – neskausmingas pakraujavimas į akį. Gydytojų komanda turėjo skubiai įvertinti susidariusią situaciją, galimą trombolizės riziką ir priimti tinkamiausią ligonei sprendimą.

*Atvejo aprašymas.* 70 metų moteris atvežta į ligoninę dėl staiga prieš 2,5 valandos nusilpusių dešiniųjų galūnių. Atlikus galvos smegenų kompiuterinę tomografiją, nustatyta superūmos išemijos zona kairiojoje frontoparietalinėje srityje. Neurologas diagnozavo ūmų išeminį insultą kairiosios vidurinės smegenų arterijos baseine su lengvo laipsnio dešiniąja hemipareze, oftalmologas – subkonjunktivinę hemoragiją (*hyposphagma*). Nesant absoliučių kontraindikacijų, atlikta sisteminė intraveninė trombolizė audinių plazminogeno aktyvatoriumi. Neurologinė simptomatika regresavo per parą, o po trijų dienų stebėta žymi hiposfagmos rezorbcija. Ligonė pasveiko, iš ligoninės išrašyta be liekamųjų neurologinių reiškinių.

*Išvados.* Pateiktas klinikinis atvejis prisideda prie įrodymų, kad sisteminė trombolizė yra saugus ir efektyvus gydymo būdas, ištikus ūmiam išeminiam insultui kartu su ūmia subkonjunktivine hemoragija.

**Raktažodžiai:** audinių plazminogeno aktyvatorius, hiposfagma, subkonjunktivinė hemoragija, trombolizė, ūmus išeminis insultas.

Gauta:  
2020 05 01

Priimta spaudai:  
2020 05 14