

The impact of hepatitis C virus infection on early post-liver transplantation complications and early graft function in a single low-volume liver transplant center

Arida Buivydienė^{1,2,3},

Viktorija Basytė³,

Laura Mašalaitė^{1,2,3},

Danguolė Stanislovaitytė²,

Jurgita Adomavičiūtė⁴,

Jonas Valantinas^{1,2,3}

¹ Centre of Hepatology,
Gastroenterology and Dietetics,
Vilnius University Hospital
Santariškių Clinics,
Vilnius, Lithuania

² Clinic of Gastroenterology,
Nephrourology and Surgery,
Medical Faculty, Vilnius University,
Vilnius, Lithuania

³ Vilnius University,
Medical Faculty, Vilnius, Lithuania

⁴ Centre of Vascular Reconstruction
and Endovascular Surgery,
Vilnius University
Hospital Santariškių Clinics,
Vilnius, Lithuania

Background. End-stage liver disease associated with hepatitis C virus (HCV) infection has become one of the leading indications for liver transplantation. The effect of HCV infection on patients and long-term graft survival after orthotopic liver transplantation is well known. The aim of this study was to evaluate the impact of HCV infection on early post-liver transplantation complications and early graft function.

Materials and methods. Between July 2005 and February 2015 60 cadaveric orthotopic liver transplantations were performed in 58 adult patients at the Vilnius University Hospital Santariškių Clinics. We retrospectively reviewed our low-volume liver transplant center experience. To evaluate the changes that occurred in HCV-positive and HCV-negative transplant recipients, the study population was divided into two groups according to their HCV status. Statistical analysis was performed using the Microsoft Excel and SPSS 20.0 program. Group differences and data reliability were determined by the Student's t-test.

Results. For 21 patients (35%) the indication for liver transplantation was end-stage liver disease due to HCV infection and for 39 patients (65%) there was another (non-HCV infection) indication. Overall, 29 patients (48%) have developed early biliary and/or vascular complications after transplantation: vascular complications were observed in 17 patients (28%) and biliary complications were observed in 12 patients (20%). Early graft function was good or fair in 52 patients (87%), primary dysfunction was observed in 8 (13%) patients.

Conclusions. The incidence of early post-transplant complications and early graft dysfunction had no statistically significant difference according to the patient's HCV status.

Key words: hepatitis C, liver transplantation, early post-transplant complications, early graft function

INTRODUCTION

It has been demonstrated that low-volume orthotopic liver transplant (OLT) centers have poorer outcomes compared to high-volume centers some years ago. But more recent analyses have failed to demonstrate any significant association between adult liver transplant center volume and recipient outcomes (1–2).

In 2005, the first successful OLT was performed in the Vilnius University Hospital Santariškių Clinics. Our hospital is a low-volume liver transplant center with a mean annual number of overall liver transplants less than 20 (average is 6 per year; Fig. 1). But till now orthotopic liver transplantation (OLT) in Lithuania has been successfully performed for patients with a variety of irreversible chronic liver diseases and liver cancer in two low-volume centers. Overall, the patient post-OLT survival rate after one year in our transplant center is 85% and we have the same results after three and four years – that is comparable with survival rates in experienced transplant centers (3–4).

However, early post-operative period after liver transplantation still represents a critical time with persistently high rate of surgical complications: post-operative hemorrhage, vascular and biliary complications and allograft dysfunction (5–6). In the Vilnius University Hospital Santariškių Clinics about one third (35%) of liver transplantations are performed in patients with (HCV) infection and this number is expected to significantly rise during the next decade, especially with burgeoning rates of hepatocel-

lular carcinoma (HCC). In our center diagnosis of HCV-positive HCC was made up to 20% ($n = 12$). By the year 2020 the proportion of untreated HCV patients developing cirrhosis is expected to increase by 30%, the number of cirrhotic patients with HCV by 100%, and the number of HCV cirrhotic patients developing hepatocellular carcinoma by 80% (7). Hepatitis C virus (HCV) infection is a well-known factor, affecting the patient and graft long-term survival after liver transplantation. Recurrence of HCV after OLT is almost universal – serum HCV titers may reach pre-transplant levels within the first few days post-operatively (8). Allograft failure secondary to recurrence of HCV infection in late term is the most common cause of death and retransplantation (9–10). HCV is a known risk factor, associated with increased mortality beyond 1-year post-liver transplant (11). But the relationship between HCV infection and early vascular, biliary complications and early allograft dysfunction is not clear (12–15).

The aim of this study was to evaluate the impact of HCV on early post-liver transplantation complications and early graft function.

MATERIALS AND METHODS

We performed a retrospective cohort study using data from all adult patients aged 18 or older who underwent OLT between July 2005 and February 2015. Patients were divided into two groups according to the following pattern of hepatitis C virus (HCV) infection: HCV-positive transplant recipients' group ($n = 21$, 35%) and HCV-negative transplant recip-

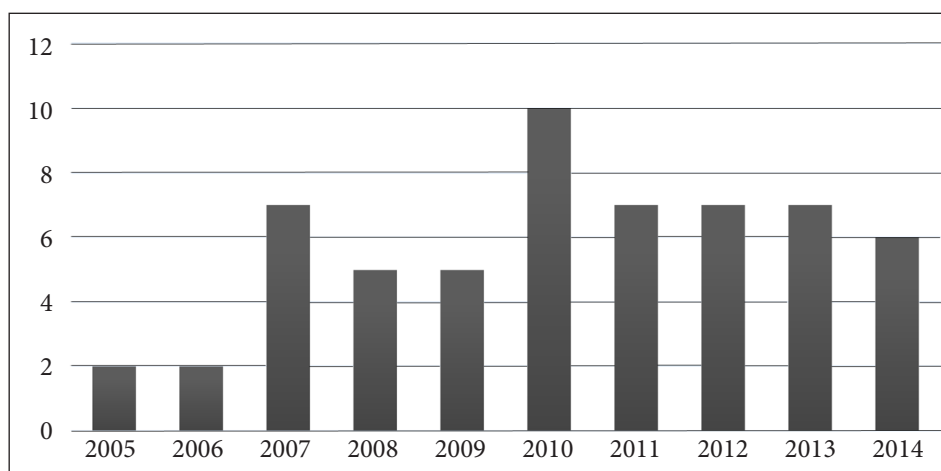


Fig. 1. Orthotopic liver transplantation in the Vilnius University Hospital Santariškių Clinics

ients' group (n = 39, 65%). Statistical analysis was performed using the Microsoft Excel and SPSS 20.0 program. Group differences and data reliability were determined by the Student's t-test.

RESULTS

In the ten-year period (2005–2015) 60 OLT in 58 adults (2 of them were liver retransplantation) were performed. 63.33% were males (n = 38) and 36.67% (n = 22) were females; the average age was 46.7 ± 9.2 years.

The indications for liver transplantation in our center are the same as in other liver transplant centers. The main indication is liver cirrhosis of different etiology (95%). In our center indications for OLT are as follows: 53% viral hepatitis (HCV/HBV)-related end-stage liver disease, 20% alcohol-related liver cirrhosis, 17% cholestatic liver disease and 10% other reasons. For all patients with HCC OLT was performed according to the Milano criteria. The original MELD score at the time of OLT was as follows: MELD ≤ 10 for 3 (indications were Caroli disease, primary biliary cirrhosis, giant hemangioma) patients (5%), MELD 11–18 for 29 patients (48%) and MELD > 19 for 28 patients (47%). The average MELD score in all patients at the time of transplantation was 20.23 (range: 7–45). The study population regarding the viral hepatitis status is shown in Table 1.

Table 1. The study population regarding viral C hepatitis (HCV) status

Indication	Patients	
	n	%
1. HCV-positive transplant recipients	21	35%
HCC associated with HCV infection	9	15%
2. HCV-negative transplant recipients	39	65%
Total	60	100%

All OLT were performed with the Belghiti technique without veno-venous bypass following completion of all vascular anastomosis with side-to-side cavo-caval, end-to-end porto-portal. The donor and recipient arteries in the majority of patients (n = 54, 90%) were connected by an end-to-end anastomosis if no anatomical variations or complications were presented. Alternatively, for 6 patients (10%) an interposition graft was placed in between the hepatic artery and aorta: 3 autoveins, 1 prosthesis and

2 donor's arterial conduits. Biliary anastomosis was performed as end-to-end choledocho-choledochostomy for the majority of patients (n = 55, 92%) with insertion of a T-drain in 37 patients (62%). Hepaticojejunostomy was performed in 5 patients (8%) (1 with primary sclerosing cholangitis, 1 with Caroli disease, 1 with cryptogenic fulminant hepatic failure, 1 with primary biliary cirrhosis and 1 liver retransplantation).

EARLY POST-TRANSPLANT COMPLICATIONS

Vascular complications were observed in 17 patients (28%). The majority of vascular complications involved hepatic artery (n = 12, 71%). Arterial vascular complications consisted of hepatic artery or arterio-arterial shunt thrombosis (n = 9, 53%), hepatic artery stenosis (n = 5, 29%), insufficiency of hepatic artery anastomosis (n = 2, 12%) and one pseudo aneurysm of hepatic artery with late hepatic artery thrombosis (n = 1, 6%) (Fig. 2). One patient (6%) had hemodynamically significant stenosis of portal vein anastomosis.

Biliary complications were observed in 12 patients (20% of the entire cohort). The majority of these biliary complications (n = 10, 83.33%) were bile leaks due to insufficiency of choledocho-choledochostomy or hepaticojejunostomy and late biliary

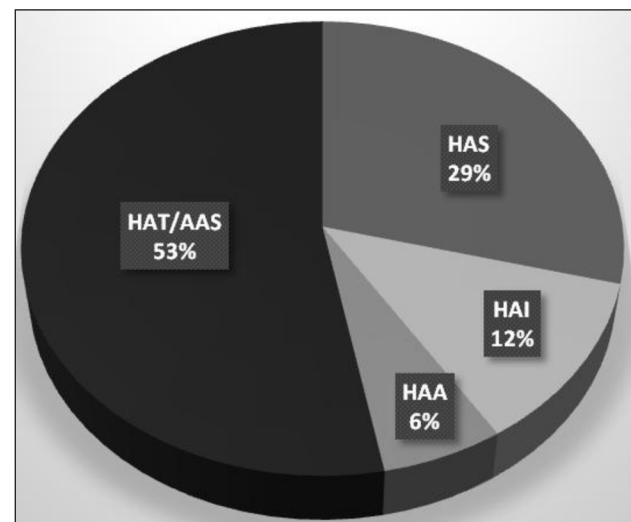


Fig. 2. Arterial vascular complications after OLT. HAT/AAS is hepatic artery or arterio-arterial shunt thrombosis; HAS is hepatic artery stenosis; HAI is hepatic artery anastomosis insufficiency; HAA is hepatic artery aneurysm

anastomosis strictures without previous biliary leakage ($n = 3.25\%$). Biliary complications were diagnosed in 19.05% ($n = 4$) of the HCV-positive patients' group ($p = 0.89$) and in 20.51% ($n = 8$) of the HCV-negative patients' group ($p = 0.89$).

7 of 10 patients (70%) with biliary leakage had hepatic artery vascular complication: 5 revealed hepatic artery thrombosis, 2 had hepatic artery stenosis.

From 10 patients with biliary leakage 3 patients died in the early postoperative period, 1 was retransplanted within 11 months after the first OLT. 4 patients (67%) from 6 patients, who had post-transplantation biliary complications and survived, revealed benign bile duct strictures. For all these strictures endoscopic treatment was necessary.

We observed that the rate of biliary complication was higher but in our small group not statistically significant ($p > 0.05$) when biliary anastomosis was performed as end-to-end choledocho-choledochostomy without insertion of a T-tube. When performing biliary anastomosis a T tube was placed for 37 patients and 8% ($n = 3$) of these patients had biliary complications. If the T-tube was not placed ($n = 23$), 39% ($n = 9$) developed biliary complications.

Since early graft dysfunction dramatically influences graft and patient outcomes after liver transplantation, early diagnosis is mandatory. In our center we diagnosed 8 cases of liver allograft early poor function/nonfunction and there were only two successful liver retransplantations performed, other two patients survived with adequate medical support, but four of them died.

There was no statistically significant differences between the HCV-positive transplant recipients' group ($n = 21$) and the HCV-negative transplant recipients' group ($n = 39$) according to recipient's age, gender, vascular complication rate, biliary complication rate, early graft dysfunction and long-term clinical outcome (Table 2).

DISCUSSION

Complications of the biliary tract remains "Achilles heel of liver transplantation" – it is a common source of morbidity and mortality. Biliary leaks in the early post-transplant period and strictures later on are the most common biliary complications and have been reported in 10–30% of post-transplant patients. The rate of biliary complications is varying widely, depending on the type of biliary reconstruction, bile duct ischemic damage, ABO incompatibility and infection (16). According to some authors, HCV infection may lead to inflammatory processes causing biliary damage (17). Biliary flow re-establishment is the last step of OLT after all vascular reconstructions. It can be performed by hepaticojejunostomy, choledo-cocholedochostomy with a T-tube or without a T-tube. This last technique is used in native bile duct disease free with a suitable caliber and presents less overall biliary complications than the other procedures in high-volume transplant centers (18). In our low-volume transplant center we observed that the rate of biliary complication was higher when biliary anastomosis was performed as end-to-end choledocho-choledochostomy without insertion of a T-tube, but in our small group it is not statistically significant ($p > 0.05$).

There are several anastomotic possibilities involving the hepatic artery. In OLT, the donor celiac axis is anastomosed to the recipient hepatic artery at either the bifurcation into the left and right hepatic arteries or the takeoff of the gastroduodenal artery. In patients with a small or diseased hepatic artery, a donor iliac artery or recipient vena saphena autove-na interposition graft may be anastomosed directly to the recipient aorta. Hepatic artery complications include thrombosis, stenosis, and pseudoaneurysm. Hepatic artery thrombosis and stenosis occurring in 2–12% of cases can lead to biliary ischemia, since the

Table 2. Clinical characteristics between the HCV-positive and HCV-negative recipients' groups

Characteristic	HCV-positive group $n = 21$	HCV-negative group $n = 39$	p value
Recipient age, years (mean \pm SD)	49.1 \pm 7.15	45.5 \pm 10	0.15
Complications (vascular and biliary)	$n = 10$ (48%)	$n = 19$ (49%)	0.69
Vascular complications	$n = 6$ (29%)	$n = 11$ (28%)	0.97
Biliary complications	$n = 4$ (19%)	$n = 8$ (21%)	0.89
Early graft good/fair function AST <2500 U/L	$n = 17$ (81%)	$n = 35$ (90%)	0.35
Primary graft dysfunction AST \geq 2500 U/L	$n = 4$ (19%)	$n = 4$ (10%)	0.39
Long-term clinical outcome, Died	$n = 3$ (5%)	$n = 7$ (11.67%)	0.72

hepatic artery is the only source of vascular supply to the bile ducts. Biliary ischemia may in turn lead to a nonanastomotic biliary stricture or a biloma, which are often associated with hepatic artery complications. The cause of HAT is still unknown, up to 20% of HAT are probably due to technical problems in the arterial anastomosis, poor quality donor and recipient vessels, arterial abnormalities requiring complex arterial reconstructions, or kinking. Those problems are more common among centers performing less than 30 OLT per year. Regarding nonsurgical risk factors involved in the appearance of HAT the literature reveals contradictory conclusions: elderly donor's age, extended cold ischemia time, lack of ABO compatibility, cigarette smoking, hypercoagulability, preservation damage, infection (20).

Liver graft dysfunction dramatically influences graft and patient outcomes after liver transplantation too. Early graft function depends on the donor, recipient and technical operative factors. Donor's age, steatosis of liver allograft, hypernatremia, long stay in an intensive care unit with high inotropic drug use are well-known factors affecting early graft function (19–20). We need appropriate organ matching based on donor-recipient characteristics. But we did not reveal any difference in early graft function depending on HCV status.

CONCLUSIONS

In our retrospective study the incidence of early post-transplant biliary, vascular complications and early liver graft function had no statistically significant difference according to the patient's HCV status. No differences were found in graft and patient survival between HCV-positive and HCV-negative recipients' groups. This study, however, has some limitations due to a relatively small sample size.

Received 17 March 2015

Accepted 7 May 2015

References

1. Paskonis M, Masalaite L, Buivydiene A, Sokolovas V, Jurgaitis J, Jurevicius S, et al. Orthotopic liver transplantation: the first experience and results of the Vilnius University Hospital Santariskiu Klinikos. *Ann Transplant*. 2010; 15(1): 14–24.
2. Paskonis M, Jurgaitis J, Sokolovas V, Rainiene T, Dainys B, Strupas K. Development of liver transplantation in the world and Lithuania. *Lithuanian Surgery*. 2007; 5(1): 77–88.
3. Strupas K. Monography: Liver transplantation; 2013. p. 114–25.
4. Adam R, Karam V, Delvart V, O'Grady J, Mirza D, Klempnauer J, et al. Evolution of indications and results of liver transplantation in Europe. A report from the European Liver Transplant Registry (ELTR). *J Hepatol*. 2012; 57(3): 675–88. doi:10.1016/j.jhep.2012.04.015.
5. Axelrod DA, Guidinger MK, McCullough KP, Leichtman AB, Punch JD, Merion RM. Association of center volume with outcome after liver and kidney transplantation. *Am J Transplant*. 2004; 4(6): 920–7. doi:10.1111/j.1600-6143.2004.00462.x.
6. Northup PG, Pruett TL, Stukenborg GJ, Berg CL. Survival after adult liver transplantation does not correlate with transplant center case volume in the MELD era. *Am J Transplant*. 2006; 6(10): 2455–62.
7. Scarborough JE, Pietrobon R, Tuttle-Newhall JE, Marroquin CE, Collins BH, Desai DM, et al. Relationship between provider volume and outcomes for orthotopic liver transplantation. *J Gastrointest Surg*. 2008; 12(9): 1527–33.
8. Charlton M. Liver biopsy, viral kinetics, and the impact of viremia on severity of hepatitis C virus recurrence. *Liver Transpl*. 2003; 9(11): S58–62. doi:10.1053/jlts.2003.50245.
9. Forman LM, Lewis JD, Berlin JA, Feldman HI, Lucey MR. The association between hepatitis C infection and survival after orthotopic liver transplantation. *Gastroenterology*. 2002; 122: 889–96.
10. Howell J, Angus P, Gow P. Hepatitis C recurrence: the Achilles heel of liver transplantation. *Transpl Infect Dis*. 2014; 16(1): 1–16. doi: 10.1111/tid.12173.
11. Wojcicki M, Milkiewicz P, Silva M. Biliary tract complications after liver transplantation: a review. *Dig Surg*. 2008; 25(4): 245–57. doi: 10.1159/000144653.
12. Fujita S, Fujikawa T, Mizuno S, Reed AI, Kim RD, Howard RJ, et al. Is early recurrence of hepatitis C associated with biliary anastomotic stricture after liver transplantation? *Transplantation*. 2007; 84(12): 1631–5. doi: 10.1097/01.tp.0000295983.55088.96.
13. Horster S, Bäuerlein FJB, Mandel P, Raziorrouh B, Hopf C, Stemmler HJ, et al. Influence of hepatitis C virus infection and high virus serum load on biliary complications in liver transplantation. *Transpl Infect Dis*. 2013; 15(3): 306–13. doi:10.1111/tid.12069.

14. Katz LH, Mor E, Brown M, Bar-Nathan N, Shahrabani E, Sulkes J, et al. Recurrent hepatitis C virus disease after liver transplantation and concurrent biliary tract complications: Poor outcome. *Clin Transplant*. 2006; 20(1): 465–670. doi:10.1111/j.1399-0012.2006.00507.x.
15. Verna EC, De Martin E, Burra P, Neri D, Gaglio PJ, Emond JC, et al. The impact of hepatitis C and biliary complications on patient and graft survival following liver transplantation. *Am J Transplant*. 2009; 9: 1398–405. doi:10.1111/j.1600-6143.2009.02649.x.
16. Davis GL, Albright JE, Cook SF, Rosenberg DM. Projecting future complications of chronic hepatitis C in the United States. *Liver Transplant*. 2003; 9(4): 331–8. doi:10.1053/jlts.2003.50073.
17. Briceño J, Ciria R. Early graft dysfunction after liver transplantation. *Transplant Proc*. 2010; 42(2): 631–3. doi:10.1016/j.transproceed.2010.02.004.
18. Varotti G, Grazi GL, Vetrone G, Ercolani G, Cescon M, Del Gaudio M, et al. Causes of early acute graft failure after liver transplantation: analysis of a 17-year single-centre experience. *Clin Transplant*. 2005; 19(4): 492–500.
19. Ousmane KA. Biliary complications after choledochocholedochostomy without T-tube in whole-size liver transplantation in adults. *J Liver*. 2012; 1: 3.
20. Bekker J, Ploem S, de Jong KP. Early hepatic artery thrombosis after liver transplantation: a systematic review of the incidence, outcome and risk factors. *Am J Transpl*. 2009; 9: 746.

Arida Buivydienė, Viktorija Basytė, Laura Mašalaitė, Danguolė Stanislovaitytė, Jurgita Adomavičiūtė, Jonas Valantinas

VIRUSINIO C HEPATITO INFEKCIJOS REIKŠMĖ ANKSTYVOMS KOMPLIKACIJOMS PO KEPENŲ TRANSPLANTACIJOS IR ANKSTYVAI KEPENŲ TRANSPLANTATO FUNKCIJAI MAŽAME TRANSPLANTACIJOS CENTRE

Santrauka

Įžanga. Hepatito C viruso (HCV) sukeltas lėtinis kepenų pažeidimas (išiečių stadija) pastaruoju metu transplantuojant kepenis yra viena dažniausių indikacijų. Kad pacientai išgyventų ir kepenų transplantatas ilgą laiką funkcionuotų, HCV infekcijos įtaka gerai žinoma, tačiau jos reikšmė ankstyvoms potransplantacinėms komplika-

cijoms ir kepenų transplantato funkcijai išlieka diskusijų objektu. Šio tyrimo tikslas buvo įvertinti, ar HCV infekcija turi įtakos ankstyvoms komplikacijoms ir transplantato funkcijai po kepenų transplantacijos mažame transplantacijos centre.

Medžiaga ir metodai. Retrospektyvinis tyrimas atliktas Vilniaus universiteto ligoninės Santariškių klinikose. Šiame mažame kepenų transplantacijų centre 2005 m. liepos – 2015 m. vasario mėn. 58 suaugusiems pacientams atlikta 60 ortotopinių kepenų transplantacijų. Išanalizuotos po transplantacijų įvykusios ankstyvos kraujagyslių ir tulžies komplikacijos bei ankstyvas kepenų transplantato funkcionavimas. Vertinant HCV infekcijos reikšmę visi kepenų recipientai buvo suskirstyti į dvi grupes (remiantis patvirtinta arba paneigta HCV infekcija). Statistinė duomenų analizė atlikta naudojant Microsoft Excel ir SPSS 20.0 programas. Grupių skirtumai ir patikimumai vertinti Student t testu.

Rezultatai. Tyrimo duomenimis, 21 pacientui (35 %) indikacijos kepenų transplantacijai buvo nulemtos lėtinės HCV infekcijos, 39 pacientams (65 %) – kitos (ne HCV) indikacijos. 29 pacientams (48 %) išsivystė ankstyvos tulžies ir / arba kraujagyslių komplikacijos po kepenų transplantacijos: kraujagyslių komplikacijos – 17 pacientų (28 %), tulžies komplikacijos – 12 pacientų (20 %). Ankstyva kepenų transplantato funkcija vertinta kaip gera ar patenkinama 52 pacientams (87 %), pradinė disfunkcija – 8 (13 %) pacientams.

Išvados. HCV infekcija neturėjo statistiškai patikimos įtakos nei ankstyvoms komplikacijoms (po kepenų transplantacijos) išsivystyti, nei pradinei transplantato disfunkcijai.

Raktažodžiai: hepatitas C, kepenų transplantacija, ankstyvos komplikacijos po kepenų transplantacijos, ankstyva kepenų transplantato funkcija